

ABDOMINORECTAL PULL-THROUGH RESECTION FOR CANCER AND FOR HIRSCHSPRUNG'S DISEASE

Delayed Posterior Colorectal Anastomosis

RUPERT B. TURNBULL, JR., M.D., and ALAN CUTHBERTSON, M.D.*

Department of General Surgery

THE complications following conventional pull-through procedures for cancer of the mid-rectum or Hirschsprung's disease are certainly not to be minimized. Ischemic necrosis of the pulled-through segment, and retraction and abscesses in the presacral space are the most difficult complications to treat. Waugh and Turner¹ in summarizing their extensive experience and excellent results state that 13.4 per cent of their patients had some degree of slough and retraction of the pulled-through colon, while in 20.9 per cent infection developed in the presacral space.

We believe that ischemic necrosis, retraction, and presacral infection are due to: (1) the too frequent reliance on the sigmoid colon as the pulled-through segment, (2) insufficient external fixation of the exteriorized colonic segment, and (3) immediate replacement of a colorectal anastomosis into a compartmented pelvic hematoma (as in Swenson's operation). The technic reported here ensures the removal of the sigmoid colon (which occasionally is of doubtful viability after mobilization), adequate and absolute fixation of the exteriorized colonic segment on the perineum, and a safe, delayed colorectal anastomosis after the incubation period of pelvic abscess is past, or the infection, if present, has been controlled.

The delayed anastomosis technic described here was evolved by us in 1952 for adults having small cancers located in the mid-rectum, and in whom a Swenson type² of pull-through resection was performed. In 1953, we utilized the same technic in children undergoing resections for Hirschsprung's disease. In September, 1960, in Sao Paulo, Brazil, one of us (R.B.T.) was pleased to note that Dr. Daher E. Cutait³ had independently utilized the delayed anastomosis in adults who had undergone pull-through resections for the acquired megacolon of Chagas' disease.

Technic of Pull-Through Resection of the Rectum and the Sigmoid Colon

Abdominal phase. The sigmoid colon is mobilized and the mesentery is stripped medially from the left ureter, iliac vessels, and aorta up to the third portion of the duodenum where the inferior mesenteric artery and vein, and left colic artery,

*Formerly Special Fellow in the Department of General Surgery; present address: Royal Melbourne Hospital, Melbourne, Australia.

are ligated and are divided. The rectum is freed from its pelvic attachments as in the Miles's⁴ operation except that the distal dissection is carried on through the levatores ani. Two stout braided silk ties are placed around the rectum two inches below the neoplasm; another is placed just above it. (The lumen of the bowel is thoroughly washed with a cancerocidal solution.) At this juncture, a pull-through operation requires that the entire left colon and splenic flexure mesentery be mobilized and be detached from the lower border of the pancreas above the ligament of Treitz. (The omentum is excised from the distal transverse colon.) The inferior mesenteric vein is again divided, this time at the ligament of Treitz. The mid-sigmoid colon will now stretch to the mid-thigh. The sigmoid-descending-colon junction is selected as the probable site for perineal resection of the left colon, and small arteries of the epiploic appendixes are cut in order to determine arterial flow. If pulsations are not seen, larger mesenteric vessels are divided near the colon until pulsation is obvious. (Note: Distally, the blood from cut sigmoid arteries flows but does not pulsate.) A heavy black braided silk tie is then placed as a marker. The bowel is not divided — thus protecting the presacral space from unnecessary contamination.

Perineal phase. In an exaggerated lithotomy position the anus is dilated; the lower ampulla (below the silk tie) is cleansed thoroughly and repeatedly with tincture of benzalkonium chloride.* If the anus is rigid and unyielding, the lower band of the internal sphincter is divided through a short radial incision in the anal skin of one of the posterior quadrants. The rectal mucosa above the dentate line is grasped with hemostats and is everted (*Fig. 1A*), and the rectum is completely severed through the mucosa about 1 cm. above the dentate line. The abdominal colorectal segment is gently pulled through the everted rectal stump until the black-silk marker at the sigmoid-descending-colon junction is in sight (*Fig. 1B*). The colon now lies directly over the aorta (*Fig. 1C*), the rectum and sigmoid portions having been withdrawn. The mesentery usually lies posteriorly at the anus. The protruding colon is severed about two inches from the anus; bleeding mesenteric vessels are ligated; and the short, everted rectal segment is sutured to the seromuscular layers of the protruding colon (*Fig. 2A*). The colonic segment is wrapped in folded gauze and is held in firm position by skin clips (*Fig. 2, B and C*) to prevent retraction. The end of the colon is clipped to the gauze wrapping.

Completion; abdominal phase. The left colon mesenteric defect is obliterated by suturing the mesentery to the preaortic tissues, to prevent herniation of small intestine. The accumulated blood in the pelvis is removed by suction, and several large soft-rubber tissue drains are placed in the depths for pelvic drainage of the blood and serum. (The drains may be left in as long as necessary, because they do not lie against an anastomosis.) The pelvic peritoneum is not reconstructed.

*Zephiran chloride, Winthrop Laboratories.

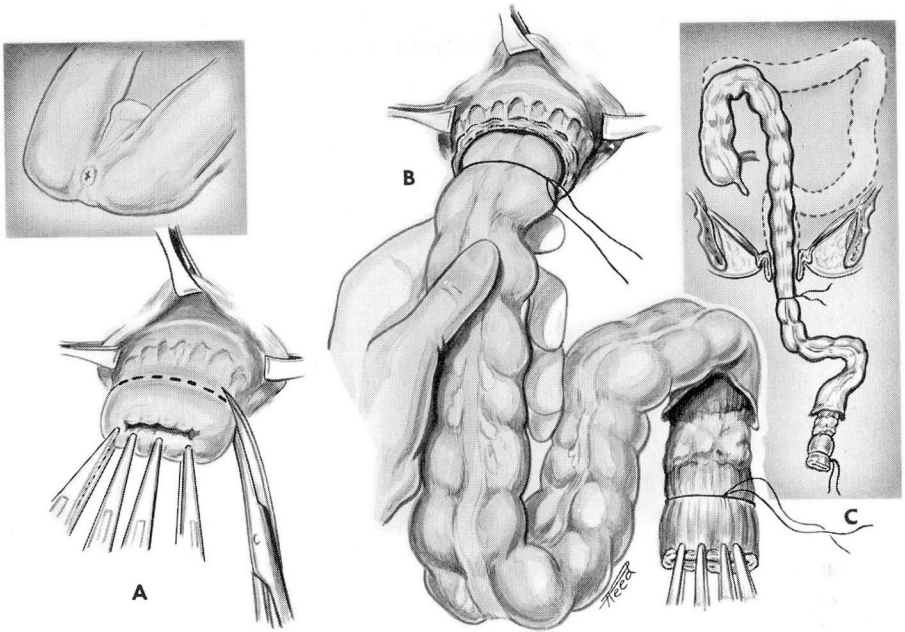


Fig. 1. Details of the perineal phase of a pull-through resection. A, Division of the slightly everted rectum. B, Pull-through of the rectum and sigmoid colon. C, Pull-through completed.

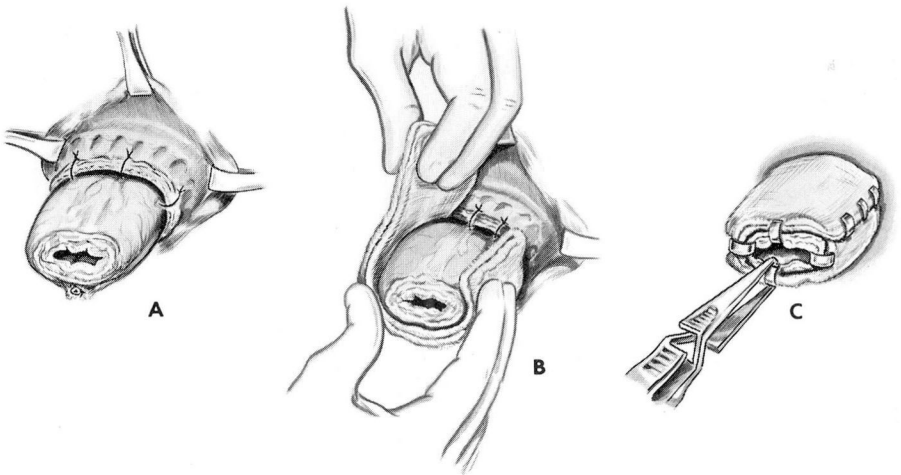


Fig. 2. Fixation of the colonic stump with a gauze stent and clips.

It is left open to allow free drainage of blood and serum into the abdominal cavity. The abdomen is closed.

Management of perineal colostomy. During the first ten postoperative days, the colon is lavaged daily by enema through the perineal colostomy. Ointments are used on the skin to prevent irritation. By the tenth or twelfth day, there is firm union between the colon and the everted rectal stump, and posterior resection with anastomosis can be performed (*Fig. 3*). If an abscess has developed in the presacral space, it can be drained alongside the protruding colon, and the space can be lavaged with a catheter. The posterior anastomosis can be delayed as long as necessary.

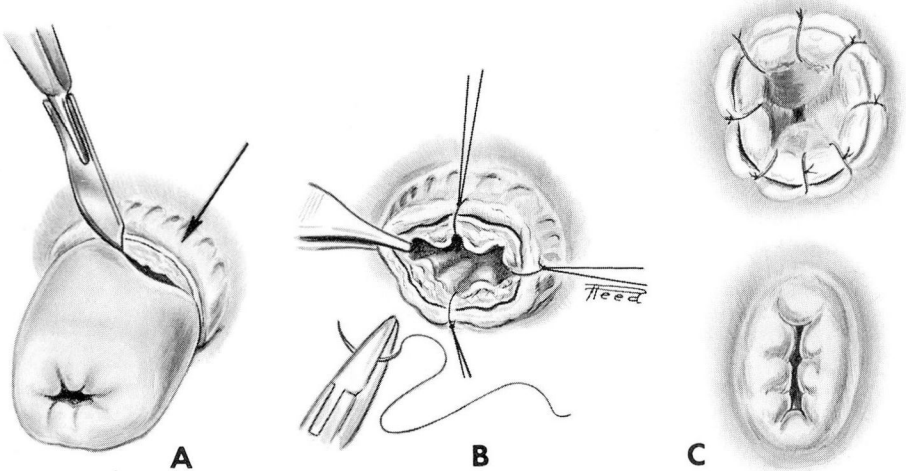


Fig. 3. Delayed (tenth day) perineal colorectal anastomosis. A, Resection of protruding colon. B, Full-thickness suture colorectal anastomosis. C, Completed anastomosis and retraction.

Figure 3 shows the details of the posterior anastomosis done on the tenth day. With the patient in left lateral position under caudal or local anesthesia the gauze collar is removed. The edematous colonic segment is cut off flush with the protecting everted rectal stump (*Fig. 3A*, arrow), and end-to-end anastomosis is made with 0000 chromic catgut through all layers. In adults, no more than 1 cm. of mucosal-covered rectum above the dentate line must be preserved, since a longer segment will not retract spontaneously after the anastomosis has been made. *Figure 3B* shows the placing of catgut sutures (by quadrants), the finished anastomosis, and the final spontaneous retraction that occurs within 24 hours. *Figure 4* shows the retracted anastomosis in position.

Bowel management. Although true continence is possible in some patients, the majority have many small movements and oozing of stool through the anus secondary to fecal accumulation. A one-quart daily enema will stop further move-

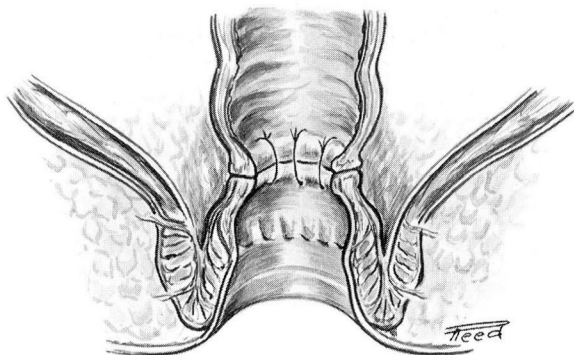


Fig. 4. Tenth-day anastomosis after retraction.

ments until the anastomotic area becomes soft and sensitive.

Management of presacral hematoma and abscess. Fever and leukocytosis during the 10-day period after operation may indicate infection of the presacral collection of blood. This can be drained by inserting a finger through the anus and into the space. Constant lavage through a catheter usually is effective. The final colorectal anastomosis can be delayed as long as necessary.

Results

Tables 1 and 2 list the complications that occurred in comparable groups of patients undergoing pull-through resections for cancer, Hirschsprung's megacolon, and other conditions from 1949 through 1960. The most serious complications occurred in the patients who had cancer. Although the comparisons

Table 1.—Immediate posterior anastomosis: major complications that occurred in 36 patients after pull-through resection (1949-1960)

Primary disease	Number of patients					
	Total	Major complication				
		Presacral abscess	Retraction	Slough	Leaking anastomosis	Postoperative death
Cancer	22	6	1	1*	2	2
Megacolon	12	1	0	0	0	0
Imperforate anus	2	0	0	0	0	0
Grand total	36	7	1	1	2	2

*Patient had had previous aortic resection for aneurysm.

Table 2.—Delayed posterior anastomosis: major complications that occurred in 37 patients after pull-through resection (1949-1960)

Primary disease	Number of patients					
	Major complication					
	Total	Presacral abscess	Retraction	Slough	Leaking anastomosis	Postoperative death
Cancer	23	3	0	0	0	0
Megacolon	7	1	0	0	0	0
Imperforate anus	3	0	0	0	0	0
Ulcerative colitis	1	1	0	0	0	0
Villous tumor	2	0	0	0	0	0
Radiation fistula	1	0	0	0	0	0
Grand total	37	5	0	0	0	0

between *Tables 1* and *2* may not be of statistical significance, there were no deaths from leaking anastomosis, no retraction of the pulled-through colon and fewer presacral abscesses in the delayed anastomosis group. Ischemic necrosis of the pulled-through colon (*Table 1*) occurred in a patient who previously had an aortic resection for an aneurysm. This low incidence is credited to the complete removal of the sigmoid colon with its unpredictable blood supply. The presacral abscesses were due to operative contamination of the collection of blood in the presacral space, and in each instance the rectum was either inadvertently opened during the pelvic dissection or was divided (technic of Swenson) before the pull-through procedure was accomplished; in two patients (*Table 1*) the anastomosis leaked after it had been completed and had been returned to the pelvis (immediate anastomosis).

Conclusion

A technic for delayed posterior colorectal anastomosis has been presented. The serious complications after this procedure have been fewer than those after primary colorectal or coloanal anastomoses. Anastomotic leaks are not possible. Should a presacral abscess develop, drainage can be effected through the anus, and colorectal anastomosis may be delayed as long as necessary. The technic is particularly adapted to pull-through resections in adults in whom a primary anastomosis of the Swenson type is difficult or impossible to perform because of rigid sphincters and perineal tissues.

References

1. Waugh, J. M., and Turner, J. C.: Diseases of the Colon and Anorectum, vol. 1, edited by R. Turrell. Philadelphia: W. B. Saunders Co., 1959, 608 p.; p. 515-526.
2. Swenson, O., and Bill, A. H., Jr.: Resection of rectum and rectosigmoid with preservation of sphincter for benign spastic lesions producing megacolon; experimental study. *Surgery* 24: 212-220, 1948.
3. Cutait, D. E.: Personal communication, Sept. 1960.
4. Miles, W. E.: Method of performing abdominoperineal excision for carcinoma of rectum and terminal portion of pelvic colon. *Lancet* 2: 1812-1813, 1908.