

RIGHT COLON USED AS AN ESOPHAGEAL PROSTHESIS

Report of Five Cases

LAURENCE K. GROVES, M.D.,

Department of Thoracic Surgery

and

RUPERT B. TURNBULL, JR., M.D.

Department of General Surgery

A large part of esophageal surgery is concerned with restoration of a relatively normal function of swallowing by substituting other organs for the esophagus. Historical review of this surgery offers a fascinating chapter on technical ingenuity and daring,¹⁻³ but it is beyond the scope of this paper. In general, the evolution of surgical technics has led to the use of the mobilized stomach as the esophageal substitute of choice.

In the surgical treatment of carcinoma of the esophagus the primary mission is to perform the best cancer operation possible, and, secondarily to re-establish gastrointestinal continuity quickly and safely. To accomplish the second goal, there is no substitute for the stomach. A complete cancer operation in the thoracic esophagus involves the mobilization and resection of the principal areas of lymphatic drainage, most important of which is the chain of nodes reaching down along the left gastric vessels to the superior border of the pancreas. When this has been accomplished, mobilization of the stomach is approximately one half achieved and it is easy to complete the procedure.

Most patients adjust satisfactorily to the thoracic stomach created for the above-described purpose, particularly if a pyloroplasty is performed. However, there are other conditions, usually occurring in young patients, frequently involving most of or upper portions of the esophagus, and all of a benign cause, in which other approaches to the problem offer at least theoretic advantages. Hopefully, these lesions are associated with a normal life span, and the reservoir and digestive functions of the stomach presumably operate best in a normal anatomic situation. Also, there are certain well-known peptic difficulties associated with a thoracic position of the stomach and esophagogastric anastomoses, although their magnitude (particularly if a pyloroplasty has been performed), is probably overemphasized.

Efforts to use intestinal segments as esophageal substitutes in various planes, from under the skin on the anterior chest wall to the normal esophageal bed, have been employed for many years.^{2,3} It has evolved that the right colon nourished by the middle colic vessels is optimal for esophageal substitution. Firstly, its vascular pattern is relatively constant, and secondly, the distance from the origin of the middle colic vessels to the tip of the cecum is roughly comparable to

the distance from the origin of the middle colic vessels to the suprasternal notch, so that when the right half of the colon is mobilized and rotated 180 degrees, the cecum will reach into the neck. At the other end there is no problem in approximating the transverse colon to the stomach. Another advantage in using a segment of colon in this manner for the replacement of benign esophageal disease is that the diseased esophagus may be abandoned in situ, and the colon may be passed up through an anterior mediastinal tunnel into a neck incision with no necessity for performing a thoracotomy.

We make no claims for originality in developing these technics,^{4,5} and our experience to date, which is cited below, is extremely limited; however, the results have been so gratifying, both to us and to the patients, that it is thought worthwhile to present them here.

Technic

Preparation of the patient for surgery includes two steps. The first of these is the obtaining of a satisfactory nutritional status. Long-standing dysphagia is often associated with obvious malnutrition. The solution to this problem may be the preliminary placement of a catheter gastrostomy that facilitates a forced feeding program. We consider a gastrostomy a mandatory part of this operative procedure, and there is no particular disadvantage to performing it as a preliminary stage if necessary. The other step in preparation concerns the colon. It must be as clean as possible before being utilized as a transplant. A low-residue diet for two or three days, followed by a cleansing dose of castor oil and a 24-hour program of neomycin sulfate administered orally are utilized. The day before operation, enemas are given until the returns are clear.

The abdomen is opened through a short right paramedian incision. The ileum is divided two inches from the ileocecal valve, and the distal section is excised from its mesentery to the cecum. The ileocolic artery and its branches to the cecum are thus preserved (*Fig. 1*). The remaining stump of ileum is closed and is invaginated into the cecum. The proximal ileum is seen to be nourished by the terminal branches of the superior mesenteric artery (*Fig. 2*). The right colon is then completely mobilized from its bed and from its peritoneal attachments until it has been reflected medially from the second and third portions of the duodenum and from the head of the pancreas. The ileocolic artery and vein are divided as close to the superior mesenteric artery as possible (*Fig. 1*). The proximal transverse colon is separated from the gastrocolic ligament and from the omentum. The right colic artery and vein (if present) are divided at their origin from the superior mesenteric vessels. The transverse colon is then divided between the primary divisions of the middle colic artery, if this vessel divides in the substance of the pancreas; or to the left of the middle colic artery, if the division point is near the mesenteric border of the transverse colon. The mobilized right colon must

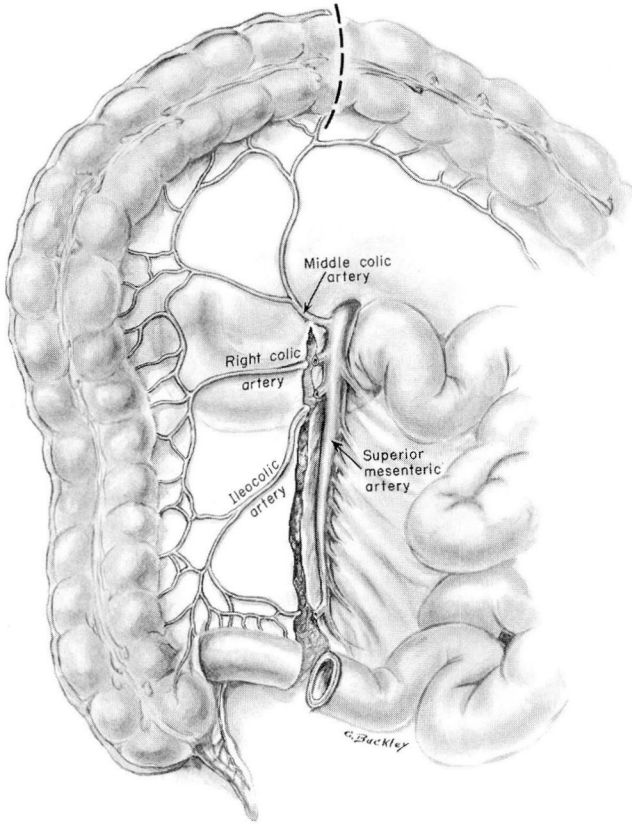


Fig. 1. Structures severed in mobilization of the right colon for esophageal substitution. The ileocolic and right colic arteries are divided at their respective origins.

swing freely on the pedicle of the middle colic artery, and must be completely separated from the head of the pancreas, the stomach, and the right renal area. A heavy silk ligature is tied around the appendix, and the ligature is utilized for traction while the cecum is pulled up posterior to the antrum of the stomach. The entire right colon is then pulled up until it lies above the lesser curvature of the stomach (Fig. 3).

We believe it is important to pass the colon and its vascular pedicle posterior to the antrum of the stomach (rather than anterior to the antrum), for this maneuver gives significant additional length and also avoids the theoretic hazard that might be associated with gastric dilatation, stretching, and obstructing the middle colic vessels (Fig. 4). Intestinal continuity is next re-established by an appropriate anastomosis between the ileum and the distal transverse colon.

At this point the anterior mediastinal tunnel should be prepared for the colon,

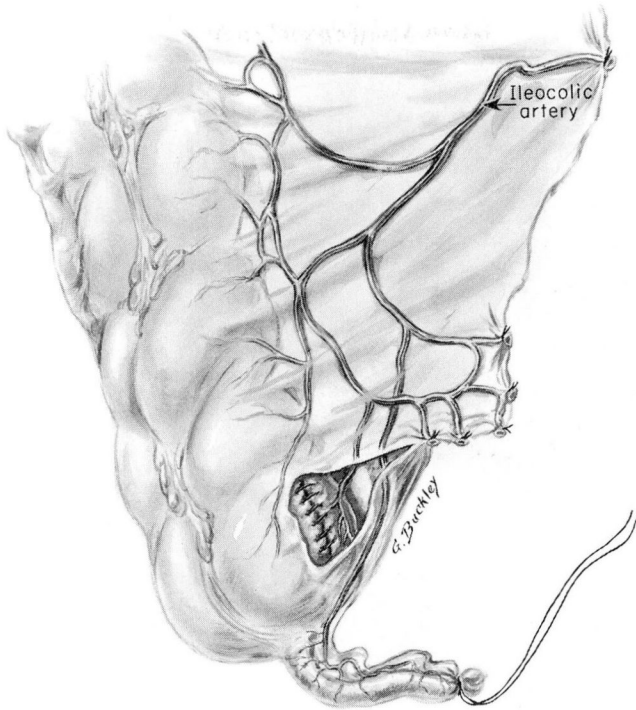


Fig. 2. Details of the ileocolic arterial supply after closure of the stump of the ileum, and invagination into the cecum. Note the preservation of the terminal branches to the cecum.

and the cervical esophagus should be mobilized for anastomosis to the cecum in the neck. The inferior portion of the tunnel is opened by breaking through into the anterior mediastinum with finger or blunt scissor dissection posterior to the xiphoid. The diaphragmatic attachments are not firm in this area and the maneuver is safe if care is taken to keep the dissection immediately on the posterior aspect of the sternum. By spreading the scissors, or by inserting two fingers and spreading them laterally, the size of the opening can be made as wide as necessary. Thus, access is gained to the anterior mediastinal plane between the sternum and the pericardium. It contains areolar tissue and is easily opened. The right pleural sac extends a varying distance over the pericardium into the mid-mediastinal region. Ordinarily it is not entered, but inadvertently an opening may be made. This is not harmful, but the possibility of a postoperative pneumothorax should be considered.

The optimal cervical exposure is obtained through an anterior sternocleidomastoid incision that commences at the sternal notch and extends approximately two thirds of the way to the mastoid process. Customarily we make this incision

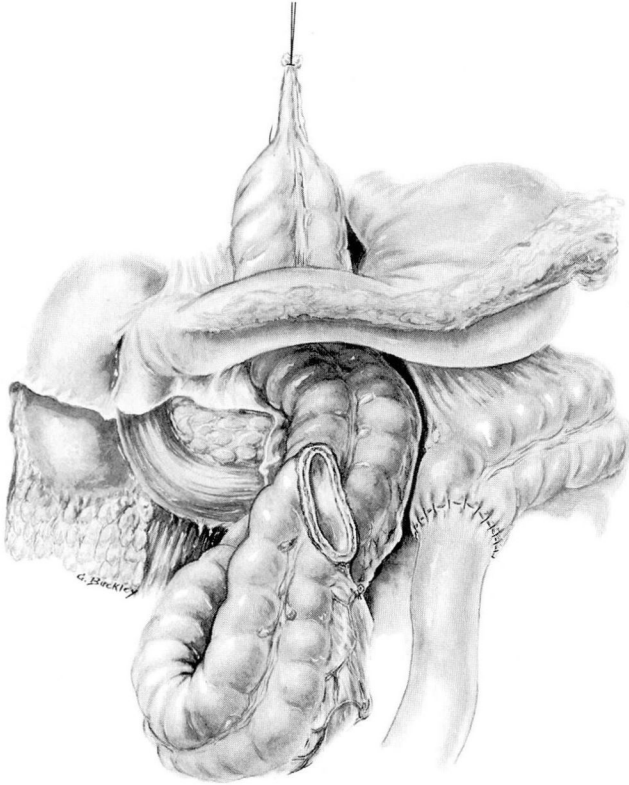


Fig. 3. Position of the right colon after it has been pulled up into the mediastinum posterior to the gastric antrum.

on the left side. As at the lower end, the areolar space posterior to the sternum is readily entered with finger dissection. Once again, care should be taken to stay immediately posterior to the sternum, thereby avoiding the innominate veins. There may be some rather tough fascial bands restricting the lateral extent of this opening; these may be cut with impunity. In a child, a finger from above and below may readily be approximated posterior to the sternum; in an adult the distance may be too great, and a long instrument may have to be passed through the mediastinal tunnel and then be withdrawn in an opened position to obtain the necessary tunnel diameter.

In dissecting down to the cervical esophagus medial to the carotid sheath, the only structures that ever need to be sacrificed are the omohyoid muscle and the inferior thyroid vessels. The cervical esophagus is identified below the larynx and is mobilized throughout its circumference. Care should be taken to avoid the recurrent laryngeal nerves. An umbilical tape is placed about the cervical esoph-

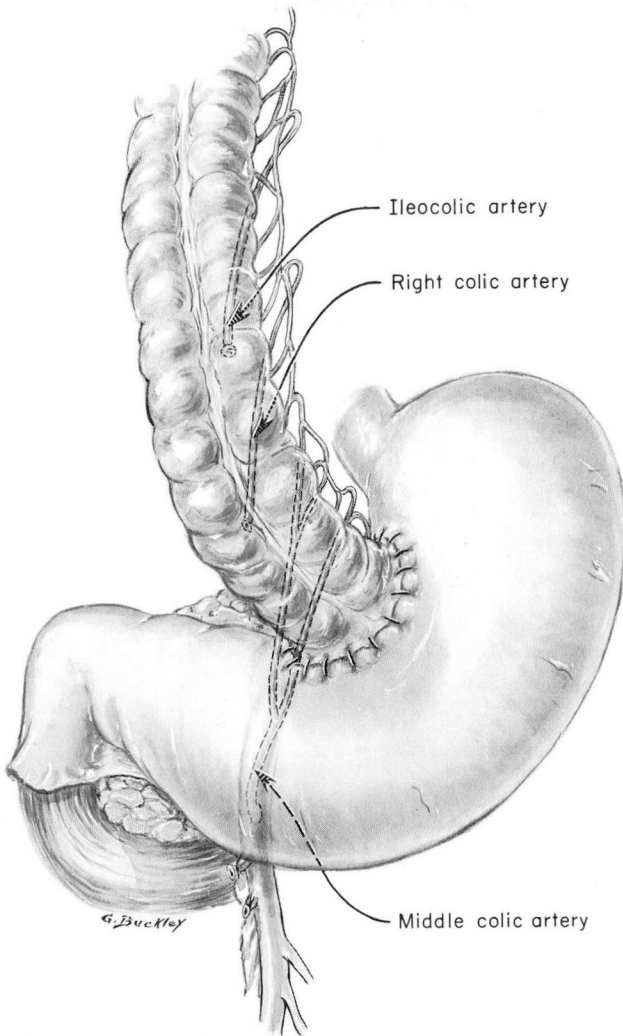


Fig. 4. The functioning position of the transplanted right colon. The middle colic artery pedicle lies posterior to the stomach.

agus and dissection is carried down around the esophagus as far into the mediastinum as is conveniently feasible. At the lowest point of dissection the esophagus is firmly tied with a heavy silk ligature. It is then divided immediately proximal to this ligature. Customarily we have then reinforced the distal closure with a continuous atraumatic catgut purse string suture. The esophageal stump is dropped into the mediastinum. It has caused no difficulties. The suture attached to the appendix is then passed up through the tunnel and, with gentle traction from above

and pressure from below, the cecum is teased up through the tunnel until it appears at the suprasternal notch. Before this maneuver we have found it valuable in several of the children carefully to enucleate a sizable mass of mesenteric lymph nodes in the immediate proximity of the cecum. Great care should be taken so as not to jeopardize any of the blood supply. We have found that the bulk of these nodes may be great enough to impede the passage of the cecum through the anterior mediastinum. It may require a surprising amount of maneuvering and gentle traction to tease the cecum up into the neck. In the course of this process, the tension on the middle colic vessels in the abdomen should be carefully assessed. When the appendiceal stump becomes apparent in the neck, a routine appendectomy is performed. The appendiceal stump is not located near to the apex of the cecum, and we have selected an appropriate cecal pouch for anastomosis. The most direct approximation of the esophageal stump and the cecum may be facilitated by dividing some of the underlying strap muscles (*Fig. 5*). There are no vital intervening structures. We have performed an open one-

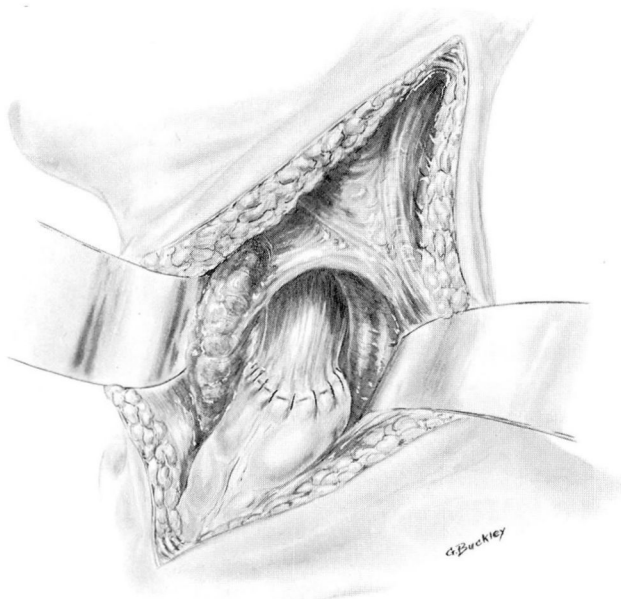


Fig. 5. Anatomic relationship of the esophageal anastomosis in the neck. The thyroid gland lies medial and the carotid sheath lateral to the anastomosis.

layer anastomosis using fine interrupted sutures with knots in the inside. It is important to place a small Penrose drain in the closure of this cervical incision in order that any possible leakage may be directed to the outside rather than toward the mediastinum.

Next, the abdominal portion of the operation is completed. The distal end of the colonic segment is tailored in length to be appropriately anastomosed, by an end-to-side interrupted technic, to the anterior wall of the stomach. There are then two additional important steps. The first of these is to create a catheter gastrostomy, bringing the catheter out through a stab wound to the left of the abdominal incision. This gastrostomy is vital for decompressive purposes, as it is not feasible to attempt to thread a Levin tube through the tortuous haustrations of the new colonic esophagus. After the need for decompression has passed, the tube may be used for feeding. We withhold oral feeding for the first postoperative week. The other operative step, which probably is important, is the construction of a pyloroplasty (*Fig. 6*). The colon — more than the esophagus —

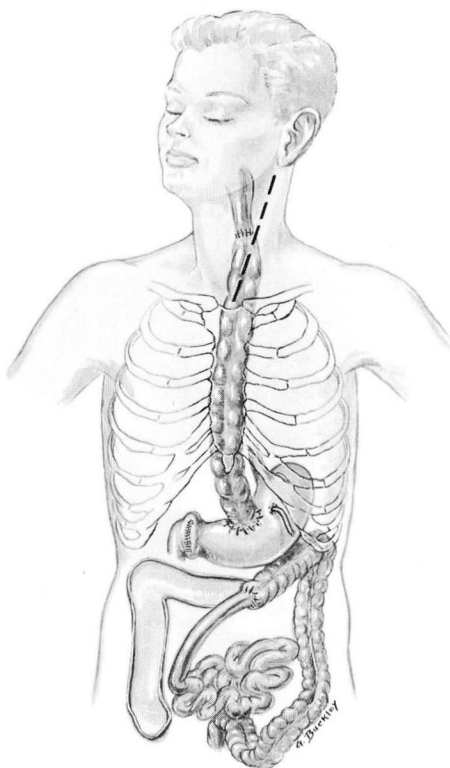


Fig. 6. Sketch of the completed operation. Pyloroplasty has been performed. The catheter gastrostomy is preserved. The ileocolic anastomosis has been completed.

seems to be resistant to peptic activity; nevertheless, we have routinely performed a pyloroplasty to minimize reflux.

Our total experience with this operation is next reported.

Case Reports

Case 1. A 26-month-old Negro girl was first examined by us in March, 1958. Ten months before examination she accidentally swallowed lye. An emergency tracheotomy was performed and a vigorous course of dilatations of the esophagus was instituted. However, dysphagia became progressively worse, and four months after the accident it was necessary to perform a feeding gastrostomy, after which time the dilatations were continued in retrograde fashion utilizing an indwelling string. The string was lost and a total esophageal atresia developed.

The physical examination here disclosed no remarkable findings. A tracheotomy and a gastrostomy were in place, and the child was obviously well nourished. As an initial procedure, two 5-mm. bronchoscopes were simultaneously passed down into the esophagus (through the mouth), and up into the terminal esophagus (through the gastrostomy). Using fine bougies it was impossible to find any channel whatsoever for a distance of about 4 cm. between the tips of the two bronchoscopes; in this fashion it was proved that there was total discontinuity of the esophageal lumen in the upper thoracic region.

The operative procedure with the technic just described was performed. The gastrostomy already in place was not disturbed, and the colon was implanted in the stomach distal to that point. The cervical portion of the procedure was not unduly complicated by the tracheotomy stoma, which was draped out of the field of the left anterior sternocleidomastoid incision.

The postoperative convalescence was uneventful. On the fourth postoperative day, it was apparent that she had learned to swallow saliva; previously she continually had to expectorate it. On the eighth postoperative day, she consumed applesauce with obvious pleasure. It was apparent, however, that swallowed matter caused distention of the cecal pouch that lay in the neck, indicative of hourglass narrowing of the colonic esophagus where it passed through the thoracic inlet; therefore, solid food was withheld for several days. Prior to discharge from the hospital she was eating a normal diet, with relish. There have been no difficulties, and the parents consider her a normal child, three years after the operation.

Comment. During her postoperative course in the hospital, the patient's swallowing resulted in distention of the cecal pouch, as mentioned, in a manner analogous to that of a chipmunk hoarding food in its cheek. This distention had completely disappeared two months postoperatively (*Fig. 7*).

A surgical procedure of this type offered the only alternative to a permanent gastrostomy in this child. Total esophageal obstruction is extremely distressing to a patient because of the inability to cope with saliva by any means other than continuous drooling or expectoration. The small infant or the infirm patient may aspirate the saliva, and dire pulmonary consequences may ensue. It is gratifying to be able to cure a protracted and complicated disability of this type in a one-stage definitive operative procedure.

Case 2. A two-day-old infant girl was first examined in February, 1958, when she was referred to us because of a tracheoesophageal fistula. The diagnosis had been suspected when it was noted that the child regurgitated excessive amounts of mucus, and

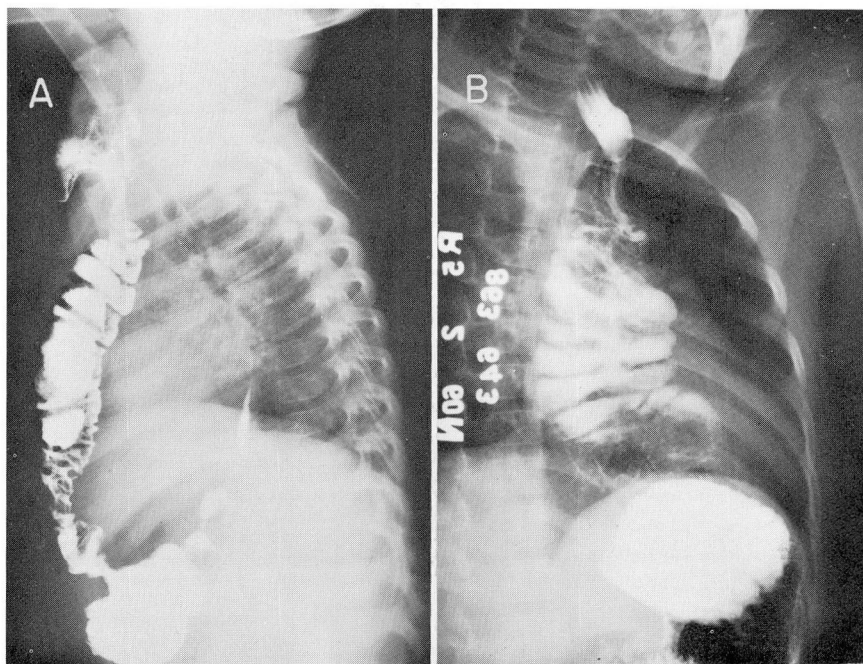


Fig. 7. Postoperative barium studies showing the function of the colonic esophagus. A, Demonstrates the immediate substernal location of the colon. Note the reflux of barium into the abandoned esophagus. This is a study on Case 1, a child with caustic stricture. The bottommost portion of the stricture is demonstrated by the barium reflux in the esophagus. B, Shows the extent to which the colon may dilate when exposed to negative intrathoracic pressure. This poses no clinical problem. Both of these views suggest that the sluggish colonic peristalsis plays only a small role in the swallowing function of these patients. Cineradiographic studies demonstrate that the barium cascades down through the colon by gravity.

it was confirmed by instillation of a small amount of Lipiodol* into the blind upper esophageal pouch. The terminal esophagus was proved to communicate with the tracheobronchial tree by the presence of air in the gastrointestinal tract.

The child was operated upon the next day. The blind proximal end was found to be extremely short, ending rather high up in the neck. The terminal esophagus arose from the inferior aspect of the carina. This fistula was taken down and closed; however, it was found that the two esophageal ends could not be approximated. The distal end was therefore tied, and the chest was closed. A feeding gastrostomy was constructed, and the cervical esophagus was exteriorized in the neck as a mucous fistula. It was decided to postpone reconstruction for two years. The child progressed well and was readmitted as planned in May, 1960, and, after considerable nutritional preparation, colonic substitution was performed according to the technic described.

The early postoperative convalescence was uneventful. On the seventh postoperative

*E. Fougera & Co.

day, the child took the first oral feeding of her life, and drank liquids well. An indurated area developed in the cervical incision which discharged a small amount of purulent material and some gas bubbles indicative of a small fistula; however, it healed rapidly and has not been a problem. Six months after the operation a report from the parents indicates that the child has had no difficulty, and she eats a normal diet for her age. Her appetite is excellent.

Comment. This is the youngest and smallest (weight, 20 pounds) patient upon whom we have performed this operative procedure. The small size of the structures did not pose any unanticipated operative difficulties. The described operative procedure offers the ideal solution to problems of congenital esophageal atresia when a primary anastomosis cannot be performed. We do not know how early in life the operation can safely be performed, but it seemed reasonable to us to defer it for two years to allow the child to grow. We are not aware of experience of other surgeons with younger infants. At the initial operative procedure in the newborn it is vital to exteriorize the upper esophageal stump so that the infant can swallow rather than aspirate the saliva. The fistula must also be divided so that gastric contents cannot regurgitate into the tracheobronchial tree.

Case 3. A five and one-half year old boy was first examined here in July, 1959, because since the age of two years he had had episodes of hematemesis which required numerous blood transfusions. In addition there was a problem of mild dysphagia with episodes of regurgitation of recently ingested food. In spite of iron therapy, his blood hemoglobin content was said to be frequently as low as 8 gm. per 100 ml.

Roentgenograms of the esophagus and stomach were not remarkable except for evidence of an ill-defined area of moderate narrowing immediately below the level of the aortic arch (*Fig. 8*). Esophagoscopy demonstrated a definite stricture at this level, and the mucosa changed to readily bleeding granulation and scar tissue. The esophagoscope could not be passed beyond the stricture that was thought possibly to be an inflammatory response to a long-retained foreign body. Mucosal biopsy specimens showed only fibrinous suppurative exudate. A week later the procedure was repeated, but no additional information was obtained; once again an acute inflammatory process was encountered and free bleeding resulted from dilatation and attempts at biopsy. The precise nature of the lesion was extremely puzzling, and a thoracotomy was believed to be indicated.

A right exploratory thoracotomy was performed. The vascularity of the posterior mediastinum was much greater than normal about the esophagus. There were also present a number of succulent, inflammatory lymph nodes. The esophagus was notably enlarged and thickened; however, palpating up and down the esophagus revealed no obvious localized lesion. The esophagus was opened longitudinally at the anticipated level of pathologic change. The muscular wall was noted to be hypertrophied and fibrotic. An area of fusiform narrowing was seen. There was definitely no retained foreign body, or mediastinitis. Several rents in the mucosa in this region were thought to be related to the previous instrumentation. Numerous mucosal biopsy specimens were removed. The reason for the bleeding was not apparent, and it was believed that, in view of the puzzling nature of the problem, a radical resection was contraindicated. The esophagus was reconstructed. The mucosal biopsy specimens showed chronic inflammation, necrosis, and suppuration, but no residual mucosa. The problem was basically

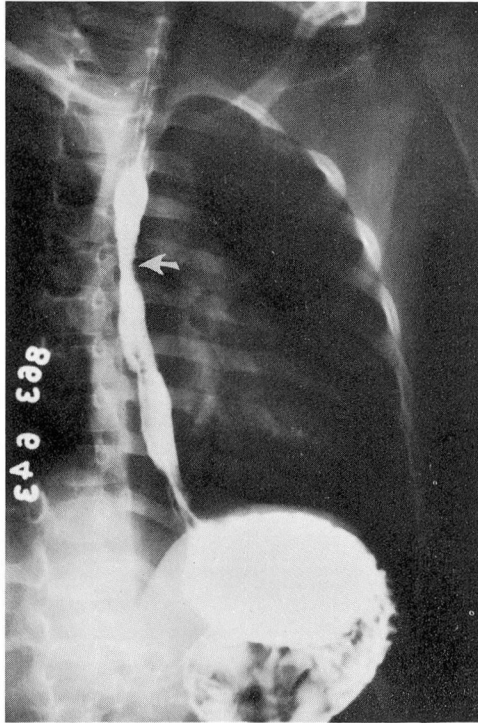


Fig. 8. Case 3. Preoperative barium study. The arrow indicates the area of stricture. In this area, a biopsy specimen of suppurative inflammation was obtained through the esophagoscope and free bleeding was seen. The mucosa below this area was proved to be gastric mucosa.

unchanged by this operative procedure although the tendency to bleed and to become anemic seemed to be somewhat less than preoperatively.

In February, 1960, the patient was again examined with a small esophagoscope. It was possible for the first time to pass the instrument beyond the area of narrowing into the lower esophagus. Biopsy specimens were removed at approximately the junction of the middle and the lower third of the esophagus, and these specimens consisted of gastric mucosa. The visual and radiologic anatomy at these levels was definitely esophageal, ruling out hiatus hernia and establishing the diagnosis of ectopic gastric mucosa.

In view of the almost life-long history of bleeding and stricture, it was decided that the most logical treatment was the operation under discussion. Postoperative convalescence was completely uneventful, and the boy was eating a normal diet at the time of discharge from the hospital. One year after operation there is slight difficulty only in swallowing lettuce and leafy vegetables. We wondered whether the functionless bypassed esophagus might still bleed. This has not been a problem to date and his blood hemoglobin content is now in the normal range.

Comment. The presence of ectopic gastric mucosa in the esophagus is extremely rare. Presumably the mucosa secretes in response to the same stimuli that cause normal gastric secretions, and results in peptic ulceration in the squamous mucosa above. This was the cause of the stricture and repeated bleeding in this patient. As an alternative procedure in this case, vagotomy and a gastric drainage operation were suggested. One wonders if the ectopic mucosa would not still secrete acid peptic juice when the level of division of the vagus nerves is further down the esophagus than the level of the ectopic mucosa, as would be the case with the conventional vagotomy. It was thought that in view of the severe fibrosis already present in the esophagus of the child at six years of age, although the stricture was not extremely severe, the most definitive action in regard to the many years ahead was to abandon his defective esophagus and construct a new one. Presumably the bypassed esophagus is still subject to its normal secretory stimuli; however, as stated, to date we have seen no evidence of further bleeding. We have seen this type of lesion in only one other patient, a middle-aged man. His problem was one of stricture without bleeding. He underwent vagotomy (trans-abdominal) and pyloroplasty; results were indifferent.

Case 4. A 43-year-old woman was first examined by us in March, 1960. Six months before examination, because of atypical cervical cytologic findings she underwent a hysterectomy. Malignancy was not confirmed on histologic examination. Two days postoperatively, some coffee-ground vomitus was noted, and gastric suction via a Levin tube was maintained for two days. Roentgenograms at that time are said to have shown an active duodenal ulcer. She was discharged from the hospital approximately 10 days after the operation; however, progressive dysphagia became a problem and she was rehospitalized one month postoperatively because of essentially complete esophageal obstruction. Roentgenograms at that time showed evidence of narrowing of the esophagus from approximately the level of the aortic arch on down. An esophagoscopy examination is said to have shown fiery-red mucosa at the upper end of this area. The mucosa bled readily.

A gastrostomy was performed for feeding purposes, and retrograde dilatations were commenced. In addition, she was maintained on steroid therapy for its antiinflammatory action. In spite of this program and in spite of the ability to dilate the esophagus repeatedly up to size no. 32 French the process did not abate. In view of the intractability of her bizarre esophagitis, she was referred to us for consideration of fabrication of a substitute esophagus.

Preparations were made for colonic replacement, which was performed in the manner described. Once again, the original gastrostomy was not disturbed. It should be mentioned that at the time of performing the pyloroplasty, no significant duodenal pathologic change was noted. On the sixth postoperative day the patient was first given a liquid oral feeding. At this time some induration of the cervical incision was noted. On the eighth postoperative day a definite fistula developed, from the anastomosis through the wound. Within six days the fistula closed spontaneously, and at the time of discharge from the hospital, the patient was eating a normal diet without any difficulty for the first time since she had undergone the hysterectomy.

The patient reported that six months after the operation she could swallow any food she desired, but was apt to have some indigestion from other than simple bland

foods. She noted that she sustained a feeling of fullness rather rapidly; presumably this is because of slow peristalsis in the colonic esophagus. However, she has been most happy not to be bothered with the gastrostomy tube and associated inconveniences, and stated that she would highly recommend the operation to anyone in her former predicament.

Comment. We do not understand the cause of this pernicious type of postoperative esophagitis; fortunately it is exceedingly rare. It is difficult to incriminate the Levin tube, as it was used for only 48 hours. Whatever the reason, it seemed to us that this patient had had a sufficiently long trial (six months) of vigorous treatment to combat the tendency to stricture, without significant success, and that definitive surgical correction was indicated.

Case 5. A Negro woman aged 33 years was examined in June, 1960, because of four days of total dysphagia that occurred acutely while she was eating chicken. She weighed 82 pounds, and gave a history of inability to swallow normally since childhood. Although she had no knowledge of possible ingestion of a caustic, it is presumed that this was the origin of the obstruction. Over the years, this patient had had multiple

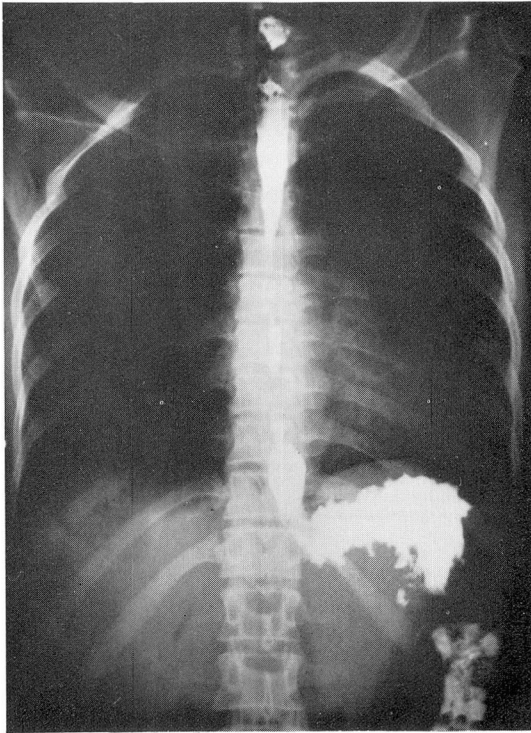


Fig. 9. Case 5. Preoperative barium study. The patient had long-standing multiple strictures presumably from caustic origin. Note that the topmost stricture is at the level of the first thoracic vertebra, and that there are several additional strictures lower down.

dilatations and had subsisted on a semiliquid diet. On one occasion, total dysphagia was precipitated by a watermelon seed.

She was examined with the esophagoscope, and the highest stricture was encountered at the level of the thoracic inlet (*Fig. 9*). Bougies passed beyond this point encountered multiple narrowed areas. At the same time through a small laparotomy incision a catheter feeding gastrostomy was constructed. The patient eagerly accepted the idea of a colonic esophagus and the operative procedure described was performed. Recovery was uneventful, and six months postoperatively she reported that she gained 15 pounds and swallows normally. She stated that she is satisfied with the results of the operation and is glad that it was performed. She described some unusual sensations, such as a feeling that food seems to descend in a round-about way, and she frequently notes gurgling in the chest associated with swallowing.

Comment. This patient had lived with severe esophageal strictures for many years, and her condition was quite stable with dilatations being performed at only rather long intervals. The maximum-sized dilator that could be passed was a no. 26 French. It is pertinent that when an alternative to the prospects of a permanently restricted oral intake was offered, the patient eagerly accepted surgery.

Conclusion

The previous case reports require no further amplification. If one restricts the use of this operative procedure (substituting a segment of the right colon for the obstructed esophagus) to patients with nonmalignant esophageal problems, this becomes an operation of only sporadic usefulness. Caustic esophageal strictures today seem to be extremely rare, attesting to at least some effectiveness of parental education programs as well as the almost universal use of store-bought soap. However, in the occasional suitable patient, the described approach offers a dramatic one-stage cure in the person whose life will otherwise be burdened with a permanent gastrostomy or an interminable series of dilatations. To date, after performing five such operations, we are fortunate in having only satisfied patients.

References

1. Gross, R. E.: *The Surgery of Infancy and Childhood: Its Principles and Techniques*, chap. 6 and 7, p. 75-125. Philadelphia: W. B. Saunders Co., Ltd., 1953, 1000 p.
2. Longmire, W. R., Jr., and Ravitch, M. M.: New method for constructing artificial esophagus. *Tr. South. S. A.* (1945) 57: 346-362, 1946.
3. Robertson, R., and Sarjeant, T. R.: Reconstruction of esophagus. *J. Thoracic Surg.* 20: 689-701, 1950.
4. Mahoney, E. B., and Sherman, C. D., Jr.: Total esophagoplasty using intrathoracic right colon. *Surgery* 35: 937-946, 1954.
5. Neville, W. E., and Clowes, G. H. A., Jr.: Reconstruction of esophagus with segments of colon. *J. Thoracic Surg.* 35: 2-22, 1958.