

EXPERIMENTAL PRODUCTION OF RENAL AND VASCULAR LESIONS WITH METARAMINOL

GEORGES M. C. MASSON, Ph.D., and SEIICHI KAWAKITA, M.D.*

Division of Research

IN the course of experiments in which hypertension was produced by subcutaneous injections of metaraminol, a drug with sustained pressor and vasoconstrictor effects,¹ we noticed lesions of renal necrosis. These pathologic changes were investigated, and they are the subject of this paper in which we also discuss their inhibition by hydralazine.

Experimental Study

1. *Effects of metaraminol in normal (control) rats.* In acute experiments, Sprague-Dawley rats that weighed from 250 to 300 gm. were each attached on a board while under sodium amytal anesthesia (dosage: 9 mg. per 100 gm. of body weight). Metaraminol was injected subcutaneously in a single dose of 1 or 2 mg. and the kidneys were examined through an incision in the abdominal wall. After ten minutes, the fur became ruffled and wet, the eyes protruded, and frothy fluid appeared around the mouth and nose. The kidneys were mottled by alternate areas of congestion and ischemia (*Fig. 1*).

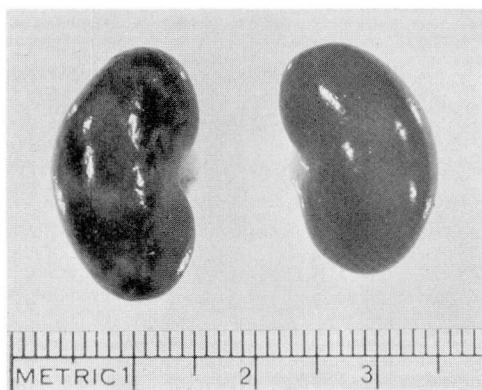

Fig. 1. On the left, kidney from a rat that received 2 mg. of metaraminol, showing zones of ischemia and congestion. On the right, kidney from a rat that received 2 mg. of metaraminol plus 0.5 mg. of hydralazine, showing absence of lesions.

In chronic experiments, metaraminol was given subcutaneously in three daily injections of 0.5 mg. each. The injected rats as well as some untreated control animals were placed in metabolism cages. The same but less severe symptoms as described above occurred after each injection and lasted for about one-half

*Fellow in the Division of Research.

hour. Body weight decreased sharply during the first 24 hours, averaging 195 gm. as compared with an initial value of 222 gm. Then body weight remained stable in some animals, while in others it recovered some of its loss. At the end of the experiment, body weight averaged 218 gm. in experimental and 233 gm. in control rats.

Urinary flow increased after injection of metaraminol, averaging 32 ml. as compared to 12 ml. per 24 hours in the control animals. On the seventh day, the animals were killed by bleeding. On gross examination, the kidneys of 5 of 10 rats showed abnormalities ranging from patchy to complete yellowish discoloration. Degree of severity was related to the amount of weight loss. Histologic changes in the kidneys ranged from tubular dilatation and atrophy to almost complete necrosis of the renal parenchyma. Necrosis involved primarily the medullary cortical junction from which it extended on both sides; in the most severe cases, only a narrow border of the outside cortex remained unaffected (*Fig. 2*), probably because of collateral circulation from the renal capsule. Isolated vascular lesions

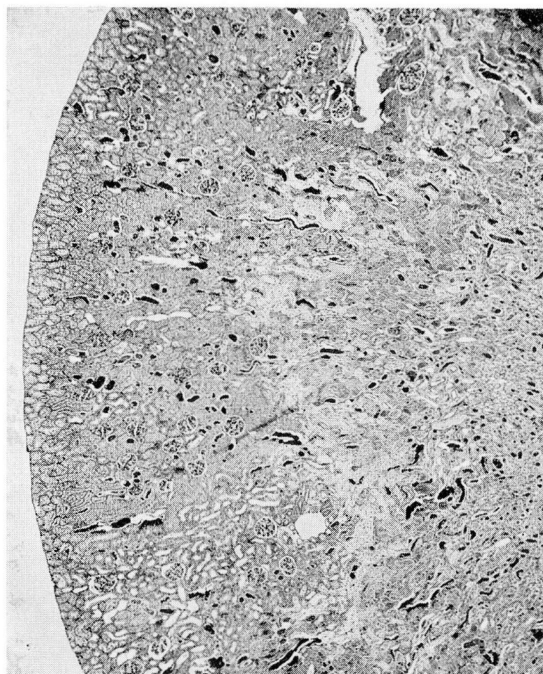


Fig. 2. Kidney from a rat treated with daily dose of 1.5 mg. of metaraminol during seven days, showing wedge-shaped necrosis that extends toward the upper cortex. On the left, note an area of normal cortical tissue except for some tubular dilatation. Periodic acid-Schiff stain; magnification X 30.

were present in arteries, including the renal artery (*Fig. 3*) but not in arterioles; their severity was not necessarily related to the degree of necrosis of renal paren-

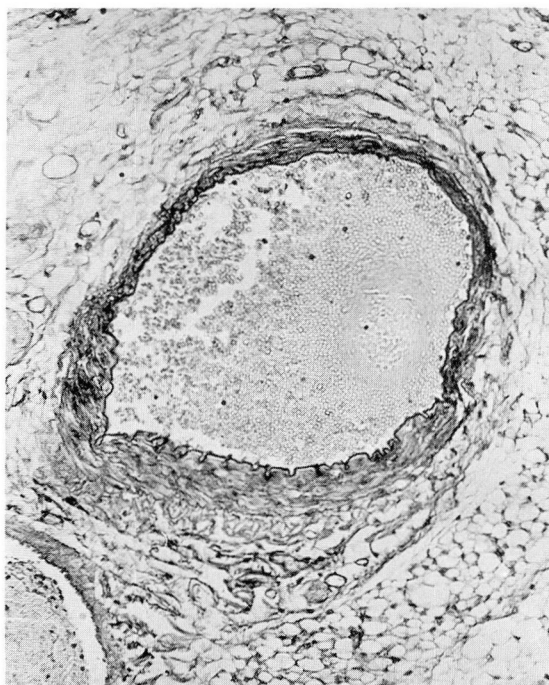


Fig. 3. Renal artery from a rat treated as described in *Figure 2*, showing extensive distention of half of the vessel, stretching of the internal lamina, thinning of the wall, and smudging of the muscularis. Periodic acid-Schiff stain; magnification X 145.

chyma. These lesions consisted of focal stretching of the arterial wall, flattening of the internal elastic membrane, and medial necrosis. In the heart and pancreas also there were a few vascular lesions; furthermore, edema and small hemorrhages were in the pancreas.

The evolution of these lesions was studied in eight rats after they each had received one injection of 3 mg. of metaraminol. Four rats died within 24 hours. The other four were killed 10 days later. At autopsy, the kidneys were found to have doubled in size (3.6 gm. as compared with 1.5 gm. in control animals of similar weight). The renal surface was completely distorted by zones of scar tissue (*Fig. 4*). The medullary cortical area contained masses of ill-defined architecture, and necrotic tubules filled with fuchsinophilic material, some of them in the process of repair. In the surrounding cortex, tubules either were closed or were widely dilated with some homogeneous casts. There was some thickening of basement membrane and interstitial fibrosis with focal round-cell infiltration. The medulla was almost free of damage except for some casts. There were no discernible arterial lesions; possibly if they had developed they had already healed.

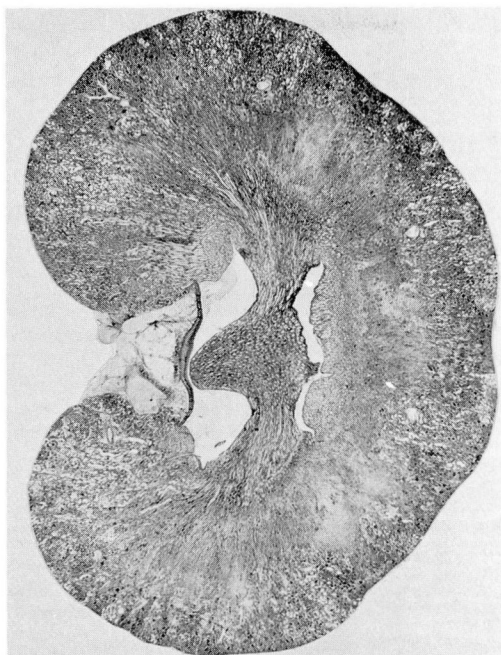

Fig. 4. Kidney from a rat that received 1 dose of 3 mg. of metaraminol and was left without treatment during 10 days, showing a distorted outline due to areas of necrosis and scarring. Note the widespread tubular dilatation. Periodic acid-Schiff stain, magnification X 5.

2. *Effects of hydralazine in metaraminol-treated rats.* Hydralazine prevents renal cortical necrosis caused by large doses of serotonin,^{2,3} as well as occlusive glomerular lesions resulting from injection of renin into desoxycorticosterone-treated rats.⁴ This protective and apparently nonspecific effect of hydralazine led us to the following investigations.

In acute experiments similar to the ones previously described, anesthetized rats received 2 mg. of metaraminol, alone or in combination with 0.5 gm. of hydralazine, while the kidneys were being observed through an abdominal window. Within 20 minutes the kidneys from rats that received metaraminol alone became mottled, whereas kidneys from those on the combined treatment remained normal (Fig. 1) during periods of observation as long as one hour. The general symptoms did not seem to be influenced by hydralazine.

In another experiment, two groups of eight rats that each weighed from 250 to 275 gm. received metaraminol (2 mg. three times daily) alone or in combination with hydralazine (0.5 mg. three times daily) during two days. Six rats while on the course of metaraminol died; those on the course of combined drugs remained alive with no significant loss in weight. At autopsy performed on the third day, no pathologic changes were visible in the metaraminol-hydralazine treated rats,

in contrast to the severe renal necrosis present in the two survivors that had received only metaraminol.

Since hydralazine is a potent antihypertensive drug, it is possible that the beneficial results reported above were due to its inhibiting the pressor effect of metaraminol. We therefore performed experiments in which each drug was tested alone or in combination while blood pressure was continuously recorded with a strain gauge connected to an indwelling aortic catheter. These experiments were performed in 15 unanesthetized rats placed in restraining cages. Subcutaneous injection of 2 mg. of metaraminol caused a rapid rise in blood pressure with a maximum level in from 8 to 15 minutes later, averaging 72 mm. of Hg above base level. A subsequent return to near normal level was reached between the third and fourth hour. Injection of 0.5 mg. of hydralazine elicited a fall in blood pressure, which averaged 34 mm. of Hg about one hour later; this was followed by a slow return to normal pressure within from 6 to 24 hours. Finally when hydralazine (0.5 mg.) and metaraminol (2 mg.) were given simultaneously there was a rise in blood pressure with a maximum average of 65 mm. of Hg above base level within about 10 minutes, then a return to normal within about one hour. Representative graphs from these various recordings are reproduced in *Figure 5*. Comparison of the pressor responses after injections of metaraminol with those after injections of metaraminol plus hydralazine indicates no difference except for a faster return to normal levels after the combined injections.

3. *Effects of metaraminol in desoxycorticosterone-treated rats.* Injection of semi-purified renin into rats pretreated with desoxycorticosterone acetate (DCA) elicits an acute syndrome of hypertension, oliguria, retention of water, vascular lesions, and renal failure. It has been assumed that these acute effects result from an enhancement of the pressor and vasoconstrictor activities of renin by desoxycorticosterone plus salt.⁵ Metaraminol was therefore used to test this hypothesis. It should be mentioned that contrary to the effects caused by metaraminol, large doses of renin are not followed by the development of vascular or renal lesions in normal rats.⁶ Rats that weighed from 90 to 105 gm. were uninephrectomized and comprised three groups. Animals of groups 1 and 2 each received daily doses of 1 mg. of DCA while those of group 3 were untreated. All the animals received 1 per cent saline solution to drink and were housed in metabolism cages. On the twenty-first day, animals of group 1 received 30 Goldblatt dog units of a semi-purified renin preparation three times daily. Animals of groups 2 and 3 were each injected three times daily with 1-mg. doses of metaraminol, a dosage just sufficient to cause mild renal lesions. Three of six rats in group 1 showed symptoms and pathologic changes characteristic of the DCA renin disease; one rat died within 24 hours. These symptoms, though, were absent in rats that received DCA plus metaraminol. There were no differences in effects in rats treated with DCA plus metaraminol and in those treated with metaraminol alone, except for relative oliguria in the former group as compared with some polyuria in the latter. Since

oliguria was not associated with increased appetite for salt as occurs with injections of renin, there was no retention of water. The results of these experiments therefore suggest that renin possesses a property or a combination of properties other than pressor and vasoconstrictor, which are unique and necessary to elicit vascular and renal changes in sensitized animals.

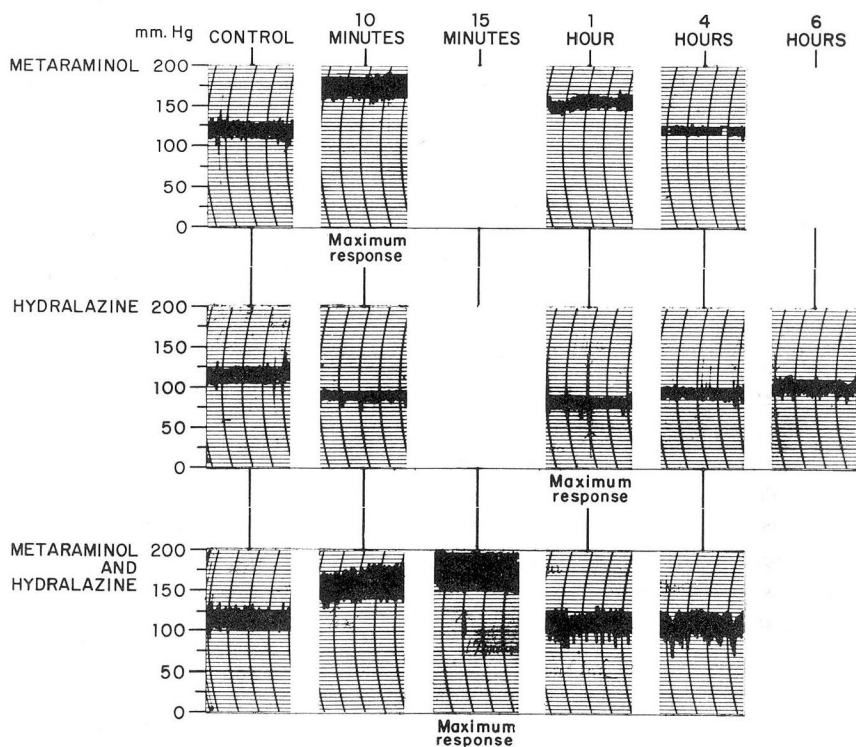


Fig. 5. Representative graphs of arterial pressure recordings in conscious rats immediately after injections of metaraminol, hydralazine, and metaraminol plus hydralazine.

Discussion

The lesions described are similar to those occurring after overdosage with various vasoactive agents. Thus, renal and vascular lesions have been elicited with vasopressin⁷ and methoxamine,⁸ and renal necrosis with serotonin.⁹ These drugs, including metaraminol have the common property of being renal vasoconstrictors. They also cause a rise in blood pressure, with the exception of serotonin, which is a depressor.¹⁰ It appears, therefore, that renal necrosis is due to renal vasoconstriction, and vascular necrosis is due to high blood pressure acting either alone or in association with vasoconstriction. The facts that the renal necrosis is not accompanied by the vascular lesions that develop after injections of serotonin, and that the vascular necrosis is not related to the severity of renal damage, indi-

cate that renal failure is not an essential contributory factor to vascular pathologic changes.

The pathologic effects of metaraminol and of other pressor drugs are somewhat similar to those produced by repeated forced injections of saline solution into the carotid artery of rats.¹¹⁻¹³ Each injection causes a sudden, fleeting rise in aortic pressure even though saline solution is still being injected. Renal necrosis is less severe than that after injection of pressor drugs, but vascular lesions are basically similar: they are restricted to arteries, which are distended and necrotic.

These experiments and those with vasopressin have led to the concept that hypertensive vascular disease results from the mechanical effects of high blood pressure; overdilatation and vasospasm of arteries would lead to necrosis of muscle.¹¹ There are, however, notable differences in the distribution of lesions in hypertension induced by forced injections of saline solution or pressor drugs, and renal hypertension. In artificial hypertension, arteries mostly are affected. In renal hypertension necrosis predominates in renal arterioles and glomeruli; when present, arterial necrosis always occurs in mesenteric and pancreatic arteries and is associated with perivascular inflammation. These differences should not be construed as negating the role of pressure in the genesis of hypertensive vascular disease, but merely as reflecting the speed at which blood pressure is raised in these two different situations. There is considerable evidence suggesting that high blood pressure is a prime requisite to development of hypertensive vascular disease¹⁴ and that vascular lesions result from vasospasm.¹⁵

Hydralazine inhibits the morphologic effects of metaraminol. Similarly, it prevents renal necrosis due to serotonin,^{2,3} and renal and vascular lesions caused by injection of renin in DCA-treated rats.⁴ It prevents or remits hypertensive vascular disease.¹⁴ Although hydralazine is well known for its antihypertensive effects, this mechanism does not provide a satisfactory basis to explain the prevention of tissue damage. It was first believed that maintenance of blood pressure at normal levels was necessary to prevent vascular disease,¹⁶ but subsequently it was shown¹⁷ that the same effects could be obtained by intermittent treatment in spite of wide daily fluctuations in blood pressure. Since renal necrosis elicited by serotonin is associated with hypertension, it is unlikely that hydralazine acts through its hypotensive effect. The other property of hydralazine, which is its ability to augment blood flow in the kidneys and viscera,¹⁸ would best account for the beneficial effects of hydralazine.

Even considering possible differences in sensitivity, the doses of metaraminol needed to produce pathologic changes in rats are enormous as compared with the doses recommended for clinical purposes. There are no indications that similar pathologic effects would occur in man. In this respect, it is worth noting that although renal necrosis in rats has been elicited with serotonin, no renal changes have been reported in patients with carcinoid tumors that secrete large amounts of serotonin.

Summary

In rats, subcutaneous administration of metaraminol at dosages between 2 and 6 mg. was followed by the development of renal necrosis and vascular lesions. These lesions predominantly affected arteries, including renal arteries, which showed focal distention and muscle necrosis. These pathologic changes were prevented by simultaneous treatment with hydralazine at dosages that do not significantly inhibit the pressor effect of metaraminol.

Acknowledgments

Metaraminol bitartrate as Aramine was supplied through the courtesy of Merck & Co., Inc., Rahway, New Jersey; hydralazine hydrochloride as Apresoline, and desoxycorticosterone acetate were supplied through the courtesy of Ciba Pharmaceutical Products, Inc., Summit, New Jersey.

References

1. Sollman, T.: *A Manual of Pharmacology and Its Applications to Therapeutics and Toxicology*, 8th ed. Philadelphia: W. B. Saunders Co., 1957, 1535 p.; p. 508.
2. Brosman, S. A.; Bradford, P. F., and Hughes, F. W.: Modification of renal lesions produced by 5-hydroxytryptamine (serotonin). *Am. J. Clin. Path.* 32: 457-464, 1959.
3. Jasmin, G., and Bois, P.: Effect of various agents on development of kidney infarcts in rats treated with serotonin. *Lab. Invest.* 9: 503-515, 1960.
4. Renzi, A. A., and Gaunt, R.: Apresoline (1-hydrazinophthalazine) in experimental 'eclampsia-like' syndrome and related aspects of water metabolism. *Am. J. Physiol.* 175: 313-318, 1953.
5. Masson, G. M. C.; del Greco, F.; Corcoran, A. C., and Page, I. H.: Acute diffuse vascular disease elicited by renin in rats pretreated with cortisone. *A.M.A. Arch. Path.* 56: 23-35, 1953.
6. Masson, G. M. C.; Corcoran, A. C., and Page, I. H.: Some effects of chronic treatment of rats with renin. *Am. J. Physiol.* 162: 379-384, 1950.
7. Byrom, F. B.: Morbid effects of vasopressin on organs and vessels of rats. *J. Path. & Bact.* 45: 1-16, 1937.
8. Herbertson, B. M., and Kellaway, T. D.: Arterial necrosis in rat produced by methoxamine. *J. Path. & Bact.* 80: 87-92, 1960.
9. Page, E. W., and Glendening, M. B.: Production of renal cortical necrosis with serotonin (5-hydroxytryptamine); theoretical relationship to abruptio placentae. *Obst. & Gynec.* 5: 781-788, 1955.
10. Page, I. H.: Serotonin (5-hydroxytryptamine). *Physiol. Rev.* 34: 563-588, 1954.
11. Byrom, F. B., and Dodson, L. F.: Causation of acute arterial necrosis in hypertensive disease. *J. Path. & Bact.* 60: 357-368, 1948.
12. Masson, G. M. C.; Corcoran, A. C., and Page, I. H.: Rôle du rein dans l'hypertension expérimentale chez le rat. *Rev. canad. biol.* 10: 309-332, 1951.

13. Wolfgarten, M., and Magarey, F. R.: Vascular fibrinoid necrosis in hypertension. *J. Path. & Bact.* 77: 597-603, 1959.
14. Masson, G. M. C.; Corcoran, A. C., and Page, I. H.: High arterial pressure as primary cause of hypertensive vascular lesions. *Cleveland Clin. Quart.* 26: 24-35, 1959.
15. Byrom, F. B.: Pathogenesis of hypertensive encephalopathy and its relation to malignant phase of hypertension; experimental evidence from hypertensive rat. *Lancet* 2: 201-211, 1954.
16. Masson, G. M. C.; McCormack, L. J.; Dustan, H. P., and Corcoran, A. C.: Hypertensive vascular disease as consequence of increased arterial pressure; quantitative study in rats with hydralazine-treated renal hypertension. *Am. J. Path.* 34: 817-833, 1958.
17. Gardner, D. L.: Relationship between intermittent hypotension and prevention by hydralazine of acute vascular disease in rats with steroid hypertension. *Brit. J. Exper. Path.* 41: 60-71, 1960.
18. Stunkard, A.; Wertheimer, L., and Redisch, W.: Studies on hydralazine; evidence for peripheral site of action. *J. Clin. Invest.* 31: 1047-1053, 1954.