

# HEPATIC GLYCOGEN-STORAGE DISEASE WITH ACIDOSIS IN THE NEONATE

## Report of a Case

DERRICK LONSDALE, M.D.,\* MARY C. HARMON, M.D.,†  
and ROBERT D. MERCER, M.D.

*Department of Pediatrics*

**H**EPATIC glycogen-storage disease, or Von Gierke's disease, is characterized by a deficiency of the specific enzyme, glucose-6-phosphatase,<sup>1-4</sup> which catalyzes the production of glucose from glucose-6-phosphate in the liver. The disease is manifested by hypoglycemia, acidosis, ketonuria, abnormal deposition of subcutaneous fat, lipemia, retardation of growth, and hepatomegaly without an enlarged spleen.

## Case Report

A five-day-old boy was admitted to the Cleveland Clinic Hospital in May, 1960, because of difficulty in breathing during feeding. The pregnancy and the labor had been normal. Although the mother's blood group was Rh negative, no antibodies had been detected in her serum. On the third day of life, grunting and gasping occurred in the infant during feeding. The difficulty in breathing persisted until his admission to the hospital.

Examination revealed a moderately dehydrated male infant who weighed 3 kg. The pulse rate was 132 with a regular sinus rhythm, and the respirations were grunting and rapid. The lungs were clear to auscultation and the heart was normal in size. The abdomen was distended and the liver was soft. The lower edge of the liver was at the level of the right iliac crest. There was some pitting edema of the legs. The heart sounds were weak but there was no venous distention. The clinical impression was that the infant's condition resulted from a primary metabolic problem, and electrolyte studies revealed a profound metabolic acidosis. The serum determinations were: carbon dioxide, 5 mEq. per 100 ml.; sodium, 143 mEq.; potassium, 6.3 mEq.; chloride, 109 mEq. per 100 ml.; pH, 7.29. Blood sugar concentration at this time was 27 mg. per 100 ml. Results of liver function tests were normal, although the serum glutamic oxaloacetic transaminase value was 400 units. A liver biopsy was considered, but was postponed because of the regression in the size of the liver and the general improvement in the infant's condition. He was discharged from the hospital at the age of one month, without a definite diagnosis and without hepatomegaly.

*Second admission to the hospital.* At the age of three months the infant was readmitted to the hospital because of tremors of the arms and legs, mild recurrent fever, and significant enlargement of the liver. The baby was rather large and fat, with no edema. There was slight hirsutism, and the liver was palpable two and one-half fingerbreadths

\*Fellow in the Department of Pediatrics.

†Formerly Member of the Staff; present address: 6760 Mayfield Road, Mayfield Heights 24, Ohio.

below the right costal margin. He was alert but exhibited poor neck tone, general irritability, and bilateral ankle clonus. Electrolyte studies revealed a moderate acidosis. There was no significant hypoglycemia. The urine was negative for acetone. The glucose tolerance curve showed a peak of 259 mg. per 100 ml. at the first hour, and a plateau between the second and third hours with no secondary peak (*Fig. 1*). Glycogen-storage disease was suspected, and a liver biopsy specimen was obtained at laparotomy. The liver was grossly enlarged, pale, and rubbery in consistency. Chemical analysis showed the glycogen content of the biopsy specimen to range between 2.75 per cent and 5.5 per cent by weight. Stained sections appeared to be consistent with a diagnosis of glycogen-storage disease. The patient was discharged from the hospital, and was to receive frequent carbohydrate feedings.

*Third admission to the hospital.* The infant was readmitted to the hospital at the age of four months because of persistent trembling spells and flushing of the face. Episodes of hyperventilation recurred. The urine was positive for acetone, and there was some increase in the total serum lipid concentration. A profound hypoglycemia was the most prominent finding; the blood sugar concentration was less than 10 mg. per 100 ml. A striking feature was that convulsions were rare even with profound hypoglycemia. A diet containing 900 calories, of which 40 per cent were protein, was given, and resulted in improvement in his general condition. Convulsive episodes ceased, although hypoglycemia, particularly in the mornings, persisted. An injection of 1:1000 of epinephrine caused the blood sugar concentration to decrease (*Fig. 1*). A glucagon test was performed, and this demonstrated no increase in the concentration of the blood sugar (*Fig. 1*). The blood sugar concentration remained satisfactory for four hours after a

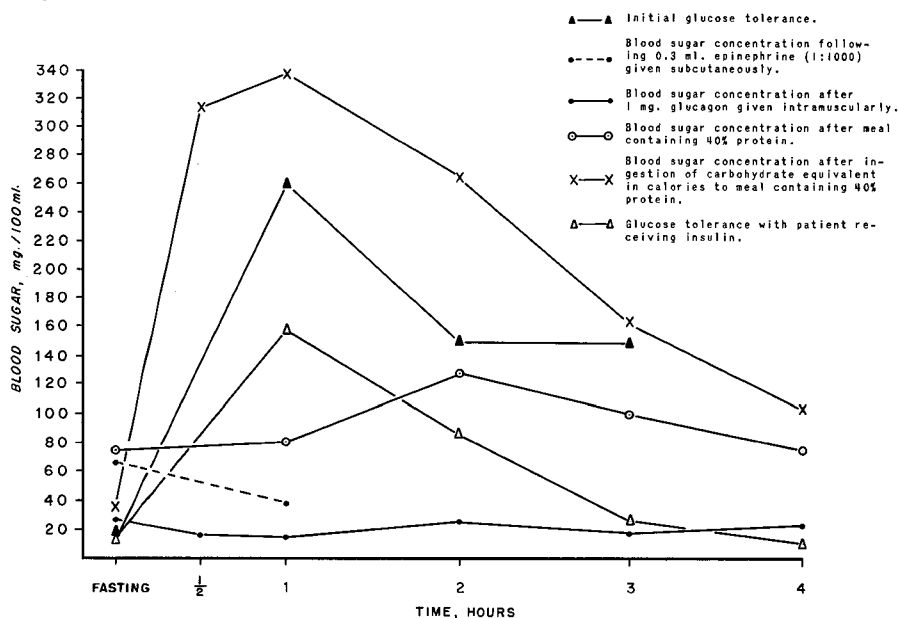


Fig. 1. Graph showing results of glucose tolerance tests in an infant having glycogen-storage disease.

high-protein meal without the hyperglycemic response that was demonstrated when a duplicate protein meal was converted into its caloric equivalent and was administered as pure carbohydrate (*Fig. 1*). The serum lipid content gradually increased to 2,630 mg. per 100 ml., and periods of fever and irritability developed which were thought to be due to protein dehydration. The urine solute concentration was 1,034 m-osM. per liter, with a specific gravity of 1.025. The diet was changed to a high-carbohydrate intake, and daily injections of 20 units of adrenocorticotropin (ACTH) gel were started. Because of the continued increase in serum lipid concentration, the administration of 5 units of lente insulin daily was begun, and the dosage of ACTH gel was reduced to 10 units daily. It was hoped that insulin would reduce the concentration of serum lipids; it seemed to have no effect on the hypoglycemia. On this regimen his condition appeared to be satisfactory and he was discharged from the hospital.

*Fourth admission to the hospital.* The patient was again admitted to the hospital, at the age of five and one-half months. He had remained well and showed no signs of his previous irritability. The urine had remained free of acetone. He was cushingoid in appearance, and the administration of ACTH gel was discontinued. The blood cholesterol concentration was 675 mg. per 100 ml., and the total serum lipid concentration had increased to 4,950 mg. per 100 ml. The glucose tolerance test showed a flat curve (*Fig. 1*). Acetonuria was present. Because of recurrent convulsions due to hypoglycemia the administration of insulin was stopped, and the diet was reduced to 700 calories with 40 per cent protein. Administration of sodium-d-thyroxine was started in a dosage of 2 mg. daily in an effort to lower the high concentration of serum lipids. During the next few days he became increasingly irritable with fever and episodes of vomiting. Electrolyte studies revealed a profound acidosis, which was counteracted by intravenous injection of a solution of sodium bicarbonate. With the use of a high-protein, high-caloric, low-salt diet the infant improved and was again discharged from the hospital.

At the age of nine months, the patient was reported by his parents to be doing well. He was then beginning to sit up, and had lost much of the excess adipose tissue. There was much less irritability than formerly, and he was gaining weight satisfactorily on a diet of three high-protein meals daily.

### Discussion

The principal signs and symptoms of glycogen-storage disease due to glucose-6-phosphatase deficiency are as follows: (1) a large liver in the absence of splenomegaly; (2) low fasting blood sugar concentration with or without convulsions; (3) recurrent acidosis and ketosis as reflected by low carbon dioxide combining power, and by ketonuria with physical signs of acidosis; (4) no effect on glycemia from injection of epinephrine or of glucagon; (5) an abnormally high and often doubly peaked glucose tolerance curve, indicating a slow utilization of glucose; and (6) a normal galactose or fructose tolerance curve. Only a few patients have been reported to have had symptoms in the neonatal period.<sup>5,6</sup> These symptoms included rapid respirations, acidosis, and dehydration, ranging in onset from sixteen hours to four days after birth. Symptoms and signs are more severe when

they present in the infant than when they first appear in the older age group. This clinical observation received biochemical support when it was demonstrated that the younger patients had more pronounced enzyme deficiency than did the older patients; infants appeared to be able to produce more enzyme as they grew older.<sup>7,8</sup> Since acidosis and fatty liver are not unusual in infants, it is possible that some cases of glycogen-storage disease are not diagnosed.

No alteration in renal function has been observed, although glycogen-storage occurs in the kidney in this disease. Ketonuria, severe acidosis, and lipemia are constant features of the disease, and treatment has always been aimed at raising the concentration of the blood sugar. In 1949, Lowrey and Wilson<sup>9</sup> demonstrated a moderate but prolonged rise in blood sugar concentration in a child having glycogen-storage disease, who received 1.7 gm. of gelatin per kilogram of body weight. The child thrived on three meals a day containing 40 per cent protein. The mechanism is somewhat obscure as a source of free glucose.

Glucagon has been administered in an effort to stimulate glycogenolysis, but it has been shown to be of no value in the hepatic type of glycogen-storage disease;<sup>6</sup> as will be discussed, it may be actually harmful in stimulating a metabolic acidosis. Some patients respond favorably to the administration of ACTH. It probably stimulates the adrenal cortex to produce extra amounts of the so-called "S hormones" that stimulate gluconeogenesis. The effects of ACTH are well documented for this disease,<sup>10</sup> and it has been pointed out that despite favorable clinical response the hypoglycemia remained.

The Emden-Meyerhof metabolic pathway is concerned with glycogenesis and glycogenolysis in the liver. The only means of providing free glucose is through the conversion of glucose-6-phosphate by its specific enzyme. The alternative pathways that are available to glucose-6-phosphate are: (1) conversion to glycogen; (2) conversion to fructose-6-phosphate, cleavage to two triosephosphates, and thence to pyruvate and lactate; and (3) oxidation to 6 phosphogluconic acid in the hexose monophosphate shunt in which a pentose sugar is formed. Eventually heptoses and trioses may form, with the release of energy, and it has been shown that this mechanism may account for as much as 20 per cent of the glucose metabolized.<sup>11</sup> In this connection, Bridge and Holt<sup>12</sup> reported a case of glycogen-storage disease in which the urine contained a reducing substance that they were unable to identify but which gave reactions characteristic of the pentose group. Pyruvic acid and lactic acid represent the terminal of anaerobic carbohydrate breakdown, and an alternative pathway in the oxidation of most amino acids.

If, therefore, the only pathway by which free glucose may be formed is blocked, it would seem that any attempt to stimulate glycogen breakdown would result in the use of alternative pathways. In this way a parallel might be drawn between this disease and uncontrolled diabetes. In glycogen-storage disease there is an excess of glycogen that cannot be utilized, and in uncontrolled diabetes the glycogen reserves have been exhausted. The biochemical disturbance in the two

diseases is somewhat similar, such as the occurrence of acidosis. The acidosis, ketonuria, and lipemia have generally been attributed to starvation, and Andersen<sup>13</sup> compared the appearance of the liver in this disease to that in uncontrolled diabetes. Much of the enlargement is due to deposition of fat in this organ.

Unlike diabetes, however, lactic acid increases in the blood in glycogen-storage disease, and levulose also causes high lactic acid concentrations but no increase in the blood sugar content.<sup>14</sup>

It has been shown that thyroxine increased the metabolic rate by stimulating glycogenolysis,<sup>15</sup> and that glucagon acts in the same way by activating hepatic phosphorylase.<sup>16</sup> In the case reported here, sodium-D-thyroxine was given in an effort to decrease the degree of the lipemia. A few days later the patient was in a state of profound acidosis that was thought to be due to the release of lactic acid and pyruvate from the liver as a result of phosphorylation of glycogen. Glucagon probably produces acidosis in the same way by activating hepatic phosphorylase, and thus would be most inappropriate in the treatment of this disease.

The abnormal fat metabolism leads to excessive fat deposits in the liver, in other organs, and in all fat depots in the body. White, Handler, Smith, and Stetten<sup>17</sup> showed by isotopic studies that fat is first deposited in the fat depots. With the disappearance or unavailability of hepatic glycogen, this depot fat is mobilized by a process catalyzed by an ill-defined hormone known as adipokin, with the adrenal corticoids acting in permissive fashion. The excessive metabolism of fats leads to excess of acetoacetic acid, and contributes to the development of acidosis and ketonuria.

The diabetic type of glucose tolerance curve that is commonly described in association with this disease is difficult to explain. It suggests that the uptake and utilization of glucose is at fault, similar to the condition in uncontrolled diabetes. It is tempting to postulate that, because of the prolonged hypoglycemia, which is a constant feature, the pancreas is no longer stimulated to produce insulin, and the system suffers from hypoinsulinism. Hexokinase is essential to the uptake of glucose in the cell, and has been shown to be inhibited in extracts from muscles of diabetic patients. The inhibition is relieved by insulin that also enhances the activity of hexokinase.<sup>18</sup> Lack of insulin would therefore explain the mechanism of the glucose tolerance curve that occurs in glycogen-storage disease. If this explanation is valid, it is possible that atrophic changes would occur in the cells of the pancreatic islets, which could be seen at necropsy. Von Gierke<sup>19</sup> stressed the absence of changes in the islets, but Faber<sup>20</sup> reported one case in which the number of islets was diminished and some were larger than normal. Similar changes have been reported in newborn babies of diabetic mothers.<sup>21</sup>

The use of insulin in this disease has, however, been condemned. Van Creveld<sup>22</sup> emphasized the sensitivity to small amounts of insulin, and Rauh and Zelson<sup>23</sup> found long-lasting reduction in blood sugar concentrations after the administration of 5 units of insulin. They pointed out that in the presence of

severe hepatic lesions this sensitivity was probably related to hypoglycemia. Unfortunately it was not possible to obtain an insulin assay on our patient. This type of assay might present a useful field of investigation in glycogen-storage disease. In our patient, the administration of insulin appeared to have but one effect: the conversion of the glucose tolerance from abnormal to normal.

### Summary

A case of typical glycogen-storage disease of the liver is described. An unusual feature in this case was the initial presentation in a neonate. Respiratory difficulty, secondary to a profound metabolic acidosis, was the leading symptom. In a discussion of some of the metabolic mechanisms, the occurrence of a secondary hypoinsulinism is suggested; treatment with insulin proved valueless, however, in this case. Attempts to reduce the serum lipid concentration through sodium-d-thyroxin administration resulted in the production of severe acidosis. A high-protein diet was the most effective means of treatment.

### References

1. Cori, G. T.: Glycogen structure and enzyme deficiencies in glycogen storage disease. Harvey Lect., Series 48, 1952-1953. New York: Academic Press Publishers, Inc., 1954, 273 p.; p. 145-171.
2. Harris, R. C., and Olmo, C.: Liver and kidney glucose-6-phosphatase activity in children with normal and diseased organs. *J. Clin. Invest.* 33: 1204-1209, 1954.
3. Cori, G. T., and Schulman, J. L.: Glycogen storage disease of liver; enzymic studies. *Pediatrics* 14: 646-650, 1954.
4. Chiquoine, A. D.: Distribution of glucose-6-phosphatase in liver and kidney of mouse. *J. Histochem.* 1: 429-435, 1953.
5. Mason, H. H., and Andersen, D. H.: Glycogen disease. *Am. J. Dis. Child.* 61: 795-825, 1941.
6. Schulman, J. L., and Saturen, P.: Glycogen storage disease of liver; clinical studies during early neonatal period. *Pediatrics* 14: 632-643, 1954.
7. Cori, G. T., and Cori, C. F.: Glucose-6-phosphatase of liver in glycogen storage disease. *J. Biol. Chem.* 199: 661-667, 1952.
8. Illingworth, B.; Lerner, J., and Cori, G. T.: Structure of glycogens and amylopectins. I. Enzymatic determination of chain length. *J. Biol. Chem.* 199: 631-640, 1952.
9. Lowrey, G. H., and Wilson, J. L.: Observations on treatment of case of glycogen storage disease. *J. Pediat.* 35: 702-709, 1949.
10. Ulstrom, R. A.; Ziegler, M. R.; Doeden, D., and McQuarrie, I.: Metabolic and clinical effects of corticotropin (ACTH) on essential glycogenosis (von Gierke's disease). *Metabolism* 1: 291-299, 1952.
11. Stetten, deW., Jr., and Topper, Y. J.: Metabolism of carbohydrates; review. *Am. J. Med.* 19: 96-110, 1955.
12. Bridge, E. M., and Holt, L. E., Jr.: Glycogen storage disease; observations on pathologic physiology of 2 cases of hepatic form of disease. *J. Pediat.* 27: 299-315, 1945.

13. Andersen, D. H.: Miscellaneous disorders of metabolism: V; glycogen storage diseases and galactosaemia, chap. 18, p. 685-696, *in* Thompson, R. H. S., and King, E. J., editors: *Biochemical Disorders in Human Disease*. New York: Academic Press Inc., Publishers, 1957, 843 p.
14. Mason, H. H., and Sly, G. E.: Blood lactic acid in liver glycogen disease. *Proc. Soc. Exper. Biol. & Med.* 53: 145-147, 1943.
15. Maley, G. F., and Lardy, H.: Efficiency of phosphorylation in selected oxidations by mitochondria from normal and thyrotoxic rat livers. *J. Biol. Chem.* 215: 377-388, 1955.
16. Collens, W. S., and Murlin, J. R.: Hyperglycemia following portal injection of insulin. *Proc. Soc. Exper. Biol. & Med.* 26: 485-490, 1929.
17. White, A.; Handler, P.; Smith, E. L., and Stetten, deW., Jr.: *Principles of Biochemistry*. New York: McGraw-Hill Book Co., Inc., 1954, 1117 p.; p. 474.
18. Colowick, S. P.; Cori, G. T., and Slein, M. W.: Effect of adrenal cortex and anterior pituitary extracts and insulin on hexokinase reaction. *J. Biol. Chem.* 168: 583-596, 1947.
19. von Gierke, S.: Über Glykogenspeicherkkrankheit. *Beitr. z. path. Anat. u. z. allg. Path.* 99: 369-384, 1937.
20. Faber, V.: Über die Glykogenkrankheit (Hepatonephromegalia glykogenica). *Frankfurt. Ztschr. f. Path.* 47: 443-453, 1935.
21. Potter, E. L.; Seckel, H. P. G., and Stryker, W. A.: Hypertrophy and hyperplasia of islets of Langerhans of fetus and of newborn infant. *Arch. Path.* 31: 467-482, 1941.
22. van Creveld, S.: Glycogen disease. *Medicine* 18: 1-128, 1939.
23. Rauh, L., and Zelson, C.: Disturbance in glycogen metabolism with hepatomegaly (von Gierke's disease). *Am. J. Dis. Child.* 47: 808-820, 1934.