

# Cleveland Clinic Quarterly

Volume 29

OCTOBER 1962

No. 4

## DEFECTS OF THE MITRAL VALVE

### Current Concepts of Surgical Treatment

DONALD B. EFFLER, M.D.

*Department of Thoracic Surgery*

**T**HE initial work of Bailey, Glover, and O'Neill,<sup>1</sup> and Harken, Ellis, and Norman,<sup>2</sup> and others<sup>3</sup> in 1950 aroused widespread interest in the surgical treatment of mitral valvular heart disease. Within a short time a large number of patients having such disease were being operated upon in various surgical centers. The original operations utilized the left transatrial approach that permitted either instrumental or finger-fracture commissurotomy. Enthusiastic early reports indicated that the closed approach was adequate in the majority of patients who suffered from pure mitral stenosis with noncalcified valves.

However, it was soon apparent that the closed-type of mitral commissurotomy always involved some element of risk related to postoperative embolization, recurrent stenosis, and chirurgic insufficiency. Cardiac surgeons quickly found that the insufficiency created by laceration of chordae tendineae or of either mitral cusp was a complication frequently less well tolerated than the preexisting stenosis. Bailey and Morse<sup>4</sup> abandoned the left, transatrial operation on the mitral valve for the right, interatrial approach in an attempt to reduce attendant complications and to improve valvotomy results. In other surgical centers the transventricular approach, which employed some form of valve dilator, has become the method of choice. The multiplicity of operations that followed the original "standard operation" for mitral stenosis is testimony that there is a need for continued improvement in the surgical treatment of mitral stenosis.

In 1958, we reported our early experience with the open operations for mitral insufficiency.<sup>5</sup> Our clinical experience at that time was limited to 14 operations in which some form of annuloplasty or valvuloplasty had been attempted to restore mitral valve competency. From that experience we concluded that these operations appeared to be palliative only, and that the definitive treatment for mitral insufficiency would require prosthetic valve replacement.<sup>5</sup> In retrospect, that conclusion summarizes the total value of the initial report. In our experience, annuloplasty and selective types of valvuloplasty to restore mitral valve competency have not withstood the test of time.

At this writing I am convinced that the surgical problems related to various types of mitral valve defects are by no means resolved. The progress made during the last one and one-half decades has brought untold benefit to a great many patients who have suffered from all forms of valvular heart disease. Nevertheless, the ultimate goal has not been accomplished, and the entire subject remains in a state of surgical flux and a state of surgical progress. It is the purpose of this paper to outline in brief our current concepts in the surgical treatment of common mitral valve deformities.

### Mitral Stenosis

*Pathologic findings.* Many clinicians have a stylized concept of the morbid anatomy related to mitral stenosis. Most of the illustrations that accompany scientific papers dealing with this subject depict the so-called fishmouth type of stenosed valve. These illustrations present a centrally placed orifice, bordered on each side by fibrosed commissures. Actually, mitral stenosis represents a variety of pathologic types.

The simple form mentioned above does occur, particularly in young women who have not suffered from superimposed bacterial infection or recurrent valvulitis. This type of stenosed valve is amenable to correction with almost any of the established methods mentioned above. Mitral stenosis, however, can be associated with calcification of the commissures, of the valve cusps, and of the annulus itself. Excessive calcification impairs valve mobility, and the outcome after adequate commissurotomy may be disappointing, because of residual inflexibility. The likelihood of embolization plus the prospects of creating insufficiency increase the expected surgical risk. The valve that has become restenosed after commissurotomy usually falls into this category, because the formation of calcium commonly accompanies re-fusion of the commissures.

Another form of mitral stenosis is that associated with subvalvular fusion of the underlying chordae tendineae and the papillary muscles. This fusion, most commonly encountered under the medial commissure, can be resistant either to finger-fracture or to instrumentation. Closed operations on the subvalvular type of mitral stenosis carry appreciable risk, as surgical laceration of major chordae results in a

flail cusp. The abrupt addition of significant mitral insufficiency may be tolerated poorly by the patient who is operated upon for pure stenosis.

Pure mitral stenosis may occur in other forms, but the simple fishmouth, the heavily calcified, and the subvalvular types are the most frequent forms encountered at operation. It is well to remember that mitral stenosis, although fairly constant from the standpoint of physiologic disturbance, may demonstrate variety in morbid anatomy. It is unreasonable, therefore, to expect any single operative approach to solve every problem related to the stenotic mitral valve.

*Operative technic.* A number of surgical centers utilize the open-heart approach as routine for surgical treatment of mitral stenosis. At the Cleveland Clinic Hospital, Dr. Laurence K. Groves and I use the closed-heart approach in the majority, but not in all, operations upon the stenotic valve. We employ three types of operative approach; a brief outline of the rationale for this selection follows.

Patients who present, by clinical evaluation, the simple form of mitral stenosis are operated upon by the closed-heart right-sided approach. Relief of stenosis is usually accomplished by finger-fracture commissurotomy. In the simple form of stenosis the results are uniformly good, and the right anterolateral thoracotomy is conducive to a benign postoperative course with a low incidence of morbidity.

The left posterolateral approach to the mitral valve with auricular appendectomy is employed, but less frequently than in past years. We reserve this operation for patients who are admitted after significant embolic accident. When clinical evidence suggests that the source of embolus was the left atrium or its appendix, a combined operation may be performed on an emergency basis. The closed left transatrial approach to the mitral valve with auricular appendectomy will be performed and, when indications are present, peripheral embolectomy will then be undertaken immediately. Although the right-sided closed approach permits better commissurotomy technic, we do reserve the original left transatrial operation for those patients in whom the benefit of auricular appendectomy outweighs the advantages of the right-sided entry.

Utilization of a mechanical dilator by the transventricular, or the transatrial approach, enjoys current popularity in a number of surgical centers. We have never used this technic and, therefore, are not qualified to express an opinion on this method of treatment for the stenotic mitral valve.

The advent of open-heart surgery would seem to offer the logical solution to all problems related to mitral stenosis. The open-heart approach that utilizes extracorporeal circulation may become the only acceptable technic for treating mitral stenosis. At the present time, however, this is not the case. In our own institution extracorporeal circulation adds a significant factor in basic economy. This includes: increased costs, additional demands upon the blood bank, lengthened hospital stay, and some increased risk to the patient. Ideally, these factors of time, costs, and effort should not be decisive in selecting operative methods; but in harsh reality,

these must be considered in the day-to-day workings of a private hospital. It is for these reasons that we reserve the open-heart approach for selected cases of mitral stenosis, specifically those in which (1) extensive calcification is evident, (2) there is evidence of combined stenosis and insufficiency, (3) a previous closed-heart approach has been unsuccessful, or (4) valvular restenosis has occurred.

The choice between the open- and the closed-heart operations for mitral stenosis requires greater precision in clinical evaluation than ever before. For this reason, physiologic study that includes right and left heart catheterization with cinecardiography is employed in the majority of patients considered for surgical treatment. A clear-cut diagnosis of mitral stenosis may not suffice. In many patients the specific details of valvular architecture, the presence of unusual thrombus, the coexistence of valvular insufficiency and the status of the coronary arteries will influence the surgical treatment. These related features may be evaluated by cardiac catheterization study.\*

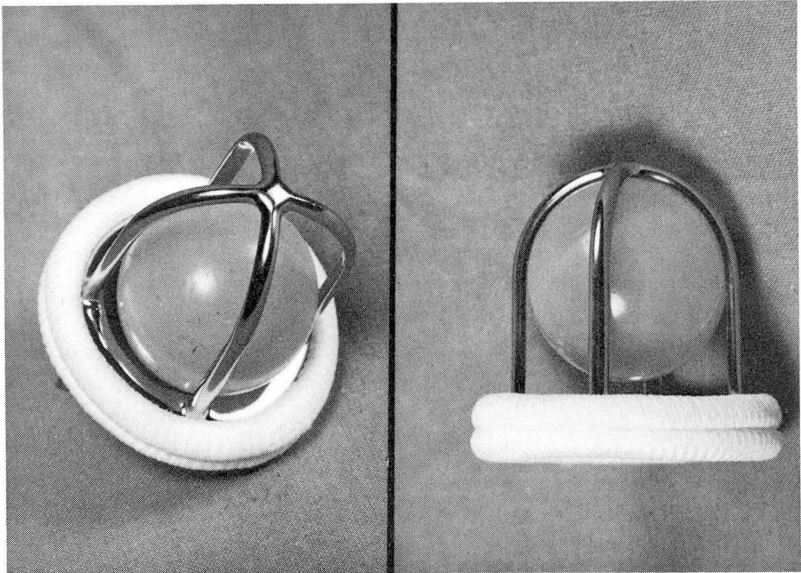


Fig. 1. Starr-Edwards prosthetic mitral valve manufactured by Edwards Laboratories, Inc., 603-H Alton Street, Santa Ana, California.

### Mitral Insufficiency

*Pathologic findings.* Mitral insufficiency results from a variety of pathologic processes. Each of these presents its own variations in morbid anatomy, and its

\*Cardiac catheterization and related studies are performed in the Cardiac Laboratory, under the direction of Dr. F. Mason Sones, Jr., and Dr. Earl K. Shirey.

own peculiar problems from the standpoint of surgical repair. Whereas the physiologic disturbances of mitral valve incompetency are easily recognized, the specific anatomic disturbance of the mitral valve is not always apparent. The anatomic features of mitral insufficiency may be particularly difficult to evaluate during autopsy, when the heart is inert and the tissues are altered by initial postmortem change. Operating room experience has taught us that there is more to mitral valve incompetency than leaflet disease alone; the related chordae tendineae, the papillary muscles and, indeed, the entire left ventricular myocardium may play an essential role in producing this disease.

Incompetency of the mitral valve may be attributed to any of the following situations: (1) dilatation of the annulus, (2) rupture of the chordae tendineae, (3) shortening of the chordae tendineae, (4) fenestration of the leaflets, (5) calcareous distortion of the leaflets, (6) loss of leaflet substances resulting from valvulitis, and (7) surgical laceration during attempted commissurotomy. Mitral insufficiency does result from a variety of disease processes in some of which the leaflets themselves are not anatomically disturbed, even though they may be rendered functionally inadequate. If this principle is appreciated by the clinician and the surgeon, it follows that no single operative procedure short of total valve replacement can offer relief for every type of mitral insufficiency.

*Experience.* Since the 1958 report,<sup>5</sup> we have persisted in our efforts to treat selected patients who have mitral insufficiency. In every operation the direct, open-heart approach was used;\* the closed-heart procedures advocated for mitral insufficiency have been, in our opinion, of little value. In the interest of brevity our clinical experience will not be detailed in this report; only our observations and conclusions are pertinent. In essence, the various technics of valvuloplasty and annuloplasty, as they have been employed here, have been of limited value to the patients. In other words, the over-all long-term results have been uniformly disappointing even though the initial response in physiologic improvement and the patient's own recovery were most encouraging. Continued clinical observation indicates that the beneficial effects initially obtained from these palliative procedures have been of short duration only.

At this writing it is my belief that the patient who requires surgical treatment of mitral insufficiency is best treated by the use of a prosthetic valve replacement. Our own experience is confined entirely to the Starr-Edwards† mitral valve.<sup>6</sup> To date we have operated upon 22 patients in whom the diseased mitral valve was replaced by this form of prosthetic device. The initial results in those patients who have survived operation are most encouraging. It is too early to make a final appraisal of

\**Extracorporeal circulation is managed by technicians Miss Rose Litturi and Mr. Fred Brown, under the direction of Willem J. Kolff, M.D., Head of the Department of Artificial Organs.*

†*Edwards Laboratories, Inc., 603-H Alton Street, Santa Ana, California.*

Table 1.—Data of 22 patients surgically treated for defects of the mitral valve

Case no.	Sex	Age, years	Operative date	Disease	Result
1	M	38	9/29/61	Mitral insufficiency	Excellent
2	M	55	10/10/61	Multivalvular: mitral insufficiency, aortic insufficiency and tricuspid insufficiency	Died 72 hours postoperatively from congestive cardiac failure
3	F	26	1/26/62	Mitral insufficiency	Excellent
4	F	44	1/30/62	Mitral stenosis and mitral insufficiency, recurrent	Died 32 days postoperatively from late infection
5	M	39	2/9/62	Mitral stenosis and mitral insufficiency, recurrent	Excellent
6	F	24	3/15/62	Mitral insufficiency, predominant	Excellent
7	F	56	3/16/62	Mitral stenosis with mitral insufficiency, predominant	Excellent
8	F	41	4/2/62	Mitral stenosis, and mitral insufficiency, predominant	Excellent
9	F	53	4/6/62	Intractable failure with mitral insufficiency	Died 24 hours postoperatively
10	M	55	4/26/62	Congenital mitral insufficiency, recurrent. (Initial operative procedure in 1956.)	Initial response excellent; died six weeks postoperatively from dislocated valve
11	M	41	5/11/62	Mitral stenosis predominant, and mitral insufficiency	Excellent
12	M	45	5/18/62	Mitral stenosis and mitral insufficiency, predominant	Improved
13	M	52	6/19/62	Mitral insufficiency	Considerably improved
14	F	45	6/27/62	Calcific mitral stenosis, recurrent. (Two previous operations.)	Initial response excellent; died one month postoperatively from late cerebrovascular accident and infection
15	F	56	7/13/62	Mitral stenosis and mitral insufficiency, recurrent, with significant aortic insufficiency	Definite improvement to date

(Continued)



SURGICAL TREATMENT OF MITRAL VALVE DEFECTS

**Table 1.** (Concluded)—Data of 22 patients surgically treated for defects of the mitral valve

Case no.	Sex	Age, years	Operative date	Disease	Result
16	F	56	7/19/62	Mitral insufficiency, severe	Definite improvement to date
17	F	36	8/29/62	Mitral insufficiency, predominant, recurrent	Early response excellent
18	M	32	9/5/62	Mitral stenosis, calcific, severe with mitral insufficiency	Died three weeks postoperatively from septicemia
19	M	15	9/7/62	Severe mitral insufficiency, intractable congestive failure	Discharged, improved
20	F	33	9/20/62	Severe calcific mitral stenosis and mitral insufficiency	Discharged from hospital, improved
21	F	35	9/21/62	Recurrent mitral stenosis, calcific	Discharged from hospital, improved
22	M	46	10/2/62	Recurrent mitral stenosis, calcific, intractable cardiac failure	Still in hospital, improved

this prosthesis, and our present attitude reflects only initial experience and short-term follow-up evaluation. It is of particular interest, however, that five of these patients have been restudied by left-heart catheterization technics, and objective data suggest complete relief of the physiologic disturbance associated with their preexisting mitral insufficiency.

*Operative technic.* Discussion of complete operative details of Starr-Edwards mitral valve insertion is not pertinent to this report. There are, however, a number of interesting features that will be mentioned in brief. The operative approach to the mitral valve is from the right side as the patient rests in a modified supine position. Extracorporeal circulation is combined with moderate hypothermia. Elective cardiac arrest is neither desirable nor necessary for this type of cardiac surgery. The hazard of system air embolization is reduced by the use of carbon dioxide gas perfusion throughout the operative field. Excision of the diseased mitral valve must be accompanied by removal of the related chordae tendineae and papillary muscle. This is an important point, as residual tissue projections within the left ventricular cavity may interfere with excursion of the plastic ball. The soft teflon annulus of the prosthesis is secured by multiple sutures of three-zero Dacron material. These sutures are placed through a rim of remaining mitral valve tissue,

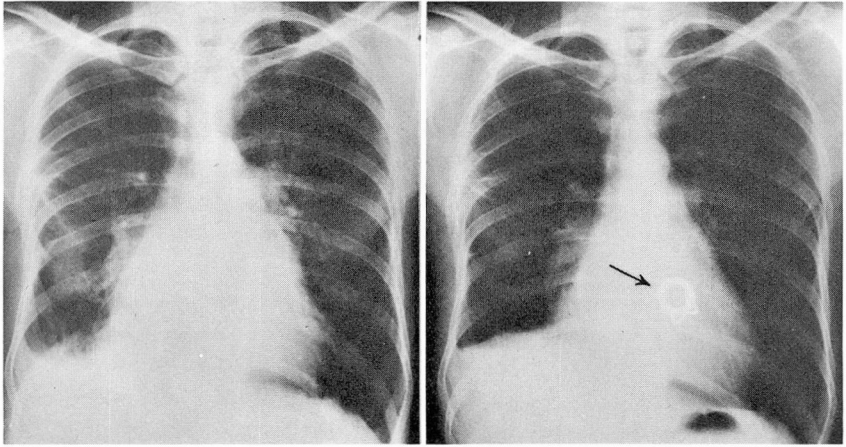


Fig. 2. Case 1. Roentgenograms demonstrate the preoperative and postoperative appearance with prosthetic mitral valve visible in right-hand illustration. The clinical response in the patient has been excellent, and parallels the obvious radiographic improvement.

or through the mitral annulus itself. It is of utmost importance that the prosthetic valve remain in the open or diastolic phase of its excursion throughout the operative procedure, otherwise, air or gas may be trapped in the left ventricle and in turn be diverted into the aortic stream.

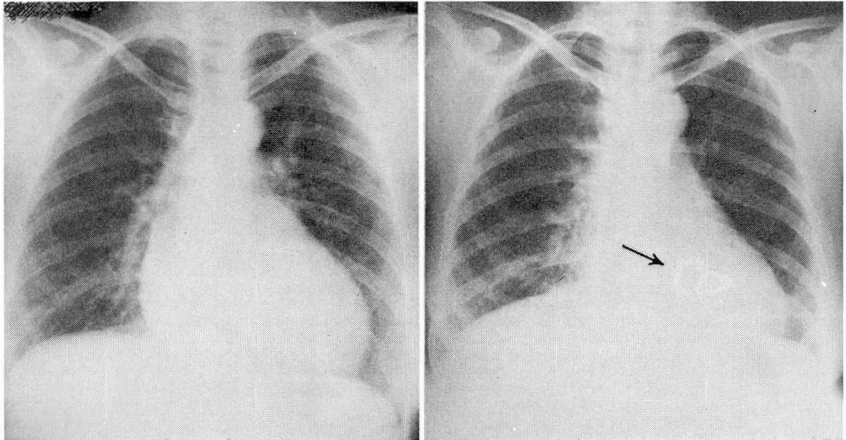


Fig. 3. Case 7. Comparison films demonstrate the prompt reduction in cardiac size within six weeks after insertion of the prosthetic mitral valve.

The postoperative care of these patients is the same as it is for a patient who has received open-heart surgery for acquired valvular disease. In addition, however, two factors are of particular importance: (1) protection against infection, and (2) the question of anticoagulant therapy. Postoperative infection may be disastrous



under any circumstances, but infection imposed upon a prosthetic valve is invariably a fatal complication. How prophylaxis can be best accomplished is an unsettled point. It is our practice to combine antibiotic therapy with restriction of all visitors and nonessential personnel; in addition, routine wound and nasal cultures are made at frequent intervals. If a culture is positive for *Staphylococcus aureus* (coagulase-positive), the patient receives additional antibiotic therapy, and isolation technics are utilized, even though his clinical course may be uneventful. At the present time we are not utilizing routine anticoagulant therapy in patients who are carrying a Starr-Edwards prosthetic valve. It should be mentioned, however, that Starr and others who are utilizing this prosthesis have recommended routine anticoagulant therapy at least in the early weeks or months after valve insertion.

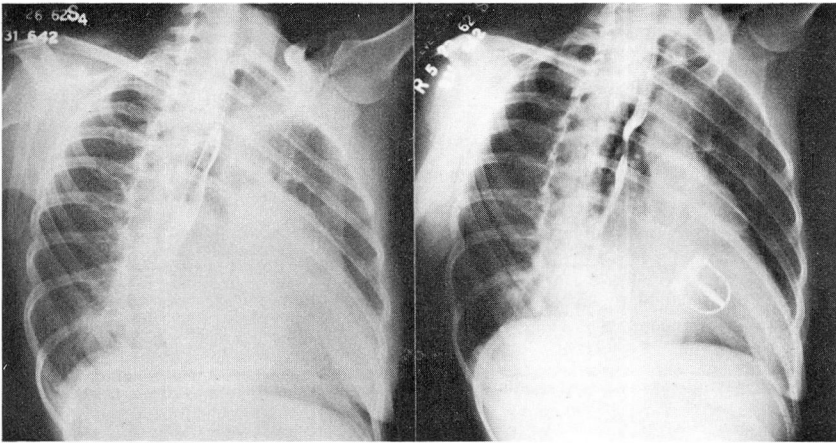


Fig. 4. Case 8. Comparison films demonstrate reduction in the size of the left atrium within two months after insertion of a prosthetic mitral valve. The oblique film demonstrates position of the prosthesis as it rests in the proximal left ventricle.

### Discussion

The surgical treatment for defects of the mitral valve remains, indeed, in a state of flux. Whereas a great deal has been accomplished, there is much to be learned, not only in the surgical treatment of mitral stenosis and mitral insufficiency, but also in the little-understood problems of recurrent valvular disease.

At the present time there appears to be no single operation that will be applicable to all forms of mitral stenosis. The exception to this would be the direct open-heart approach that utilizes extracorporeal circulation. From the standpoint of economy, both in time and cost to the patient, the addition of extracorporeal circulation today is still a burden. Perhaps the simplified forms of extracorporeal circulations as proposed by Zuhdi, Kimmel, Montroy, Carey, and Greer<sup>7</sup> will reduce this economic burden to a level more acceptable both to the patient and to the hospital itself.

Whether or not the incidence of subsequent restenosis of the mitral valve will be altered by an initial open-heart operation for mitral stenosis cannot be answered at this time. It seems likely, however, that in a certain percentage of patients, recurrent valvulitis will develop and that this subsequent complication will not be influenced by the technic of initial commissurotomy.

In many respects the surgical attack upon mitral insufficiency is more advanced than the surgical treatment of mitral stenosis. This is true for no other reason than the almost universal rejection of closed-heart technics for the incompetent mitral valve. At the present time the surgical attack upon mitral insufficiency utilizes some form of annuloplasty, selective valvuloplasty, and valve replacement. Whenever a large variety of operations are devised for a given lesion, it follows that none gives complete relief. This is certainly true in the technical repair of the incompetent mitral valve. Technics of mitral annuloplasty and mitral valvuloplasty are numerous. Many of these show considerable ingenuity and imagination. With experience, however, the surgeon and the clinician realize that initial success does not always yield the desired long-term result. On the basis of personal experience we have rejected virtually every method of annuloplasty and valvuloplasty that was employed during the preceding six or seven years. As stated before: the initial success with the Starr-Edwards prosthetic valve has been promising, and at the moment we consider it the treatment of choice for the patient who needs surgical relief of mitral valve incompetency. There is little doubt that this best present form of surgical treatment does not constitute the ultimate, but is only another phase in the continued search for better surgical treatment of mitral insufficiency.

### References

1. Bailey, C. P.; Glover, R. P., and O'Neill, T. J. E.: Surgery of mitral stenosis. *J. Thoracic Surg.* **19**: 16-45; discussion, 45-49, 1950.
2. Harken, D. E.; Ellis, L. B., and Norman, L. R.: Surgical treatment of mitral stenosis; II. Progress in developing controlled valvuloplastic technique. *J. Thoracic Surg.* **19**: 1-15; discussion, 45-49, 1950.
3. Sweet, R. H.: *In* Discussion of references 1 and 2. *J. Thoracic Surg.* **19**: 45-46, 1950.
4. Bailey, C. P., and Morse, D. P.: Mitral commissurotomy performed from right side. *J. Thoracic Surg.* **33**: 427-486, 1957.
5. Effler, D. B.; Groves, L. K.; Martinez, W. V., and Kolff, W. J.: Open-heart surgery for mitral insufficiency. *J. Thoracic Surg.* **36**: 665-676; discussion, 690-696, 1958.
6. Starr, A., and Edwards, M. L.: Mitral replacement: clinical experience with ball-valve prosthesis. *Ann. Surg.* **154**: 726-740, 1961.
7. Zuhdi, N.; Kimmell, G.; Montroy, J.; Carey, J., and Greer, A.: System for hypothermic perfusion. *J. Thoracic & Cardiovas. Surg.* **39**: 629-633, 1960.