

USE OF THE CRAIG NEEDLE FOR BIOPSY OF BONE

J. TED HARTMAN, M.D., AND JOHN B. SOMBECK, M.D.*

Department of Orthopedic Surgery

BIOPSY of a bone lesion often is necessary to arrive at an accurate pathologic diagnosis of orthopedic disease. In obtaining such a biopsy, the pertinent factors are the anatomic site of the bone and the density of the tissue forming the lesion. Some bones, such as the vertebral bodies, are technically difficult to approach surgically. When the lesion is deep, open biopsy can be a formidable procedure involving considerable morbidity and risk. The reports on methods of biopsy have been numerous. In 1948, aspiration of material was recommended,¹ but tissue obtained by this method is usually sparse and distorted, and renders interpretation difficult. Moreover, aspiration of a dense sclerotic bone lesion is virtually impossible. The Vim-Silverman needle is used on soft-tissue lesions² or on lytic bone lesions, but only a thin sliver of tissue is obtained and this may be compressed and distorted if firm elements are present to compress soft-tissue structures.

Currently we are using the Craig needle to obtain tissue from bone lesions, and have found the procedure simple and safe. In 1955, Dr. Frederick S. Craig³ of the New York Orthopedic Hospital described the needle he designed especially for a biopsy of bone. The instrument consists of a cylinder with a saw-tooth cutter end and an inside diameter of 3.5 mm.; a sharp S-hook stylet is used to remove the plug of tissue (*Fig. 1*). The needle is used under local anesthesia and with radiographic control. It is used with much less risk than that entailed with open biopsy to remove specimens from practically all bones except the upper eight thoracic vertebrae (on which no needle technic should be employed because of possible injury to the azygous vein, aorta, vena cava, or pleura). Below this level, the pillars of the diaphragm and the iliopsoas muscles form an envelope that isolates the vertebral body and the Craig needle from neighboring vital structures.

The tissue sections made from decalcified specimens obtained with the Craig needle generally show adequate cellular detail, particularly with Zenker's fixation, and usually provide a mass of tissue sufficient for accurate diagnosis. In one case of intervertebral sepsis, the organism was cultured from a portion of the specimen, and also was demonstrated in an appropriately stained tissue section.

The ability to obtain an absolute diagnosis in many of the patients with metastatic neoplasm is of more than just academic interest. In many instances it has allowed us to determine without delay the type of therapeutic program to initiate, such as radiotherapy, chemotherapy, or hormonal therapy.

We have used the Craig needle to biopsy bone lesions in 42 patients during the past year, either to establish diagnosis or for information on progress of neoplasms. Eighteen biopsies were of vertebral bodies, and 24 were of other bones. Three of

*Fellow in the Department of Orthopedic Surgery.




Fig. 1. Below, the serrated end of the Craig needle, and above, the S-shaped styilet for removal of the plug of tissue.

the biopsies were noncontributory in patients in whom we subsequently were able to diagnose neoplasm. The biopsy findings were as follows: *carcinoma metastatic to the bone*, 14 patients—eight had undifferentiated carcinoma, but with a previous history, present laboratory findings, or examination, which allowed a definite diagnosis (four of the specimens gave no clues as to the origin of the tumors). One of the metastatic lesions was a transitional-cell carcinoma—the primary neoplasm subsequently was isolated in the nasopharynx; one was a clear-cell neoplasm without a known site of origin. *Lymphocytic lymphoma of a vertebral body*, one patient. *Ewing's sarcoma*, two patients: one needle biopsy specimen was diagnostic, while the other was sufficiently suggestive to warrant open biopsy to obtain further tissue. *Synovial and osseous fragments*, two patients; later open biopsies revealed chondromyxofibroma in one patient, and an osteoarthritic bone cyst in the other. One patient was clinically and by roentgenographic evidence thought to have Paget's disease undergoing malignant change; the needle biopsy showed *Paget's disease without neoplasm*. The tissues from a femoral head that was disintegrating showed *necrotic bone fragments and fibrosis of marrow*; a culture of the tissue was negative. One specimen showed *hemosiderosis of bone marrow*; one was compatible with *bone infarct*; and two specimens showed *sclerotic bone without neoplasm*. Three biopsies were performed in order to follow the course of *osteogenic sarcoma* in femora, and previously treated by heat. Three specimens each showed *inflammatory tissue* on microscopic sections, and one of these returned the causative organism on culture. Eight biopsy specimens revealed *normal bone fragments* in patients in whom we suspected neoplasms.

Report of Two Representative Cases

Two cases are herewith summarized to show the clinical application of the Craig needle for bone biopsy.

Case 1. A 63-year-old diabetic dentist noted onset of lower thoracic back pain three months before examination by us. He had previously been treated with muscle relaxants, physical therapy, and roentgentherapy for a hemangioma of a vertebral body. On examination here, he moved slowly because of back pain, and there was tenderness to palpation and percussion over the interspace between the tenth and eleventh dorsal vertebrae. There was extreme limitation of flexion of the spine. Roentgenograms revealed evidence of a probable hemangioma of the first lumbar vertebra, but also a destructive process of the interspace between the ninth and tenth dorsal vertebra. A purified-protein-derivative skin test was negative. A Craig needle biopsy of the interspace between the ninth and tenth dorsal vertebrae was performed under local anesthesia. The characteristics of the tissue obtained (*Fig. 2*) were compatible with chronic osteomyelitis,

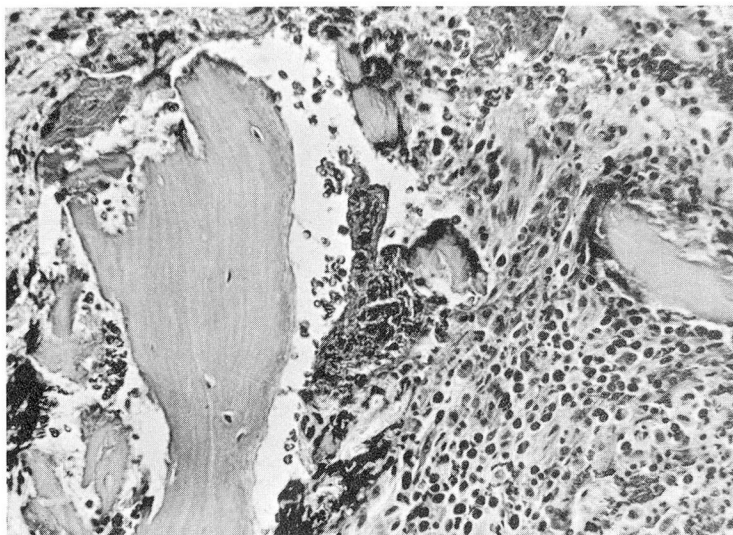


Fig. 2. Case 1. Photomicrograph of a biopsy specimen. Erosion of a bone trabeculum is seen at the upper left. To the right of this bone fragment are some small bone sequestra as well as an inflammatory infiltrate (polymorphonuclear). Hematoxylin-eosin stain; magnification X 250.

and on culture the tissue grew *Staphylococcus aureus* sensitive to erythromycin. He was treated with erythromycin for two weeks preoperatively, and then a spinal fusion from the eighth to the eleventh dorsal vertebrae was accomplished. His postoperative progress was excellent and he was free from back pain after bony fusion was obtained.

Case 2. A 69-year-old retired man was first examined here because of a five-month history of intermittent pain in the right hip. The pain had become progressively more severe, and signs of irritation of the sciatic nerve developed. On examination, motion of the right hip was extremely painful, and the right extensor hallucis longus was weak. Roentgenograms revealed evidence of a combined osteoblastic and osteolytic lesion of the right ilium suggestive of chondrosarcoma or carcinoma of the prostate. The acid phosphatase concentration was 17.7 units. A Craig needle biopsy of the ilium was performed under local anesthesia. The character-

istics of the tissue obtained (*Fig. 3*) were compatible with carcinoma of the prostate. Diethylstilbestrol therapy was instituted.

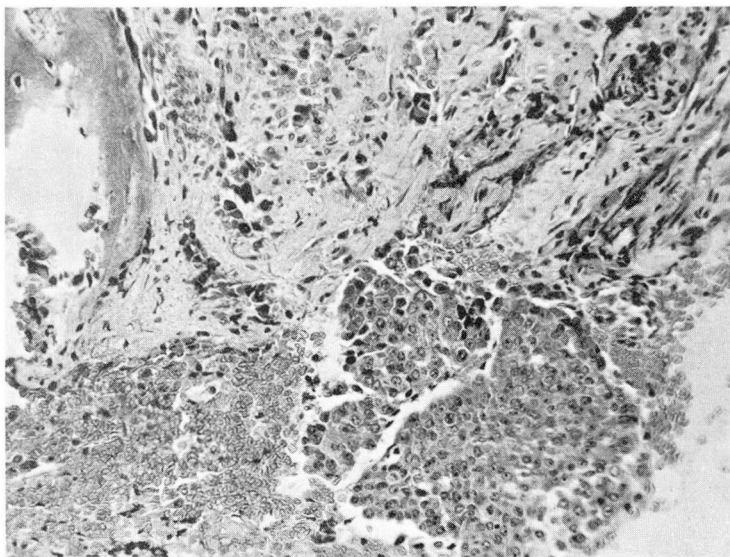


Fig. 3. Case 2. Photomicrograph of a biopsy specimen. In the lower right is a cluster of carcinoma cells (compatible with carcinoma of the prostate). Hematoxylin-eosin stain; magnification X 250.

Comment

On the basis of our experience with 42 patients, we are impressed with the effectiveness of the Craig needle for biopsy of bone, and believe it is a valuable addition to our diagnostic facilities. The instrument is easy to use, and generally removes a specimen of bone that is adequate for pathologic interpretation. There have been no complications to date, and the procedure has been tolerated well by all the patients.

References

1. Valls, J.; Ottolenghi, C. E., and Schajowicz, F.: Aspiration biopsy in diagnosis of lesions of vertebral bodies. *J.A.M.A.* 136: 376-382, 1948.
2. Brown, C. H.: Biopsy of liver with Vim-Silverman needles. *Mississippi Valley M. J.* 81: 198-200, 1959.
3. Craig, F. S.: Vertebral-body biopsy. *J. Bone & Joint Surg.* 38-A: 93-102, 1956.