

THE SIGNIFICANCE OF CHRONIC HOARSENESS IN ADULTS

JUSTIN M. WAUGH, M. D.

Pain, bodily discomfort, shortness of breath, an overactive heart, swelling of the extremities, chronic fatigue, some form of indigestion, or any symptom or group of symptoms that restrict the normal activities of human beings constitute the chief complaints of patients seeking relief from their medical advisors. Such symptoms always elicit a careful, painstaking examination; on the other hand, the symptom of chronic hoarseness is a very common complaint, but its significance is greatly underestimated by the average practicing physician.

How is the patient who presents himself for the relief of persistent and increasing hoarseness customarily managed? Inquiry is made concerning the general health, the duration of the symptom, and whether the patient has any cough or pain. The patient replies that nothing seems to be wrong except that his voice is not clear and that he has to make a constant effort to speak, whereas formerly he was never conscious of discomfort or of inconvenience. The doctor then takes a tongue spatula and looks into the patient's throat. What does he see? Nothing but a normal or slightly congested throat. He may look carefully at the tonsils, and sometimes he may see what he regards as a possible cause of hoarseness. But the infallible prescription is a gargle or a favorite medicine for colds. Thus the consultation terminates and the patient goes on—sometimes to certain, slow decline and death, just because the doctor was not aware of the many pathological conditions which might be the cause of the hoarseness and not sufficiently interested to direct his patient to someone who could give him assistance in making an accurate diagnosis.

Think of the position of the larynx, or voice-box, in relation to the tongue and the back of the pharynx. Recall what happens if one gets a few drops of fluid into the larynx, and then ask—why a gargle? In using a gargle, the muscular action of the throat combined with closure of the epiglottis is directed entirely to holding the solution above the level of the larynx, and it practically always succeeds in doing this. But even if the fluid reached the uppermost part of the larynx, it would still not reach the vocal apparatus, which is some distance below the upper margin of the larynx, and if the pathological condition were at a level just below the cords, how utterly futile would be the use of a gargle. The thyroid, cricoid, and arytenoid cartilages constitute the so-called voice-box which contains those muscular, cartilaginous, nervous, and circulatory elements that are necessary to produce tone and speech and which have a very vital relationship to respiration. Within this small space may develop a large variety of pathological conditions, and these may either be limited to this territory alone or become second-

THE SIGNIFICANCE OF CHRONIC HOARSENESS IN ADULTS

ary to extensive pathology in contiguous structures. It would be difficult to find anywhere in the body a region of equal dimensions in which such a variety of pathological conditions may exist. Moreover, when the dimensions of the human larynx and its interior structure are considered, it is quite understandable that a very slight pathological change can easily derange this function of voice production. Thus, chronic congestion of the cords or of the mucous membranes will produce hoarseness; ulceration will produce hoarseness; granulomata, hoarseness; new growths, hoarseness; impairment of the nerve supply to the vocal cords, hoarseness.

The first symptom of which the patient is conscious in any of the above conditions is hoarseness, though how soon the hoarseness will develop after the onset of the disturbance will depend to some extent upon the location of the pathological area.

PARALYSIS OF THE VOCAL CORDS

Paralysis of one or both vocal cords may be due to disease of the central nervous system, the most common cause being syphilis. The paralysis is usually bilateral. The abductor power is lost early but the adductor function remains unaffected for a long period of time. The voice is retained for many months but dyspnea is progressive.

Hemorrhage, new growths, or degenerative disease, occurring in the nucelus ambiguus, in the floor of the fourth ventricle, or at the jugular foramen, may give rise to the jugular syndrome which causes peripheral manifestations in the form of paralysis of the soft palate and of the muscles of the pharynx and larynx on the corresponding side. If the lesion is peripheral in origin, it is usually unilateral (Fig. 1, A and B) and is due to trauma or to pathology in the chest which causes pressure on the recurrent laryngeal nerve. Many pathological changes may occur within the neck and chest cavity which will cause pressure on the recurrent nerves with consequent impairment of the function of one vocal cord. Thus tuberculosis, aneurysm of the aorta, new growths, and changes in the mediastinal glands may be the cause of the paralysis. Prominent among the lesions that produce early paralysis of one vocal cord is cancer of the esophagus. Paralysis may also occur as the result of pressure from an esophageal diverticulum when it is filled. There may be no pain or difficulty in swallowing—merely a hoarseness due to the paralysis of the vocal cord from pressure upon the recurrent nerve on the same side.

Recently we have observed two cases of unilateral vocal cord paralysis caused by pressure or stretching. In the one case there was unusual stretching of the seventh, eighth, ninth, tenth, and eleventh nerves due to a bilateral acoustic tumor. Following operation, the function of these nerves has almost completely recovered, except for the seventh.

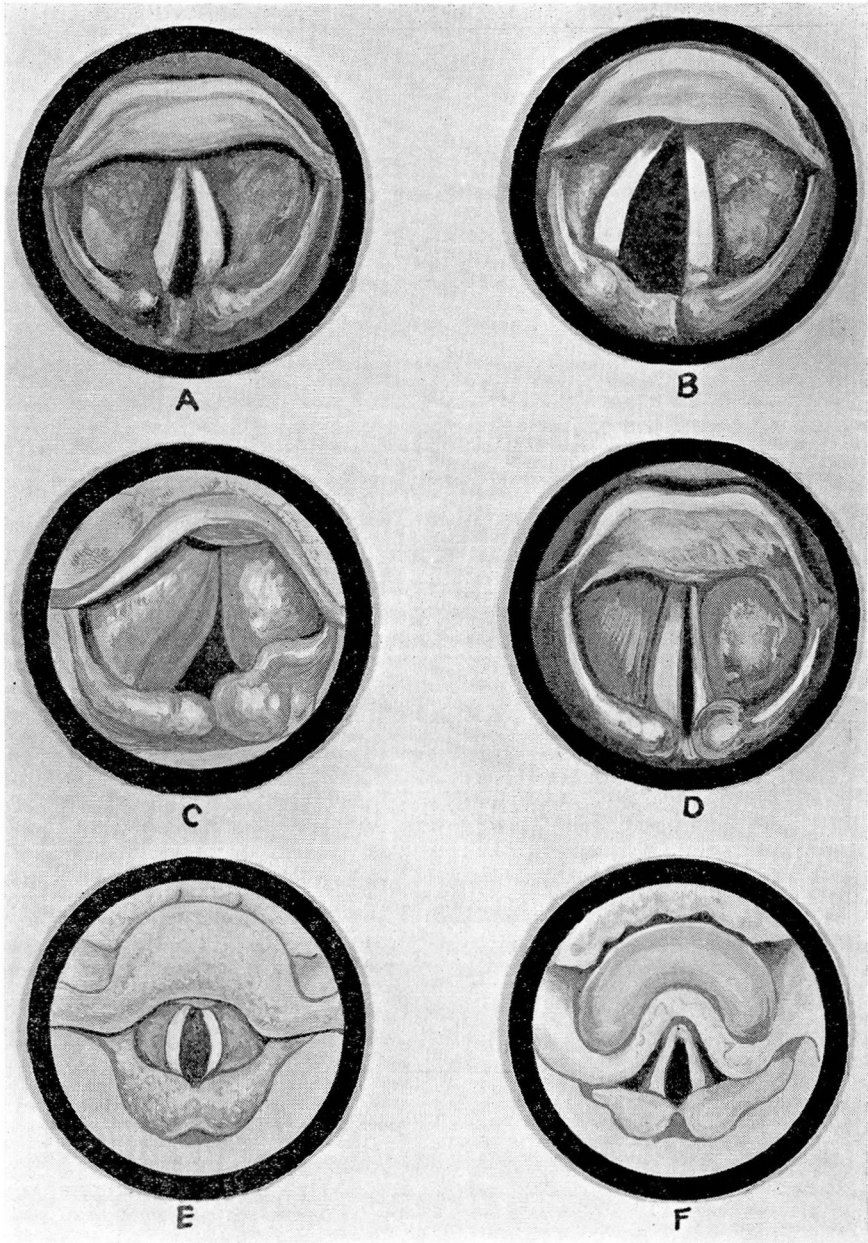


FIGURE 1: A. Unilateral paralysis of left vocal cord. Left cord fixed near midline. B. Unilateral paralysis of left vocal cord. Left cord fixed in midline; right cord in full abduction. C. Trauma to larynx with hemorrhage into arytenoids and both false cords. D. Unilateral hemorrhage with extravasation of blood into larynx. E. Tuberculosis of larynx. F. Tuberculosis of larynx.

THE SIGNIFICANCE OF CHRONIC HOARSENESS IN ADULTS

In the second case the pressure was caused by a paragangliomatous tumor of the cervical sympathetic lying above the bifurcation of the carotid artery. The paralysis was not relieved following operation although the tenth nerve was not severed.

INJURIES TO THE LARYNX

While injuries to the larynx (Fig. 1, C and D) are relatively rare, due to the mobility of the larynx together with the protection offered by the lower mandible, the treatment of fractures, wounds, and burns requires skill, presence of mind, and willingness to act on the part of the surgeon.

In cases of some sudden injury to the larynx a marked *concussion* of the larynx may ensue which causes dyspnea, syncope, and death. Artificial respiration and immediate tracheotomy are indicated.

Fractures usually occur in men and they may be so slight as to go unrecognized. Gunshot wounds in reality are compound fractures, and structures other than the cartilages may be involved such as the thyroid, the vocal cords, the vagus nerve or its branches, the great vessels of the neck, the hyoid bone, and the mandible. There follows, therefore, great danger from cellulitis, emphysema, and mediastinitis. Pneumonia may follow. Sometimes secondary hemorrhage and subsequent stenosis of the larynx or trachea result. Hoarseness begins at once and is quite persistent.

Incised wounds of the larynx are usually the result of murder or attempted suicide. An increasing number of these cases are now seen due to automobile accidents. Various degrees of hoarseness accompany these wounds and may persist indefinitely.

Burns may result from fire, acids, or from injudicious or overenthusiastic use of radium or x-ray. These always heal slowly and the stenosis which follows may reach any degree, even to extensive destruction of the larynx. The temporary or chronic edema following burns calls for great wisdom in treatment. The slowly healing ulcerated surface should never be swabbed; tracheotomy may be necessary at any time. Perichondritis and necrosis may follow weeks or even months after severe burns. This is particularly true of burns due to x-ray or radium. Any degree of chronic hoarseness may result from burns to the larynx.

TUBERCULOSIS OF THE LARYNX

Tuberculosis takes on an added virulence when it attacks structures near the exterior of the body. Involvement of the larynx materially diminishes the outlook for the patient's recovery. The pulmonary process may not have been sufficiently active to cause the patient any concern and the invasion of the larynx may be very subtle. Since it is quite impossible to detect a so-called "pretuberculous stage" of laryngeal tuberculosis, an early diagnosis of the cause of hoarseness is of

vital importance. Tuberculosis is usually not primary in the larynx, and many clinicians think that it is always a secondary or complicating manifestation. If, however, the laryngeal lesion is recognized and no lesion has been demonstrated in the lungs, it means that the pulmonary tissues are seriously threatened and the pulmonary disease will manifest itself soon. In such a case, a roentgen examination of the chest will almost always demonstrate lung involvement.

The usual site of primary invasion of the larynx by tuberculosis is in the arytenoid and interarytenoid areas. The mucosa is involved but the epithelial cells remain intact. The original deposit is in the form of multiple tubercles which later coalesce and break down, leading to ulceration. The invasion of the walls of the small veins causes a damming-back of the circulation and gives the appearance of edema of the tissues. In the early stages (Fig. 1, E), this tumefaction occurs in a localized area, but later it appears to be asymmetrical edema of the arytenoid area. Involvement of the epiglottis appears later. The area affected presents a pale, dull gray appearance with a slightly yellowish tinge. The epithelial surface is unbroken and at times the individual tubercles may be seen plainly beneath it.

Should there be involvement of the epiglottis, the first change from the normal is a unilateral thickening over or near the free edge, although sometimes it may occur near the base. It is distinctly more red, not well defined, and at this stage not edematous. Later, edema occurs over the entire free edge and this gives the so-called turban-like appearance of the epiglottis (Fig. 1, F).

Among the early symptoms may be noted recurrent aphonia. Dysphonia is more apt to occur if there is much thickening in the arytenoid areas. Cough is a much more prominent symptom when ulceration occurs in the posterior commissure than when the disease is in other parts of the larynx. Pain, a later symptom, means ulceration and is experienced either at the site of the area involved or is referred to the ear. Ulceration of the epiglottis or over the arytenoid area makes swallowing very painful; in fact, it is at times almost unbearable and requires injection of the superior laryngeal nerve or its section to give relief. Otherwise the patient becomes rapidly dehydrated, and proper nutrition becomes impossible. When there is extensive edema of the larynx, we have found tracheotomy a very satisfactory measure as this not only relieves dyspnea but puts the larynx at absolute rest. The management of these patients in a sanatorium is usually much more satisfactory than in a home. In such institutions, the larynx is usually under constant observation and treatment is instituted if necessary. Unskillful attempts at direct medication of the larynx are strictly contraindicated.

In any case of tuberculosis of the chest, chronic laryngitis may be

THE SIGNIFICANCE OF CHRONIC HOARSENESS IN ADULTS

found which is not necessarily due to tuberculous involvement of the larynx. The important observation is whether or not the lesion in the larynx is symmetrical, for the lesion of chronic laryngitis is always symmetrical, whereas a unilateral or asymmetrical involvement, especially in the posterior part of the larynx, is very suggestive of tuberculosis. When this swelling occurs in the interarytenoid area, this is also an important factor in making the diagnosis. It is sometimes necessary to examine the patient in what is known as the Killian position, as this brings into view the posterior surface of the interarytenoid area, and one may see very early ulceration or granulation on the posterior surface of a mass which, if viewed from the anterior aspect, presents a smooth, nonulcerated surface. The color of the mucous membranes is not of aid in the differential diagnosis between early tuberculosis and chronic laryngitis. It is important to remember that although the earliest manifestation of tuberculous laryngitis occurs in the vocal cords, especially in their posterior third, nevertheless the cord retains its motility and there is no infiltration and fixation such as is seen in the presence of malignancy. Figure 2,A shows extensive tuberculosis of the throat and larynx.

SYPHILIS OF THE LARYNX

All stages of syphilis have been demonstrated in the larynx. At times it may be difficult to make a diagnosis of syphilis of the larynx, but this condition has certain rather characteristic appearances. The involvement is usually extensive and it is of the infiltrating type. It has been described accurately by Bosworth as causing a "peculiar, dusky, sombre hue of the mucous membrane which has a dark red, or somewhat purplish tint, in contrast to the bright red, scarlet color of an idiopathic inflammation. It may be intensified in certain areas, thus giving the tissues a mottled appearance."

Tertiary lesions in the larynx usually appear in the form of a gummatous tumor. However, due to the activity of the larynx, these gummata break down and ulcerate very early. The ulceration is deep and crater-like, with sharp-cut edges, in which respect it differs sharply from tuberculous and malignant ulcerations. Though improvement in the patient's general condition takes place during the course of treatment, the ulceration tends to recur. It may be localized in any part of the organ and the cicatrization that follows ulceration may produce great distortion of the larynx with persistent hoarseness.

BLASTOMYCOSIS OF THE LARYNX

Among other diseases that may cause gradual and chronic hoarseness is blastomycosis of the larynx which is usually associated with lesions in the pharynx, trachea, and lungs. The histological picture is sug-

gestive of tuberculosis as there is evidence of inflammatory disease and giant cell proliferation of epithelium with minute abscesses.

The characteristic feature of blastomycosis is the presence of spherical, encapsulated, parasitic cells, the presence of which can best be demonstrated in unstained specimens of the secretion. A "cold in the throat" is usually the first symptom and this is followed by persistent and increasing hoarseness; gradual stenosis, cough, and dysphagia may develop.

In the early stage of the disease, flat lesions are seen on the larynx. These nodules are minute, superficial abscesses and there is an opaline frog-spawn secretion. The appearance of the tiny nodules is characteristic of the disease.

Diagnosis is made only by biopsy and bacteriological examination. The intensely red and inflammatory appearance of the larynx as seen in the mirror is not typical of tuberculosis and is particularly not suggestive of carcinoma. If this condition is not recognized and treated, the outcome is fatal. Potassium iodide is the treatment of choice.

BENIGN GROWTHS OF THE LARYNX

Almost any form of benign growth (Fig. 2, C and D) may make its appearance in the larynx, but those most commonly seen belong to the following groups: (1) The papillomata (Fig. 2, E and F); (2) the fibromata; (3) the cystomata, and (4) the angiomas. These growths usually involve the margins of the cords, and though small, may produce a marked impairment of the voice without causing other symptoms. They may be present for years without showing any tendency to malignant degeneration. Usually they can be removed successfully without injury to the vocal structures and the hoarseness and voice disturbances may be completely relieved.

MALIGNANT GROWTH OF THE LARYNX

Cancer of the larynx (Fig. 3, A, B, C, D) begins insidiously and in its early stages progresses slowly. It may be a carcinoma of the basal-cell or squamous-cell type. Its usual site is on one cord at about the junction of the anterior and middle thirds. It tends to progress in the direction of the long axis of the cord, and until well advanced does not involve the other structures within the larynx. Because of the sparsity of the lymphatics, it does not readily become extrinsic, that is, it does not spread outside the laryngeal box.

The usual site of the initial lesion is on the free edge of one vocal cord. This free edge has no true mucous membrane covering, there being only a firm thin layer of epithelium and no glands. From this area the lymph flow is to two nodes, one on each side, and from these nodes there is no demonstrable efferent lymph flow. This fact misleads

THE SIGNIFICANCE OF CHRONIC HOARSENESS IN ADULTS

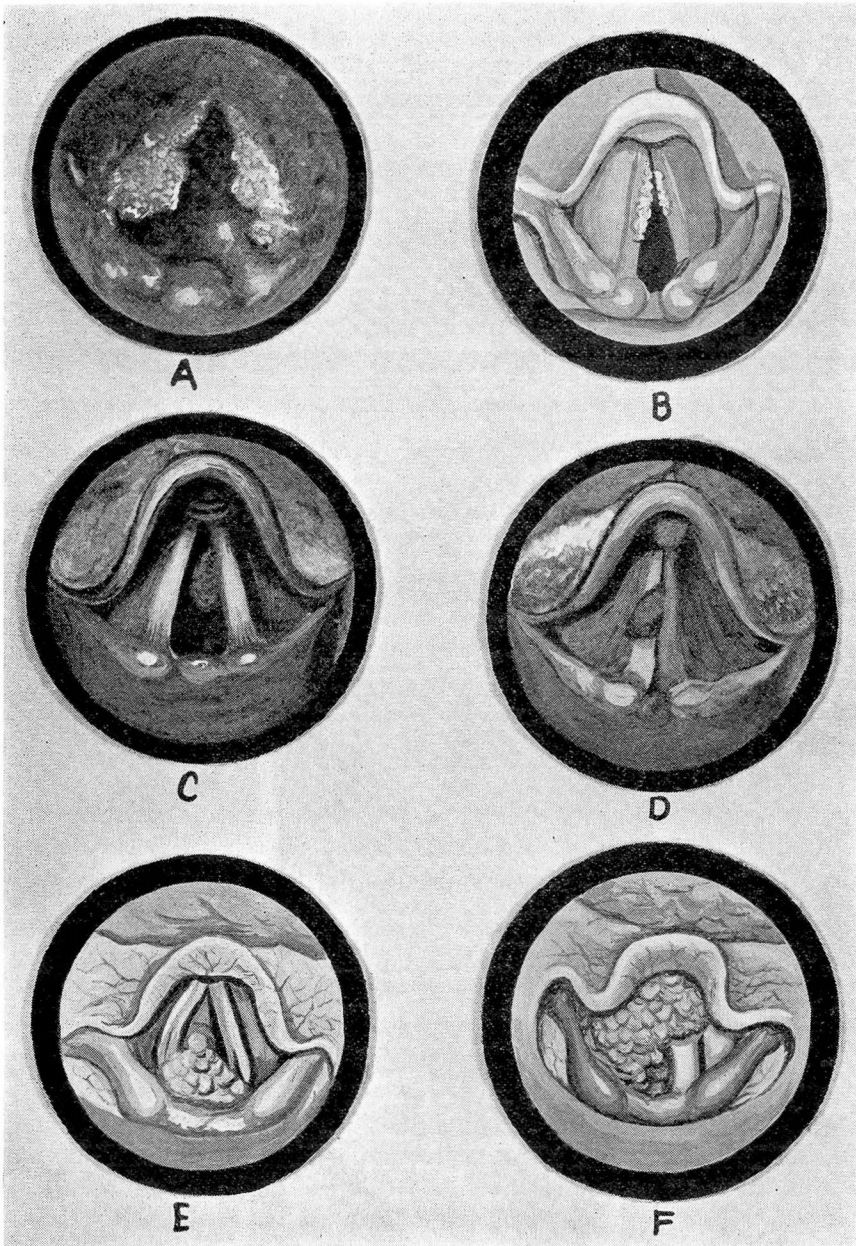


FIGURE 2: A. Extensive tuberculosis of throat and larynx. B. Keratosis of larynx. C. Tumor of larynx. Appearance of growth on respiration. D. Tumor of larynx. Appearance of growth on phonation. E. Papilloma of larynx. F. Papilloma of larynx.

the doctor because the lesion does not progress rapidly and precious time may be lost.

If, however, the lesion begins in one cord in the posterior third of the larynx, it is very significant as the growth is probably subglottic at an early stage. This type of carcinoma has the appearance of a benign growth and often the portion recovered at biopsy fails to show its carcinomatous character.

There is also a group of borderline cases which begin as keratoses or leukoplakias (Fig. 2, B). For many months or even years they remain nonmalignant but, at times, their character may change as the patient grows older. These patients should be seen periodically in order that any malignant change may be recognized immediately.

Cancer rarely metastasizes from the larynx to other parts of the body and is also rarely a metastatic growth. It is usually primary within the larynx, though in extremely rare instances cases have been observed in which it appeared as a metastatic lesion from a primary cancer in some other part of the body.

Cancer of the larynx may be due to direct extension from a cancer in an adjacent structure, such as the esophagus or the thyroid gland. In such a case it is of the extrinsic type. The extrinsic type of cancer progresses much more rapidly, the lymphatic structures are involved early, and glandular enlargement is soon evident. This type is usually of the squamous-cell type and is much more rapidly fatal than the basal-cell intrinsic cancer.

Usually in cases of cancer of the larynx the only symptom complained of for weeks or months is hoarseness. Pain, cough, dyspnea, the expectoration of foul and blood-stained sputum, etc., are later symptoms.

Why then, in view of the above facts, do we have so many fatalities from cancer of the larynx? There is but one answer: The patient who is suffering from hoarseness goes to his family doctor and the doctor belittles the gravity of the symptom. He temporizes with a condition which, if diagnosed early and treated intelligently, offers every chance for cure. If one waits for the textbook series of classical symptoms of cancer of the larynx to appear, namely, dyspnea, hemorrhage, salivation, pain in the ear, glandular involvement, and cachexia, there is only one outcome of the disease—death. And this is true no matter what procedure is adopted or how extensive a surgical operation is performed at this stage.

One should never be misled by the patient's general condition, especially in the first and second stages of laryngeal cancer. He may retain his weight and vitality; he may feel well, and may be annoyed only by slight, persistent hoarseness. Neither should one be misled by the

THE SIGNIFICANCE OF CHRONIC HOARSENESS IN ADULTS

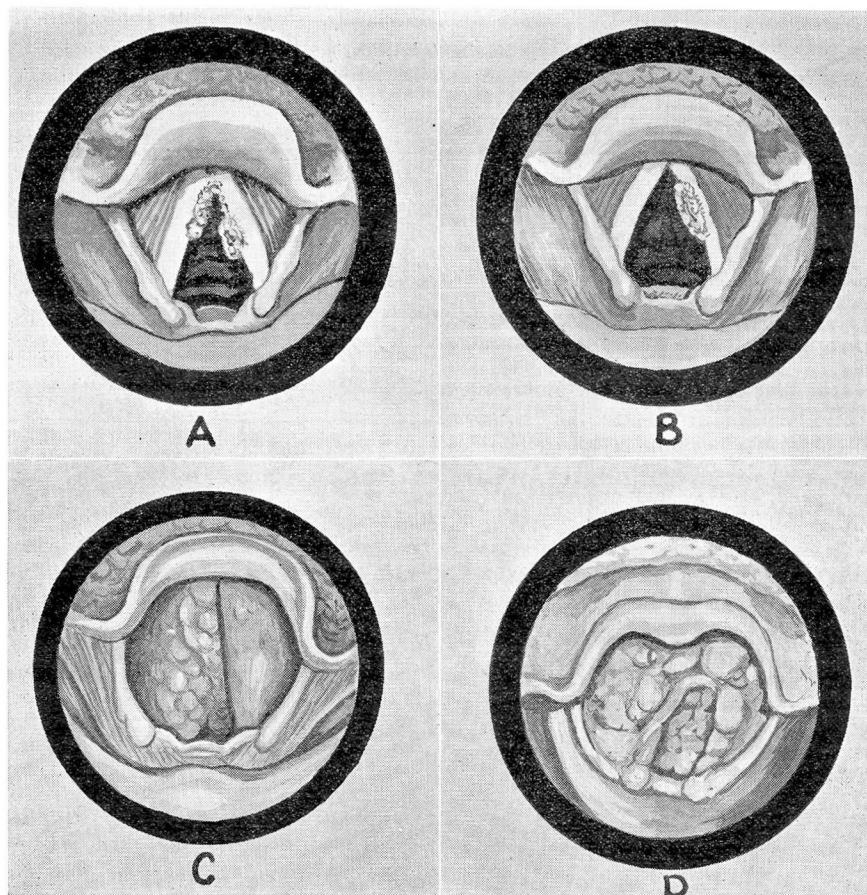


FIGURE 3: A. Carcinoma of larynx. B. Carcinoma of larynx. C. Advanced carcinoma of larynx. D. Advanced carcinoma of larynx.

fact that in the early stages of the disease the use of iodides sometimes mitigates the severity of the symptoms.

In the great majority of cases of cancer of the larynx, a definite diagnosis is not made until many months have elapsed. To make that diagnosis requires painstaking effort and repeated observation. Complete cocaineization of the throat is often necessary to secure a view of the larynx in a sensitive or refractory patient.

Biopsy is frequently of great importance in establishing the diagnosis, but this should be done only with the distinct understanding with the patient that if a pathological diagnosis of cancer is made, operation is to follow immediately.

As long as the lesion is unilateral and intrinsic, a skillfully performed laryngofissure will probably result in cure. But, to secure the highest

percentage of favorable results the technique must follow that used by Dr. Chevalier Jackson. The dissection beneath the cartilage without entering the cavity of the larynx until the last step of the operation is all-important in preventing transplantation of cancer cells. To do this, the opening of the cartilaginous box must be made from without inward and the laryngeal scissors must be dispensed with. This is the key to the whole operation, and yet today it is often ignored. If the lesion is unilateral but subglottic or if it has extended anteriorly around the commissure to the opposite side, laryngectomy should be performed.

Only two groups of men are qualified to do laryngectomy. In the one group is the general surgeon who is willing to interest himself in every minute and delicate feature of this operation and who will work throughout in close coöperation with a competent laryngologist. The other group is comprised of the few laryngologists who have had good training in neck surgery before they became laryngologists. Any general surgeon can rip out a larynx but his percentage of unfavorable results will be high. Most laryngologists are surgical scratchers when they undertake to remove a larynx and the time and trauma involved go far toward prejudicing recovery of the patient. In every case conscientious after-care by both the surgical and nursing staffs is all-important.

In conclusion, let me emphasize again the following points: Keep in mind the variety of pathological conditions that may affect the larynx and remember the importance of ferreting out the cause of chronic hoarseness in every adult, especially if he is over forty years of age. Have your opinion checked closely whenever you are in doubt. Bear in mind the dictum of Sir St. Clair Thompson that if in a case of intrinsic cancer of the larynx the patient's general health is good and the diagnosis is made early, the prognosis for lasting cure is better than in the case of cancer in any other part of the body.