

EXPERIENCE WITH THE STARR-EDWARDS AORTIC VALVE: REPORT OF SIXTY CASES

DONALD B. EFFLER, M.D., LAURENCE K. GROVES, M.D.,
and RENE FAVALORO, M.D.*

Department of Thoracic and Cardiovascular Surgery

THE Starr-Edwards aortic valve† has been used at the Cleveland Clinic Hospital for the surgical treatment of acquired aortic valvular disease, for one and one-half years. The decision to utilize the Starr-Edwards aortic valve was influenced by two factors: (1) dissatisfaction with the late results of valvuloplasty, and (2) lack of confidence in the cloth type of prosthesis. This report reviews our experiences with the first 60 patients in each of whom the Starr-Edwards aortic valve was used for aortic valve replacement.

In 1956, we undertook the surgical treatment of acquired aortic valvular disease, utilizing the direct approach with extracorporeal circulation.¹ Efforts were made to relieve calcific aortic stenosis by a combination of decortication and commissurotomy. Insufficiency of the aortic valve, related to dilatation, and prolapse of the redundant cusps were treated by various plastic procedures designed to reduce the caliber of the aortic root, and to reestablish cusp integrity—on occasion the aortic valve was rendered bicuspid. All of the procedures were undertaken with enthusiasm, and the initial results frequently were gratifying. However, evaluations of the long-term results have been uniformly disappointing: in our experience, calcified aortic valves, treated by decortication, invariably became recalcified and restenosed. Regurgitant valves treated by plication, plastic support, or bicuspidation, were not wholly satisfactory: the little-understood process that leads to cusp attenuation was not arrested, and insufficiency recurred. Our experience led us to the conclusion that plastic procedures designed for the relief of stenosis or of insufficiency were not of long-term value. For this reason all plastic procedures, save simple commissurotomy for the fibrous stenotic valve (a rare entity), are no longer used at the Cleveland Clinic Hospital.

Prostheses that simulate aortic valve anatomy have received considerable experimental and clinical application. Simulated aortic valves or individual cusps made from various cloth materials bear remarkable resemblance to the normal human counterpart. Indeed, excellent results have been reported after experimental and clinical application; however, problems related to accurate fitting, tendency toward clot formation, and subsequent loss of mobility are by no means resolved. Observations made by Kolff and his associates,^{2, 3} after an extensive program to develop cloth aortic valve prostheses, prompted caution toward their clinical

*Fellow in the Department of Thoracic and Cardiovascular Surgery.

†Manufactured by Edwards Laboratories, 624 Dyer Road, Santa Ana, California.

application. We were reluctant to utilize any type of cloth prosthesis until there was reasonable assurance of the prevention of clotting and subsequent loss of mobility.

In our early clinical ventures we also were impressed with the anatomic derangement that invariably attends the process of aortic stenosis, or aortic insufficiency. The fact that a prefabricated valve could closely simulate the normal human valve did not take into account the topographic distortion that accompanies these diseased processes, rendering the site unsuitable for a prosthetic valve of normal construction. The foregoing principle is analogous to that of the severe clubfoot, which, by diligent treatment may be made functional to the patient, yet the structural alteration may require special footwear not designed for the normal extremity. The design of the ball-valve prosthesis is not intended to reproduce human anatomy; it seeks only to provide effective relief of the physiologic disturbances related to stenosis and/or insufficiency. The Starr-Edwards ball-valve prosthesis had already provided gratifying results in the treatment of severe mitral valve disease.⁴⁻⁶ Since the ball-valve prosthesis can be made in a basic range of valve sizes, virtually any abnormality that occurs in the gamut of aortic valvular disease can be fitted with a prosthesis.

Clinical Experience

Our experience with aortic valve replacement is limited, and the duration of follow-up of patients is brief; nevertheless, these observations may have value as this field of cardiac surgery continues on in its developmental phase.

Age of patients. Of the 60 patients, 44 (73 percent) were between 40 and 60 years of age at the time of operation. The youngest patient was 23 years old, and the oldest 63 years of age. An analysis by decades is shown in *Figure 1*.

Diagnosis. Evaluation of each patient included a left-heart catheterization study and selective coronary arteriography.* The dynamic alterations of the diseased valves were assessed as accurately as possible, and when practicable were reevaluated at the time of operation. *Table 1* lists the essential findings from laboratory studies.

In the diagnostic evaluation of the individual patients an effort has been made to categorize the valves with significant calcification. When calcification is present, there frequently is associated reduction in the caliber of the aortic root and the left ventricular outflow tract itself. This restricts the size of prosthetic valve replacement and the surgeon's ability to relieve the existing gradient. In contrast, the noncalcified valve associated with free aortic regurgitation, is associated with dilatation of the ventricular outflow tract and of the aortic root. In this latter situation the surgical mission is more easily accomplished; hence, the presence or absence of extensive calcification of the diseased aortic valve is a significant diag-

*All physiologic studies were performed under the direction of our colleagues, F. Mason Sones, Jr., M.D., and Earl K. Shirey, M.D., in the Cardiac Catheterization Laboratory.

STARR-EDWARDS AORTIC VALVE

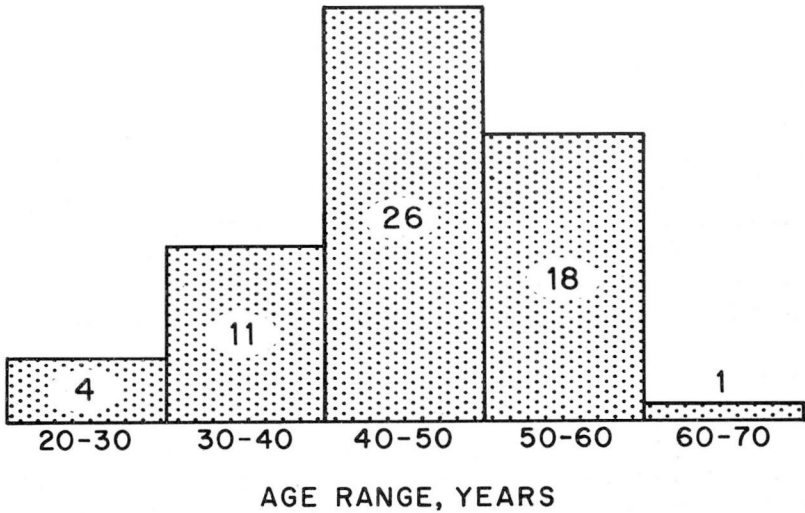


Fig. 1. Bar graph showing age range (by decades) of 60 patients who underwent aortic valve replacement.

Table 1.—Preoperative left-heart catheterization findings in 60 patients

Diagnosis	Number of patients
Severe aortic stenosis and mild aortic insufficiency	17
Severe aortic insufficiency and mild aortic stenosis	15
Aortic insufficiency only	16
Aortic stenosis only	6
Severe aortic stenosis and severe aortic insufficiency	6
Total	60

nostic point as far as the surgical team is concerned. In this series, calcification was reported as severe in 35 patients, and as mild in 3 patients; in 22 patients no evidence of calcification could be demonstrated on the diseased aortic valves.

Etiology. Rheumatic heart disease was diagnosed in the majority of patients who constitute this series, though there is some doubt that every diagnosis was necessarily accurate. A significant number of patients with free aortic insufficiency demonstrated none of the typical stigmata attributed to rheumatic heart disease, and this clinical category was selected for want of a better one.

Table 2 lists the presumed etiologic diagnoses of this series. Two diagnoses of

Table 2.—Presumed etiologic diagnoses of 60 patients

Diagnosis	Number of patients
Rheumatic heart disease	50
Class: II	5
III	30
IV	15
Rheumatic heart disease, aortic stenosis heart disease	2
Doubtful rheumatic heart disease	1
Congenital heart disease	2
Cardiovascular syphilis	2
Cystic medial necrosis	2
Marfan's syndrome	1
Total	60

congenital heart disease were made because the calcific aortic stenosis was associated with a typical bicuspid valve. In five of our patients, aortic insufficiency was in reality secondary to primary disease of the proximal aorta: syphilitic aortitis, cystic medial necrosis, and Marfan's syndrome accounted for this group.

Coronary atherosclerosis. It has long been recognized that angina pectoris may be a feature in the clinical picture of severe aortic stenosis. Early in our experience we followed the premise that relief of the aortic stenosis would in all probability relieve associated coronary insufficiency. Our results do not always support this hypothesis. Selective coronary arteriography establishes the frequent relationship between calcific aortic stenosis and coronary atherosclerosis (Table 3). Each disease

Table 3.—Preoperative coronary arteriographic data of 60 patients

Coronary atherosclerosis	Number of patients
None	44
Mild	8
Severe	2
Not known	6
Total	60

represents an individual entity, and it does not follow that relief of one invariably produces improvement in the other.

Patients with demonstrable coronary atherosclerosis are accepted for surgical treatment of severe calcific aortic stenosis. This is done with the knowledge that the risk of operation is great and that the patient's ultimate fate will most likely be determined by his preexisting coronary disease. It would seem that the patient

who will have significant myocardial infarction after surgical relief of aortic stenosis would have a better chance to survive an occlusion. At present this concept is presumptive, and requires testing by additional time and clinical experience. It is of interest that the patients listed in *Table 4* include a 30-year-old man who, after discharge from the hospital, died unexpectedly from demonstrable occlusion of the right coronary artery and acute subintimal hemorrhage (these findings were established at postmortem examination). Another patient, a 58-year-old man

Table 4.—*Preoperative status of cardiac function in 60 patients*

Congestive left-heart failure secondary to aortic valvular disease	Number of patients
None	32
Mild	23
Severe	5
Total	60

who was considered to have the most advanced coronary atherosclerosis of all our patients, survived not only the initial operation remarkably well, but survived a second operative procedure for leakage around the prosthesis, and he continues to do well six months after the last procedure.

Cardiac function. No patient has been accepted for prosthetic valve replacement who has not demonstrated significant cardiac disability. No effort is made to assess the subjective findings in this group of 60 patients. *Table 4* is a simple listing based on the number of patients who demonstrated left-heart failure secondary to aortic valvular disease.

Left ventricular failure was absent in 32 of the patients. Selection of these patients was based upon the subjective manifestations of their disease and upon the objective findings that were assessed by standard clinical study and left-heart catheterization. In this group, evidence from catheterization study, radiographic findings of left ventricular hypertrophy or dilatation, and electrocardiographic pattern were compatible with a history of progressive disability and some degree of myocardial failure. In these patients, operation was recommended to forestall the inevitable trend toward myocardial deterioration.

Twenty-three patients had demonstrable congestive heart failure that subsequently responded to stringent medical therapy. Perhaps the most significant observation was noted in the five patients who were taken to the operating room in intractable failure. One of these (case 36), a 45-year-old physician, lived in an oxygen tent for seven days before operation; recovery was dramatic as soon as the mechanical factor of calcific aortic stenosis was relieved by valve replacement. Although surgical treatment of the patient who remains in a functional class IV

status is always undertaken with misgiving, the ultimate recovery of all patients in this category has encouraged us to extend the latitude of this surgical treatment to patients previously thought beyond salvage.

Prior operation. Nine patients in this series each had already undergone an operation for relief of aortic valvular disease: seven had been operated upon for relief of calcific aortic stenosis, and two for plastic repair of grossly insufficient valves. Five of the operations were performed by us, two at other surgical centers.

Although a previous operation imposes an additional burden on the surgeon, inasmuch as landmarks may be distorted by postoperative adhesions and non-specific inflammatory reactions, we believe that this does not constitute a contraindication to surgery. Reexamination of the valves in the nine patients added testimony to the conviction that valvuloplasty for the treatment of aortic stenosis or free aortic regurgitation is an obsolete procedure of palliative value only.

Surgical mortality. Of the 60 patients reported herein, 16 have died. Analysis of the mortality figures indicates that there were nine hospital deaths (15 percent) and seven late deaths, or a total mortality of 26.6 percent.

Perhaps as important as the overall mortality figures is the improved trend in mortality as demonstrated in *Figure 2*. Whereas the overall mortality rate in our first 20 operations approached 50 percent, there was only 1 death in the last 20 operations, bringing the current mortality figure to less than 5 percent. Improve-

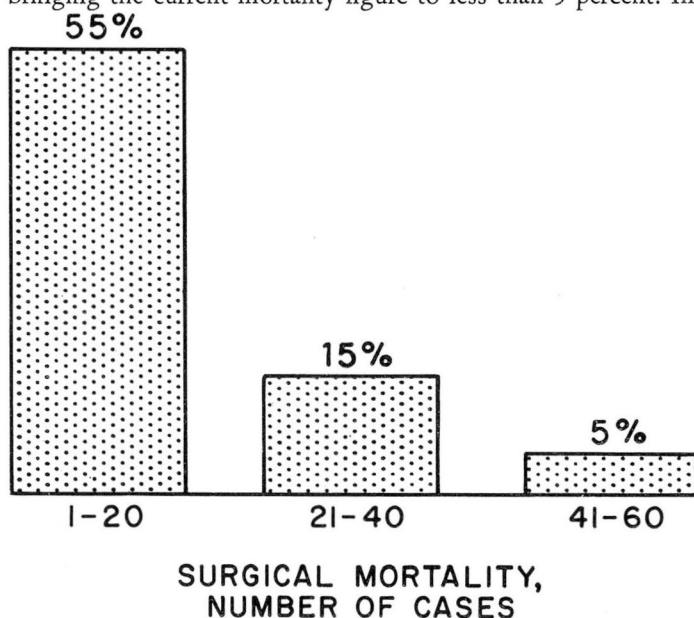


Fig. 2. Bar graph showing surgical mortality in series of 60 patients who underwent aortic valve replacement.

ment in surgical mortality is related to a number of factors. Certainly improved technic and facility, and resultant reduction in operating time for surgical replacement of the aortic valve, are significant. Excellent perfusion provided by the disc oxygenator,* and supplemental coronary arterial perfusion throughout the procedure have been beneficial factors. Routine prophylaxis with sodium methicillin† after prosthetic replacement has, for the present, eliminated the factor of postoperative infection that accounted for a number of early deaths. A major advance has been the use of the direct-current defibrillator, as suggested by Lown, Amarasingham, and Neuman,⁷ which shortens the resuscitation period, and, more important, encourages return to sinus rhythm even in patients who have demonstrated chronic atrial fibrillation for long intervals. The value of the direct-current defibrillator as an adjunct to the surgical treatment of acquired heart disease cannot be overemphasized.

Complications. Those ensuing complications that are minor and transient are not included here. Infection, postcardiotomy syndrome, heart block, bleeding, and embolus, are the complications that may contribute to ultimate mortality or may greatly prolong the postoperative convalescence of the patient. *Infection:* bloodstream infection and contamination of the valve prosthesis, in our experience, has been a consistently fatal complication. Serious infection has not been a problem since we instituted routine prophylaxis with methicillin for at least seven days after operation. *Postcardiotomy syndrome:* this is a little-understood entity attendant to intrapericardial surgery, and apparently is enhanced by extracorporeal circulation. It is characterized by fever and chest pain; disorientation, agitation, and hallucination are not uncommon. Skilled nursing care, vigorous antipyretic treatment, and injections of steroids seem to be the most effective treatment for this frequent complication.

Heart block: occlusion can occur after aortic valve replacement. Early in the series one of our patients died 54 days after surgery; his ventricular rate had never exceeded 50 per minute following valve replacement. A second patient, in whom complete heart block developed, has been supported for four months by an internal pacemaker.

Extensive calcification, particularly at the base of the right coronary cusp can invade the ventricular myocardium close to the main conduction pathway. Trauma incident to valve replacement may result in transient or permanent atrioventricular dissociation. When this occurs, prompt utilization of the internal pacemaker should be considered.

Bleeding: postoperative bleeding can be a troublesome feature during the immediately postoperative period. Bleeding from the heart or the aorta has not been a problem except in patients who have demonstrable degenerative changes in the aorta itself. Excessive bleeding is most likely to occur from the sternum or from

*Pemco Co., Cleveland, Ohio.

†Staphicillin, Bristol Laboratories.

the pericardium. Careful measurement of blood loss, together with a constant record of arterial and venous pressures is mandatory. Reoperation for relief of cardiac tamponade for control of a specific bleeding point has been necessary in three instances. All of these patients have recovered.

Embolus: there has always been great concern about thrombi arising on intra-vascular prostheses. Surgical replacement of the aortic valve was undertaken with the fear that systemic embolization would be a major hazard to the patient. This fear has not materialized. Efforts to remove the heavily calcified valve have been successful in almost every instance without subsequent embolization by calcific particles. Air embolus has been avoided in the operating room by careful venting of the left heart and the aortic root itself.⁸ Embolization from clot formation has not been a factor of concern in this series of patients. One patient who was readmitted to the hospital four and one-half months after operation, for treatment of a cardiac arrhythmia, suffered a nonfatal cerebrovascular accident. The source of the presumed embolus has not been established.

Anticoagulant therapy has not been used routinely in patients who have had prosthetic aortic valve replacement. It is our current belief that the hazard of complications attendant to this prophylaxis outweighs the expected gain that it may provide.

Comment

Our enthusiasm for the Starr-Edwards aortic valve prosthesis receives continued encouragement from the results. The need for such a satisfactory replacement of the diseased aortic valve was painfully evident when the disappointing results of aortic valvuloplasty were reviewed. At present, aortic valve replacement appears to be the treatment of choice for acquired aortic stenosis and for free aortic regurgitation. Continued reduction in the operative risk, and the consistent improvement in those patients who survive surgery, seem to justify this preference. However, the follow-up-time factor is short, and it will be several years before the validity of this attitude will have been thoroughly tested.

Addendum

Since the preparation of this report, 28 additional operations for aortic valve replacement have been performed by the authors.

References

1. Effler, D. B., and Groves, L. K.: Open-heart surgery for acquired valvular heart disease; present technique and trends. *Arch. Surg.* **84**: 155-169, 1962.
2. Akutsu, T.; Dreyer, B., and Kolff, W. J.: Polyurethane artificial heart valves in animals. *J. Appl. Physiol.* **14**: 1045-1048, 1959.

STARR-EDWARDS AORTIC VALVE

3. Seidel, W.; Akutsu, T.; Mirkovitch, V., and Kolff, W. J.: Mitral valve prosthesis and study of thrombosis on heart valves in dogs. *J. S. Res.* **2**: 168-175, 1962.
4. Starr, A., and Edwards, M. L.: Mitral replacement: clinical experience with ball-valve prosthesis. *Ann. Surg.* **154**: 726-740, 1961.
5. Effler, D. B.: Defects of mitral valve; current concepts of surgical treatment. *Cleveland Clin. Quart.* **29**: 167-176, 1962.
6. Effler, D. B., and Groves, L. K.: Mitral valve replacement: clinical experience with ball-valve prosthesis. *Dis. Chest* **43**: 529-538, 1963.
7. Lown, B.; Amarasingham, M. B., and Neuman, J.: New method for terminating cardiac arrhythmias; use of synchronized capacitor discharge. *J.A.M.A.* **182**: 548-555, 1962.
8. Groves, L. K., and Effler, D. B.: Needle-vent safeguard against systemic air embolus in open-heart surgery. *J. Thoracic & Cardiovas. Surg.*: In press.