

SELECTIVE SPLANCHNIC ARTERIOGRAPHY IN THE DIAGNOSIS OF PANCREATIC TUMORS

THOMAS F. MEANEY, M.D.,

Division of Radiology

EUGENE I. WINKELMAN, M.D., BENJAMIN H. SULLIVAN, M.D.,

and

CHARLES H. BROWN, M.D.

Department of Gastroenterology

IN the diagnosis of pancreatic tumors, a major obstacle is the relative inaccessibility of the pancreas for direct study. Although tumors of the brain and kidneys are often recognized by means of arteriographic methods, tumors of the pancreas have not been commonly diagnosed from a study of the pancreatic and peripancreatic arteries. Visualization of these vessels in the past has been dependent upon opacification of the abdominal aorta, and the nonselective distribution of the contrast material to aortic branches concerned with the pancreas. Consequently, the dilution of the contrast material by aortic blood, and the opacification of arteries not concerned with the pancreas have resulted in arteriograms with insufficient detail for diagnosis. However, these disadvantages were overcome by Ödman,¹ who used the technic of selective celiac arteriography. Moreover, he successfully demonstrated arterial displacement and distortion produced by pancreatic masses in two patients. In order to evaluate further the potentiality of selective angiography in the diagnosing of pancreatic tumors, we studied by selective celiac and superior mesenteric arteriography a series of 25 patients who had abdominal pain of obscure cause.

Method of Study

In each case the same procedure was used. After percutaneous introduction of a catheter into the femoral artery, by the Seldinger² technic, selective arteriography was performed. Under fluoroscopic observation, a radiopaque catheter was manipulated into the celiac artery and the superior mesenteric artery, and from 10 to 20 ml. of contrast material (Hypaque sodium, 50%*) was injected manually. Serial radiography in the anteroposterior and oblique or lateral projections was performed. No complications ensued.

Arterial Relationships of the Pancreas

The arterial blood supply of the pancreas is illustrated in *Figure 1*. The posterior aspect of the body of the pancreas lies in close apposition to the celiac axis. The splenic artery arises from it and lies along the superior border of the body and tail of the pancreas in its course to the splenic hilus. Many small branches

*Winthrop Laboratories.

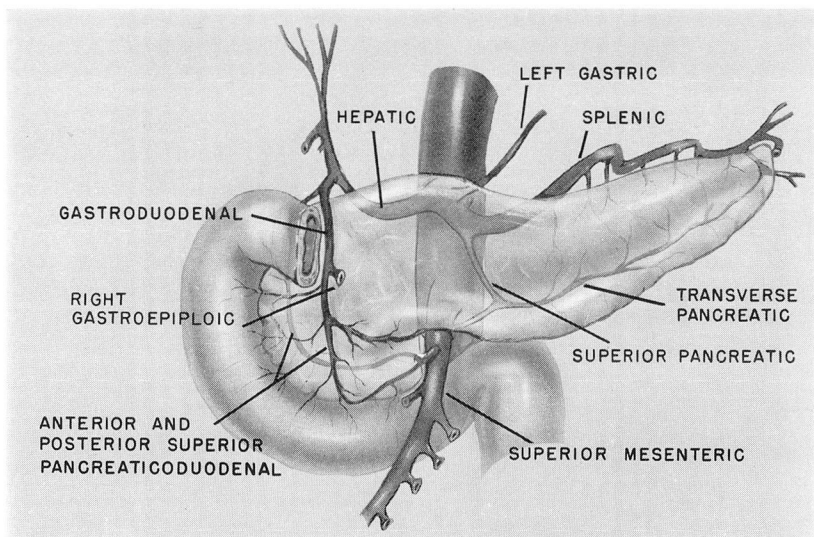


Fig. 1. The arterial relationships of the pancreas (after Pierson³). The hepatic and splenic arteries border the pancreas superiorly, and the body of the pancreas rests upon the celiac axis and the superior mesenteric artery. Numerous branches derived from these arteries ramify upon or within the pancreas.

arise from the splenic artery and enter the pancreatic substance. The hepatic artery usually arises as the other major branch of the celiac artery, and passes to the right in relationship to the superior aspect of the gland. From the hepatic artery the gastroduodenal artery arises, and descends upon the anterior surface of the head of the pancreas, where it divides into numerous branches. The transverse pancreatic artery (arteria pancreatica magna) passes through the pancreas accompanying the main pancreatic duct. The transverse pancreatic artery may be derived from either the gastroduodenal artery or the splenic artery.

The superior mesenteric artery arises from the aorta posterior to the pancreas, and emerges from its inferior border. From it a recurrent branch, the inferior pancreaticoduodenal artery, originates and is distributed to the head of the pancreas. Occasionally the hepatic artery is a branch of the superior mesenteric artery.

Results of Arteriography

Twenty-five patients having abdominal pain of obscure cause were studied. The arteriographic findings are listed in *Table 1*. Three patients in whom arteriographic abnormalities were demonstrated underwent exploratory laparotomy and each was found to have carcinoma of the body of the pancreas. In no case was resection of the tumor advisable. The arteriographic findings were similar in the three patients, and consisted of stenosis of the celiac artery and/or its branches, produced by tumor encasing the vessel. In the first patient, there was stenosis of

Table 1.—*Arteriographic findings in 25 patients studied for abdominal pain of obscure cause*

Diagnosis	Number of patients
Arterial encasement secondary to carcinoma of the pancreas	3
Occlusive disease of the atherosclerotic type	11
Hepatic artery occlusion	1
Normal	10
Total	25

the celiac artery at its origin, and a long segment of narrowing that affected the proximal portion of the splenic artery (*Fig. 2*). At the time of operation, these vessels were enveloped by tumor. In the second patient, the tumor also affected the celiac artery, producing a smooth region of stenosis and narrowing of the proximal portion of the splenic artery, although less in degree than in the first patient. In the third patient, the tumor encircled the root of the celiac artery and its hepatic branches, also producing stenotic segments (*Fig. 3*).

Comment

The anatomic relationship of the celiac and superior mesenteric arteries and branches to the pancreas is such that they are likely to be affected by growth or extension of neoplasm. The two usual arteriographic manifestations of tumor encountered in most regions of the body consist of displacement of vessels by neoplastic mass, and/or hypervascularity within the tumor itself (so-called tumor stain). A third type of evidence that was encountered in the patients studied in this series was arterial stenosis due to extrinsic encasement of the vessels by pancreatic tumor.

The differentiation must be made between stenosis due to neoplastic encasement, and narrowing secondary to atherosclerosis. The distinguishing feature of arterial narrowing due to tumor in this series is stenosis that is smooth and tapered. By contrast, the intimal lesions of atherosclerosis usually produce irregularity of the internal lumen. In addition, in two of the patients, the lesions were longer than would be expected in atherosclerosis.

Unfortunately, the arteriographic changes found in the three patients represented manifestations of invasion by tumor; none of the tumors was resected. It should be recognized however, that pancreatic arteriography is in the early stage of development, and it is believed that with increasing experience with technic and interpretation, arteriographic manifestations of early stages of pancreatic tumor may be found.

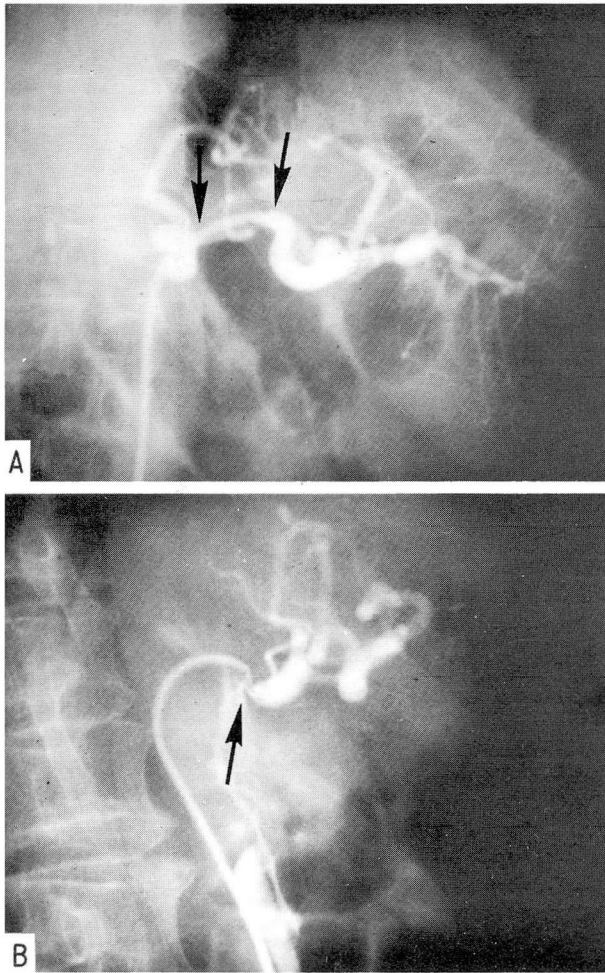


Fig. 2. A, Anteroposterior radiograph of the celiac arteriogram showing a long segment of narrowing of the splenic artery (arrows). In this patient, the hepatic artery was derived from the superior mesenteric artery. B, Lateral radiograph of the celiac arteriogram demonstrating marked encasement of the root of the celiac axis.

Summary

Selective celiac and superior mesenteric arteriography was performed in 25 patients who had obscure abdominal pain. In three of the patients in whom arteriographic abnormalities were found, exploratory operation revealed carcinoma of the body of the pancreas. Surgical resection of the invasive tumor was not safely possible in any of the patients. However, the arteriographic method, as applied to

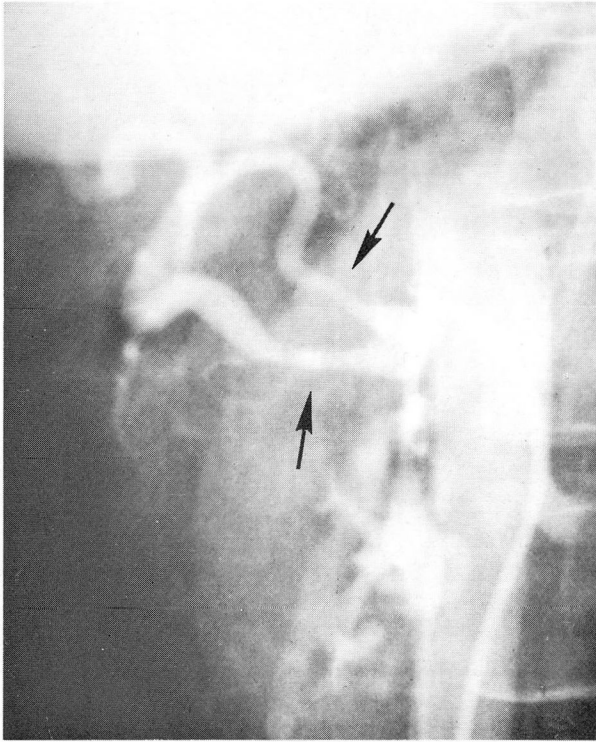


Fig. 3. Celiac arteriogram made with the patient in the right posterior oblique position. Two hepatic arteries originate from the celiac artery and both are enveloped by tumor, which has produced long segments of narrowing (arrows). Stenosis of the celiac artery was also present.

the pancreas, is in an early stage of development, and it is believed that eventually it may be possible to recognize arteriographic evidence of pancreatic tumors in earlier stages of growth than were found in this series.

References

1. Ödman, P.: Percutaneous selective angiography of coeliac artery. *Acta radiol. suppl.* **159**: 1-168, 1958.
2. Seldinger, S. I.: Catheter replacement of needle in percutaneous arteriography; new technique. *Acta radiol.* **39**: 368-376, 1953.
3. Pierson, J. M.: Arterial blood supply of pancreas. *Surg. Gynec. & Obst.* **77**: 426-432, 1943.