

Cleveland Clinic Quarterly

Volume 31

JULY 1964

No. 3

A MEDICAL SILASTIC PROSTHESIS FOR THE CONTROL OF URINARY INCONTINENCE IN THE MALE

A Preliminary Report

JAMES K. WATKINS, M.D.,* RALPH A. STRAFFON, M.D.,
and
EUGENE F. POUTASSE, M.D.†

Department of Urology

IN 1961, Berry¹ reported a new surgical procedure for the control of urinary incontinence, in the male, resulting from an ineffective sphincter mechanism. He created a new "sphincter" in the bulbus urethra by implantation of an acrylic prosthesis between the bulbocavernosus and the bulbus portion of the urethra. The prosthesis saddled the urethra and was fixed in position by four wire sutures located at each corner of the prosthesis, the wires being anchored to the fascia of the ischiocavernosus and the ischial tuberosities. The increase in urethral resistance created in the area of the bulbus urethra near the membranous urethra was sufficient to achieve continence, yet still allow a free-flowing urinary stream during mic-turition.

We have used a new material and have made minor modifications in the design of the prosthesis used in the Berry operation, and this preliminary report concerns our experience with five male patients treated for urinary incontinence.

*Fellow in the Department of Urology.

†Formerly member of the staff, Department of Urology; present address: 801 Medical Tower, Norfolk, Virginia.

Material

The material used for the prosthesis is silicone rubber (Medical Silastic), which has been widely used in recent years for medical implants in the human body. Among its attributes for this purpose are: (1) it causes minimal tissue reaction, (2) it is inexpensive, and (3) it is easy to prepare and to design for implantation.

The prosthesis is fashioned from a rectangular block of Medical Silastic approximately 3 cm. by 2 cm. by 0.75 cm. (Fig. 1A). A saddle effect is then achieved by creating a midline grooved depression on the inner or urethral surface of the prosthesis. The depression in the proximal end is made slightly larger than that at the distal end. The grooved depression is made with any smooth cylindric device (Fig. 1B and C).

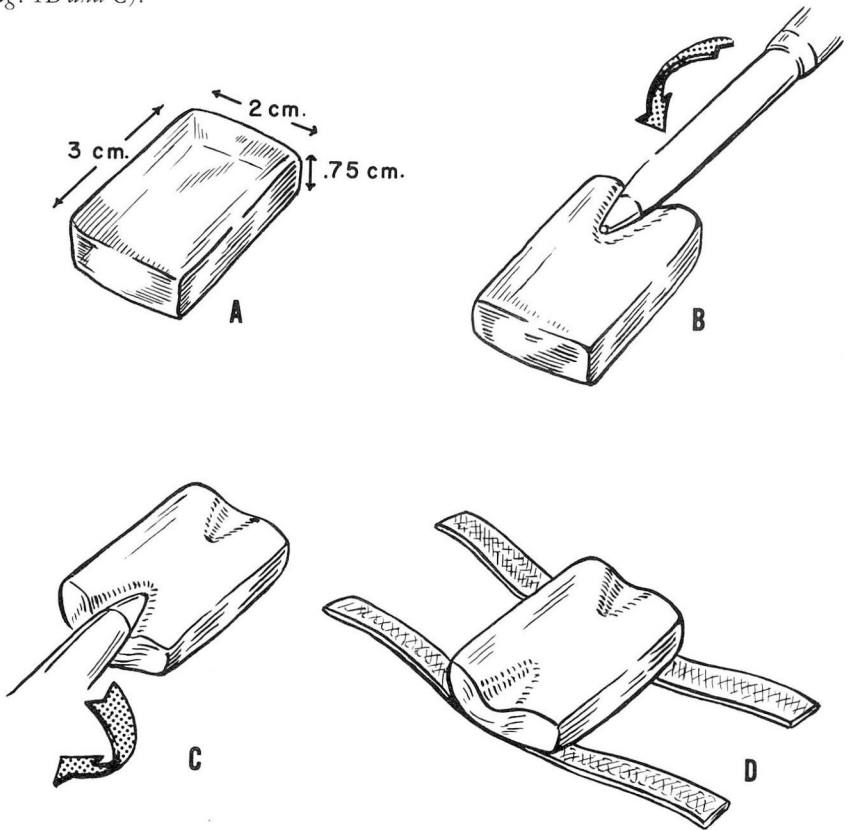


Fig. 1. Sketch showing the fashioning of the Medical Silastic prosthesis. A, A raw block of Medical Silastic of the approximate dimensions of the implant. B, Fashioning a urethral groove in the implant with a cylindric instrument. C, Rounding off the corners of the implant with the same cylindric instrument. D, Placement of the Silastic block on anchoring strips of dacron-impregnated Silastic—the completed Medical Silastic implant.

The Silastic block is placed on two strips of dacron-impregnated Silastic, approximately 15 cm. by 0.75 cm. by 0.1 cm. These strips serve to anchor the prosthesis in position when sutured to the fascia of the ischiocavernosus, and serve the same function as the corner wire sutures of the acrylic prosthesis described by Berry.¹ The completed prosthesis is shown in *Figure 1D*.

The total time for fashioning the prosthesis is about eight minutes. The raw Silastic is available in large sheets 0.75 cm. thick, and the entire prosthesis costs about 25 cents to make. It is evident that with this versatile material any variation of design or dimension of the prosthesis can be easily achieved. The prosthesis can be made in several sizes preoperatively and then the one that best fits the patient can be utilized at the time of implantation.

The necessity to clean and to sterilize the medical implants and to maintain them uncontaminated for implantation cannot be overemphasized. Surface contaminants, such as fingerprints, talc, dust, or lint can produce foreign-body reactions. The prosthesis is first boiled in a solution of water and green soap for about 15 minutes. This cleans the prosthesis and also vulcanizes the Silastic in the desired shape. The strips of dacron-impregnated Silastic initially cemented to the prosthesis are also vulcanized to the body of the prosthesis by this treatment. The prosthesis is then rinsed copiously in hot water, with a final rinse in distilled water. Sterilization is achieved by placing the prosthesis in a clean, lint-free, Pyrex dish that is heated to 400 F. in a dry oven for approximately one hour.

Technic

The surgical technic of inserting the prosthesis is essentially the same as that described by Berry.¹ A spinal anesthetic is usually administered to the patient, and a suprapubic trocar cystotomy tube is inserted into the bladder. The patient is then placed in an exaggerated dorsal lithotomy position and the perineum is prepared with Septisol* and aqueous benzalkonium chloride.† A 16F urethral catheter is inserted into the bladder and is left in place, during the operation, as an aid in positioning the prosthesis. A midline vertical incision is made extending from the perineal-scrotal angle posteriorly to approximately 3 cm. in front of the anus. The subcutaneous fascia is divided and dissected laterally, exposing the bulbocavernosus and the ischiocavernosus on either side. The midline raphe is divided for a 2-cm. length, and a pocket for the prosthesis is fashioned beneath the bulbocavernosus. The prosthesis is then inserted into position with the urethral groove saddling the bulbus urethra. The strips of dacron-impregnated Silastic are brought through the fibers of the bulbocavernosus laterally and each strip is sutured securely to the ischiocavernosus fascia and the ischial tuberosities on either side with two-zero silk sutures. The indwelling urethral catheter should be removed before the sutures

*Vestal Laboratories.

†Zephiran chloride, Winthrop Laboratories.

are tied, to insure maximum compression of the urethra. The prosthesis in place is shown in *Figure 2A and B*.

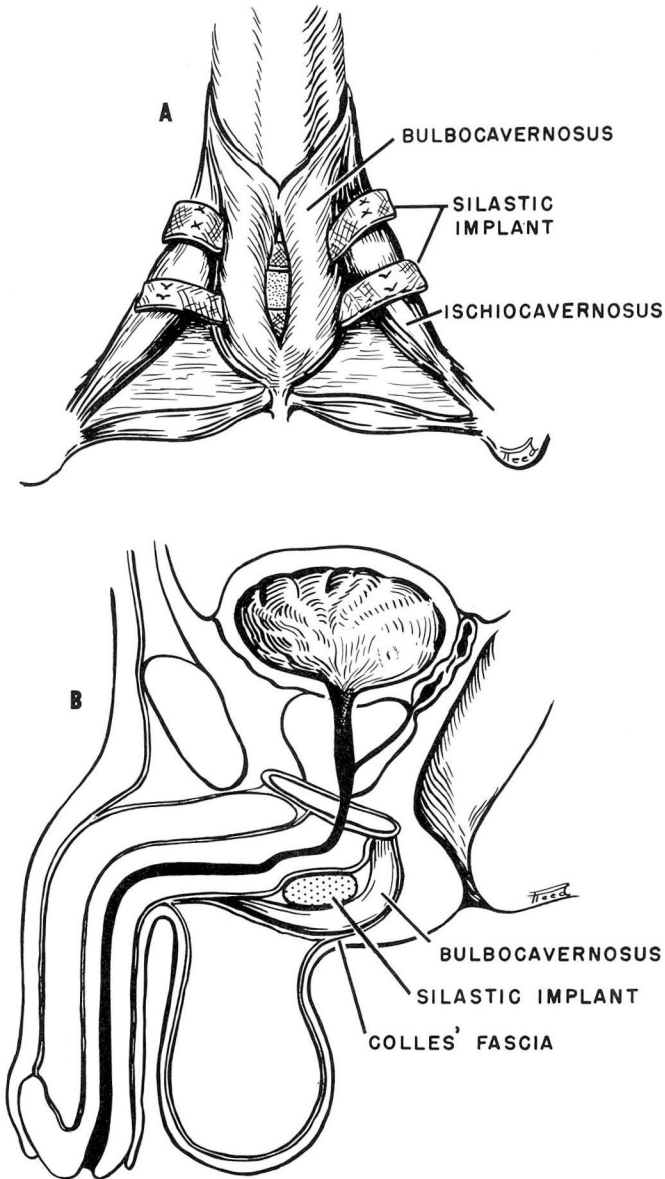


Fig. 2. Sketch showing the Medical Silastic prosthesis implanted in position for control of urinary incontinence in the male. A, Perineal view. B, Sagittal view.

The bulbocavernosus is then closed over the prosthesis and the incision is closed in layers. We prefer to use suprapubic catheter drainage for from five to seven days. Then the tube can be clamped and the patient be allowed to void. If he is able to void satisfactorily, and to empty the bladder without residual urine, the suprapubic tube is removed.

Selection of Patients

Selection of patients is important in utilizing this special treatment for urinary incontinence in males. All patients should receive a thorough urologic examination which must include a cystometric examination, residual urine check, panendoscopy, and cystoscopy. The patients who have had the best results from implantation of the prosthesis are those with incontinence secondary to damage to the sphincter mechanism after prostatectomy.

Patients with urethral strictures that require frequent urethral dilatations are not good subjects, inasmuch as frequent instrumentation can dislodge the Silastic prosthesis. Incontinence secondary to neurogenic bladder, or obstruction uropathy with overflow incontinence, can be discovered and treated appropriately if the patient receives a good urologic evaluation.

Results

We have utilized this prosthesis in five male patients, all of whom had dribbling incontinence after prostatectomy. Duration of symptoms ranged from 12 months to 12 years. After insertion of the prosthesis, each patient initially achieved total continence. They have been followed up postoperatively for periods ranging from nine months to one year.

The first patient, a 71-year-old man, had dribbling incontinence since October, 1962, after undergoing a transurethral resection of a vesical neck contracture. The vesical neck contracture developed after a transurethral resection of the prostate in October, 1952. A Medical Silastic prosthesis was inserted in May, 1963, after which he was continent and satisfied with his voiding pattern. Five months later some slowing of the urinary stream developed, relieved by a single urethral dilation. Approximately four months later, again slowing of the stream occurred and became progressively slower. Panendoscopy revealed that the vesical neck contracture had recurred and he was carrying a large amount of residual urine. The prosthesis seemed to be in satisfactory position and was not notably obstructing the urethra. Trocar cystostomy was performed and revision of the vesical neck will be necessary.

The second patient, a 57-year-old man, had been incontinent since a transurethral resection of the prostate in August, 1961. The prosthesis was inserted in June, 1963, after which he was continent and voided with a good urinary stream. Approximately five months after insertion of the prosthesis, a perineal cutaneous fistula developed,

communicating directly to the area of the prosthesis. An attempt to excise the fistula surgically was unsuccessful. Three months after the insertion of the prosthesis, we removed it, believing it to be acting as a foreign body and keeping the fistula open. After removal of the prosthesis, the fistula tract closed. Fortunately the patient has remained entirely continent despite the fact that the prosthesis is no longer present. The continence is probably due to fixation of the urethra from the inflammatory process that developed around the prosthesis.

The third patient, a 66-year-old man, had been incontinent since a transurethral resection of the prostate in May, 1961. Carcinoma was present in the resected tissue. He has been treated with estrogen since that time. In July, 1963, the prosthesis was inserted and he became continent and voided satisfactorily for approximately three months, when dribbling incontinence again developed. The position of the prosthesis was surgically verified: three of the anchoring sutures had loosened. It was necessary to resuture the anchoring strips of dacron-impregnated Silastic to the ischiocavernosus fascia and ischial tuberosities. One month postoperatively he again was continent and the voiding pattern was satisfactory.

The fourth patient, a 68-year-old man, had been incontinent since a transurethral resection of the prostate in 1952; carcinoma of the prostate was discovered at the time of resection. The prosthesis was inserted in August, 1963, and he has been continent, and has a satisfactory voiding pattern.

The fifth patient, a 60-year-old man, had been incontinent since a suprapubic prostatectomy was performed in October, 1961. The prosthesis was inserted in September, 1963. Since then he has been continent, and voiding with an excellent urinary stream.

Summary

The results achieved in five male patients treated for incontinence, with the Berry operation and a Medical Silastic prosthesis, are reported. It is our belief that the prosthesis made of the new material has merit for this operation, because it causes minimal tissue reactivity, it is low in cost, and one can easily prepare a variety of sizes and designs to custom fit the prosthesis for the patient.

Reference

1. Berry, J. L.: New procedure for correction of urinary incontinence: preliminary report. *J. Urol.* 85: 771-775, 1961.