

CURRENT CONCEPTS IN THE SURGEON'S TREATMENT OF BLEEDING DUODENAL ULCER

STANLEY O. HOERR, M.D.

Department of General Surgery

TEAM management of the patient experiencing severe upper gastrointestinal hemorrhage is today the rule rather than the exception. Recognition of the value of having a surgeon as well as the internist or family physician in attendance from the onset of bleeding represents the most significant advance in this field in recent years. It not only avoids a possibly fatal delay in operative intervention to have the surgeon on a standby basis, but it has also resulted in educating surgeons to the fact that the vast majority of serious hemorrhages will cease without an operation.

Gastric cooling as a means of achieving temporary control of bleeding is probably the most publicized innovation of the last decade in the management of bleeding. Less dramatic but perhaps of wider value have been several changes in surgical thinking and surgical technic, an example of which is the use of ligation of the base of a bleeding duodenal ulcer, coupled with the simpler and safer vagus transection with pyloroplasty rather than gastric resection.

Gastric cooling. Gastric cooling is to be distinguished from gastric freezing. In gastric cooling, intragastric temperatures of the order of from 6 to 10 C. (43 to 50 F.) are employed; whereas in gastric freezing, the stomach wall is frozen, and intragastric temperatures are of the order of from -10 to -20 C. (14 to -4 F.). Gastric freezing is employed in a few medical centers for the definitive treatment of chronic duodenal ulcer, but it is far from universally accepted. Gastric cooling, on the other hand, has shown itself to be a useful tool for the temporary control of bleeding. A large experience was reported by Wangenstein and associates.¹ Although many of the patients ultimately died, it is noteworthy that in the group of patients who had peptic ulcer, death was not due to hemorrhage except when the ulcer itself was a complication of a disease or stress.

Although cooling may be effective in arresting hemorrhage from a gastric or a duodenal ulcer, the threat of renewed bleeding when cooling ceases is ever present. The cooling apparatus demands constant surveillance while in use, and the technical details themselves must be executed carefully. Cooling is not to be undertaken lightly. Gastric balloons have been known to break, resulting in severe alcohol intoxication, requiring dialysis to save life. Stomachs have been frostbitten by too prolonged hypothermia. It is the belief of my colleagues and myself that gastric cooling is not the procedure of choice in most patients who have a problem of bleeding gastric or duodenal ulcers. Its principal value is for the occasional patient in whom the 'purchase of time,' to correct some reversible state such as electrolyte imbalance, or impending heart failure, will lessen the risk of operation. There also are

patients in whom the surgical risk is prohibitive because of associated disorders, and for these gastric cooling may be a useful supplement to the more usual conservative measures. The ultimate use of cooling in the treatment of bleeding esophageal varices, where so many other factors govern therapy, is not considered here.

Surgical approach to the bleeding ulcer. Often, bleeding will arise from a previously proved duodenal ulcer, or an ulcer that can be promptly found, after the surgeon opens the abdomen, because of the inflammatory reaction around it. For many years the standard procedure was to ligate the ulcer base, and then to perform a gastric resection. It was believed that failure to divert the gastric contents would simply lead to a secondary hemorrhage, often fatal. Dorton, Webb, and Royalty² first reported on the conservative surgical departure—ligation of the ulcer base and vagus transection with pyloroplasty—and the work has been advanced by Weinberg³ and by Farris and Smith.⁴ Thus, surgery for active bleeding from a duodenal ulcer has gone through a complete cycle since the original operative procedure of ligation of the bleeding vessels and excision of the ulcer.

The surgical experience of many others besides the originators of this procedure, has shown that it is effective in controlling bleeding in the majority of patients. In my surgical practice in the last six years I have been using this operation for nearly all patients who have bleeding duodenal ulcer. Secondary hemorrhage in the immediately postoperative course has not occurred, although several patients have had a recurrent hemorrhage a month or so later and required a subsequent gastric resection. The technic of the procedure is shown in *Figure 1*. The surgeon exposes

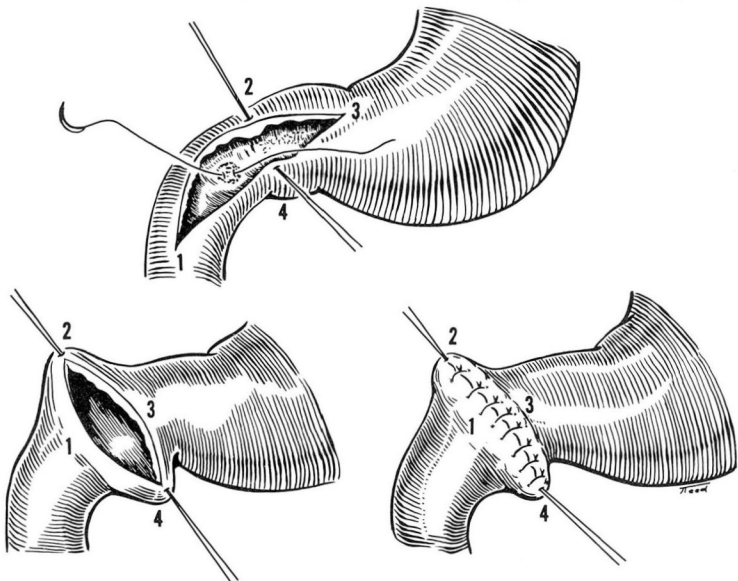


Fig. 1. Sketch showing ligation of base of bleeding ulcer, through a linear gastroduodenotomy that is then closed as a Heineke-Mikulicz pyloroplasty.

the bleeding ulcer by a generous gastroduodenotomy, ligates the ulcer base, and then closes the gastroduodenotomy either with a Heineke-Mikulicz pyloroplasty or a Finney type of pyloroplasty (side to side) as shown in *Figure 2*. Experience with

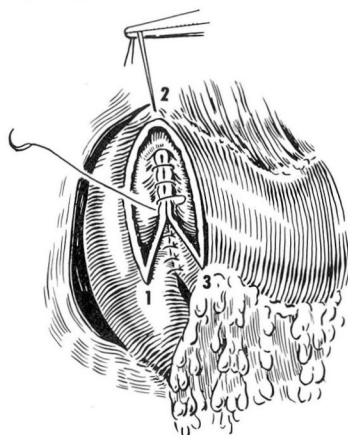


Fig. 2. Sketch showing closure of the gastroduodenotomy by a Finney pyloroplasty, preferred by many surgeons, and mechanically preferable in certain circumstances.

this procedure, and the evidence of the trend toward increased use of the procedure is shown in *Table 1*.

Table 1.—*Massive hemorrhage from duodenal ulcer*

Period	Surgical treatment			
	Gastric resection		Ligation of ulcer base with vagus transection and pyloroplasty	
	Cases	Death	Cases	Deaths
1950-1959	16	1	3	0
1960-1964	3	0	13	2*
Total	19	1	16	2*

*One death—patient never recovered from the anesthetic but bleeding was controlled.

One death—hemorrhage from another bleeding area in cirrhotic patient who previously had a portacaval shunt.

Investigation when the source of bleeding is not immediately apparent. The surgeon first performs a gastroduodenotomy. Often the stomach is filled with blood and clots and must be emptied partly by scooping as well as by suction. Some surgeons believe that extension of the gastroduodenotomy up into the stomach leads to problems in the closure of the incision, and they therefore employ a transverse type of incision high in the stomach, as shown in *Figure 3A*. On the other hand, I often employ a long extension of the original gastroduodenotomy, as shown in *Figure 3B*. This incision is then closed at the distal end with a Heineke-Mikulicz

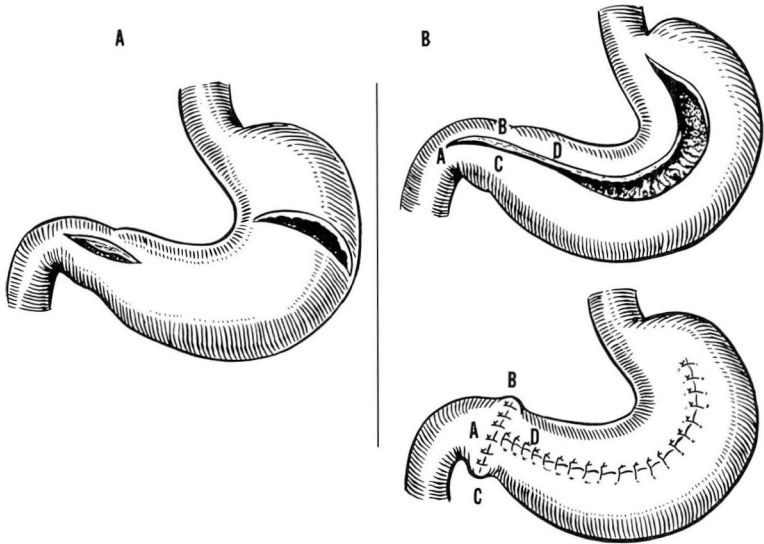


Fig. 3. A, Sketch showing transverse high gastrotomy and linear gastroduodenotomy for exploring interior of stomach and duodenum. B, Sketch showing the author's preference for exploration of the interior of the stomach by extending the gastroduodenotomy closure as indicated, with a Heineke-Mickulicz pyloroplasty joining the gastrotomy.

type of pyloroplasty. This type of closure does not seem to offer any greater risk of leakage than that after any other type of anastomosis. It is certain that wide exposure of the inside of the stomach is essential to locate some of the more obscure sources of bleeding. Easily overlooked is the long, narrow ulcer, which may occur in the lesser curvature close to the esophagogastric junction, and whose significance was pointed out some years ago by Gilchrist and Chun.⁵ Under special circumstances, even if the bleeding is from a gastric ulcer, a gastric resection may be difficult or unwise. Then, a similar procedure to that employed for bleeding duodenal ulcer is used: the ulcer bed is securely ligated; the vagus nerves are divided; and a pyloroplasty is performed. The increased employment of this procedure is shown in *Table 2*.

Table 2.—*Massive hemorrhage from gastric ulcer*

Period	Gastric resection		Ligation of ulcer base, biopsy of ulcer, vagus transection, and pyloroplasty	
	Cases	Deaths	Cases	Death
1950-1959	11	2	0	0
1960-1964	1	0	5	1*
Total	12	2	5	1*

*Death not from hemorrhage.

Surgeons and physicians have also become alerted to the Mallory-Weiss syndrome. Bleeding that follows unusually severe retching may be suspected of being due to lacerations along the lesser curvature, and a specific search is made for these lacerations.

A maneuver illustrated in a motion picture film by Dunphy⁶ is to irrigate saline through the duodenum, introducing it by catheter at the pylorus, and sampling it by a jejunotomy at the ligament of Treitz (*Fig. 4*). Active bleeding in the duodenum for a nonvisualized and nonpalpable source may be proved in this way.

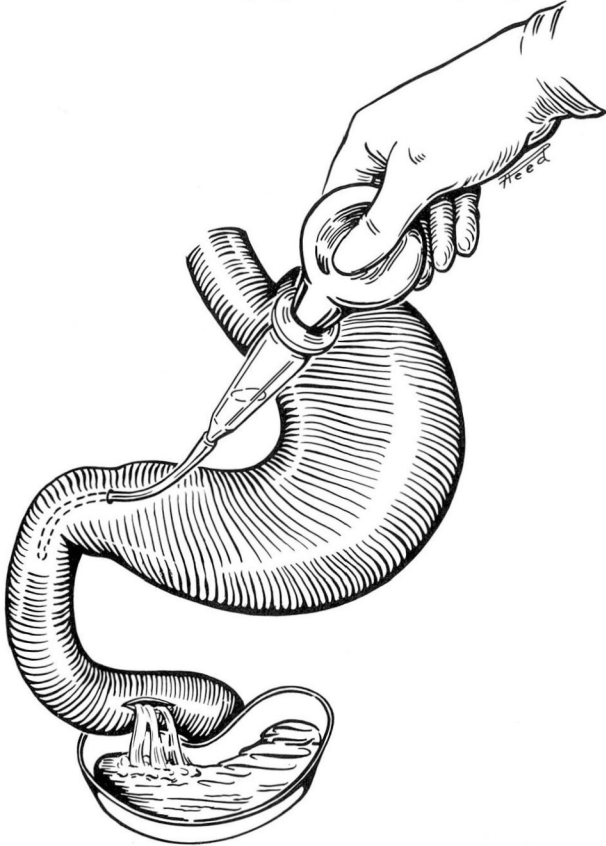


Fig. 4. Sketch showing method for determining active bleeding from an occult source in the distal duodenum. (Method of Dunphy.)

If neither lesion nor blood is found in stomach or duodenum, and active bleeding high in the small intestine from an occult lesion is suspected, a method for localizing the bleeding to a segment of intestine is as follows (*Fig. 5*). A segment about 18 to 20 inches long is isolated between enterostomy clamps; 5 to 10 ml. of saline is injected into the middle portion of this segment, and part of the solution

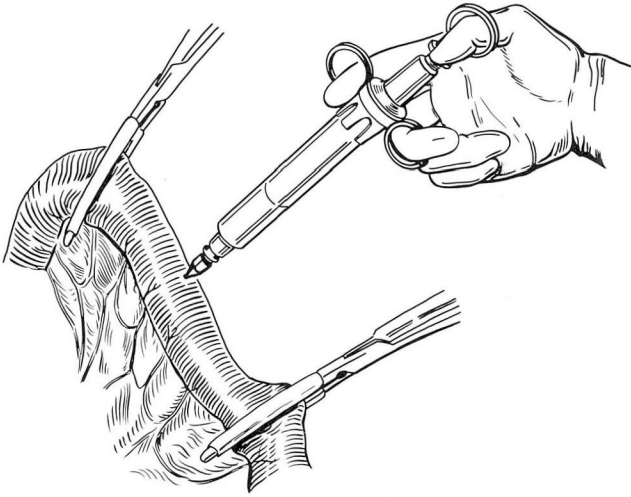


Fig. 5. Sketch illustrating method of injecting saline and withdrawing it to determine presence or absence of blood in a segment of small intestine.

is immediately withdrawn. If blood is present, the segment may be marked with a serosal suture with long ends, and the segment immediately proximal similarly tested. When a segment proves to be free of blood, several feet of small intestine distal to this area may be resected empirically and a search for the source conducted by surgeon and pathologist in the opened specimen. The author has used this method successfully to stop bleeding from an otherwise undetectable uremic ulcer that had been the cause of significant, continuing hemorrhage.

Bleeding point never found, or bleeding from diffuse gastritis. In some patients the source of the bleeding is never clearly demonstrated. Under these circumstances, surgeons, in the past, have performed a so-called blind gastrectomy, in the belief that it would be good treatment for any of the usual sources of bleeding, such as an unrecognized duodenal ulcer or gastric ulcer, bleeding from a hiatus hernia, or from an erosive gastritis. Gastric resection would seem to be wise for a massive hemorrhage from an erosive gastritis, but in many patients in whom the bleeding point is not identified, the best and safest procedure will be a vagus transection with a pyloroplasty. This procedure offers minimal risk to life and minimal disturbance of digestive function, with a chance of preventing recurrence almost equal to that of the blind gastrectomy.

Conclusions

The most significant improvement in the management of a patient bleeding from the stomach or duodenum has resulted from the use of a team approach with both a surgeon and the family physician or internist, observing together the progress

of the bleeding patient. The surgeon may then operate promptly if it should become necessary, but he also observes that in the majority of patients the bleeding will stop without surgical intervention.

Gastric cooling is effective in many instances in arresting hemorrhage from a gastric or duodenal ulcer, but is believed to have its principal usefulness in purchasing time for the occasional patient who has some coexistent disease or condition that will benefit by treatment before surgical exploration.

In the operating room, the surgeon now often performs the much simpler procedure of ligation of the ulcer base, vagus transection and a pyloroplasty for a bleeding duodenal ulcer, and may occasionally do the same operation for a bleeding gastric ulcer: excision of the ulcer or ligation of its base coupled with vagus transection and pyloroplasty.

If the source of the bleeding cannot be identified, the inside of the stomach may be inspected through a large incision. Particular attention is paid to the region just distal to the esophagus on the lesser curvature where bleeding linear ulcers or tears may exist. In instances when the bleeding point cannot be identified, vagus transection and a pyloroplasty may be performed, in preference to the less conservative blind gastrectomy that has been used under these circumstances.

References

1. Wangenstein, S. L.; Orahood, R. C.; Voorhees, A. B.; Smith, R. B., III, and Healey, W. V.: Intra-gastric cooling in management of hemorrhage from upper gastrointestinal tract. *Am. J. Surg.* **105**: 401-412, 1963.
2. Dorton, H. E.; Webb, J. G., and Royalty, D. M.: Vagotomy and pyloroplasty; simple safe solution to bleeding ulcer problem. *J. Kentucky M. A.* **50**: 16-19, 1952.
3. Weinberg, J. A.: Treatment of massively bleeding duodenal ulcer by ligation, pyloroplasty and vagotomy. *Am. J. Surg.* **102**: 158-167, 1961.
4. Farris, J. M., and Smith, G. K.: Vagotomy and pyloroplasty: solution to management of bleeding duodenal ulcer. *Ann. Surg.* **152**: 416-429, 1960.
5. Gilchrist, R. K., and Chun, N.: Severe hemorrhage in presumed peptic ulcer; surgical treatment in absence of demonstrable lesion. *A. M. A. Arch. Surg.* **69**: 366-377, 1954.
6. Dunphy, J. E.: *Surgical Exploration for Obscure Massive Upper Gastrointestinal Hemorrhage* (shows detailed steps to be taken in operating for severe upper gastrointestinal hemorrhage of unknown etiology). Sound, color, motion picture film. Boston, 1956.