

GAS GANGRENE TREATED WITH HYPERBARIC OXYGENATION

Report of a Case

JOHN F. SMART, M.D.,* JOHN HOMI, M.D.,
J. RICHARD R. BOBB, M.D., and CARL E. WASMUTH, M.D., LL.B.

Department of Anesthesiology

A NEW approach to the treatment of gas gangrene is to administer oxygen under high pressure. This is achieved by placing the patient in an environment where the pressure of the oxygen can be raised to two or three atmospheres. A rise in partial pressure of oxygen in the alveoli occurs, with a consequent rise in the tension of oxygen in the arterial blood and tissues (approximately fifteen times when the patient is placed in an oxygen chamber at three atmospheres). The increased oxygen tension present at the border of the advancing infection creates an environment unfavorable to the further growth and multiplication of the anaerobic *Clostridium perfringens*. The spread of the gas gangrene is thus limited and the disease arrested.

Experimental studies with dogs¹ and with rabbits² revealed that after ligation of the hepatic arteries the mortality from clostridial hepatitis was greatly reduced by administering oxygen under high pressure. Brummelkamp³ treated 37 patients, who had clostridial infection, with hyperbaric oxygen with good results. Of the eight deaths in the series only one was directly and two were indirectly attributable to the gas gangrene. Wallyn and associates,⁴ who treated two patients with hyperbaric oxygen, found that there was a remarkable reversal of the gas gangrene infection. Three patients who had gas gangrene were treated by oxygen under pressure at approximately two atmospheres by Karasewich and associates¹ and results were encouraging. VanZijl and Maartens⁵ treated nine patients, who had gas gangrene, with oxygen under pressure; six of these patients recovered.

We have had the opportunity to use hyperbaric oxygen in the treatment of a patient who had gas gangrene.

Report of a Case

In December, 1964, a 61-year-old man was admitted to the Cleveland Clinic Hospital because of ischemia of the left leg. He had a long history of peripheral vascular disease. In June, 1962, a left aortofemoral bypass graft was performed, followed by a left femoropopliteal bypass in June, 1964, after which ischemia developed in the left leg. On December 23, 1964, a femoropopliteal graft replacement was performed, but the circulation in the left leg remained poor. As a result, the left leg had to be amputated below the knee on January 7, 1965.

First postoperative day (January 8). The patient's temperature rose to 102 F. and his pulse rate to 108. Late in the day the temperature rose to 103 F., and he became confused and disoriented. Examination of the amputation stump revealed crepitus in the leg and thigh. A clinical diagnosis of gas gangrene was made. A smear, taken from the wound at that time, later revealed the

*Fellow in the Department of Anesthesiology.

presence of *Clostridium perfringens* and staphylococci. His temperature rose to 105 F.

Second postoperative day. Early in the day the patient was examined by two of us (J.H. and J.F.S.) and the decision was made to treat him in the high pressure oxygen chamber (Fig. 1).

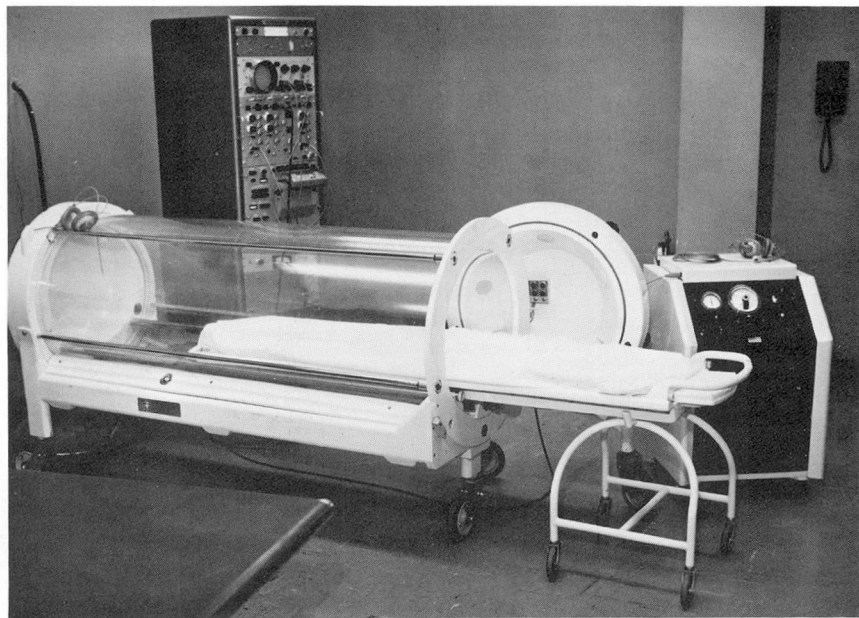


Fig. 1. Photograph of the chamber used at the Cleveland Clinic, a Linde Vicker's Mark IV Adult High Pressure Chamber. It is cylindrical, approximately 7 ft. in length by 2 ft. 6 in. in diameter. The walls consist of two layers of half-inch Perspex separated by a half-inch air space. The chamber will supply oxygen at pressures up to 30 p.s.i. above atmospheric pressure.

The patient was placed in the chamber under a pressure of three atmospheres (absolute) of oxygen, but treatment was terminated after one and one-half hours as he was extremely confused and did not tolerate the chamber well.

Eight hours later the patient was jaundiced and the degree of toxicity had increased. Again he was placed in the pressure chamber, under three atmospheres of oxygen for two hours. It was then considered essential to open and to debride the wound, as oxygen could not enter any dead tissue present. Under spinal anesthesia debridement was performed. The muscle above the knee was found to be viable, but that below the knee was necrotic and was removed. A moderate amount of gas was present.

Later in the day, when the patient was placed in the chamber, he was weak and semicomatose. He soon regained consciousness, became alert, and began to ask questions. Two hours later he was removed from the chamber, and his general condition seemed improved.

Third postoperative day. The patient's general condition was greatly improved. His temperature was 103.6 F., and his pulse rate was 108. The treatment consisted of two two-hour periods of oxygen at three atmospheres, which was well tolerated.

Fourth postoperative day and thereafter. The gas gangrene now seemed to be well under control. The patient's temperature was 101 F. and his pulse rate 80. The jaundice had faded. At that time it appeared that treatment had been adequate, but, in order to ensure that this was actually the case, three further treatments, each of two hours at three atmospheres, were given on the fifth, sixth, and seventh days.

The patient's general condition improved, and on the eighth day an amputation above the knee was performed. Four days postoperatively, the fasciotomy wound on the thigh was closed. After an uneventful recovery the patient was discharged from the hospital on January 30, 1965.

Discussion

The case described demonstrated the inhibition of growth of *Clostridium perfringens* by oxygen at high tension. Aside from debridement, hyperbaric oxygenation was the only therapy employed. We believe that the patient's treatment was adequate after five two-hour periods of oxygen at three atmospheres. The patient's temperature remained elevated (101.4 F.), possibly because of secondary infection with staphylococci. Further treatment was given to ensure that the clostridial infection had been completely eradicated.

Although oxygen under pressure is of great value in the treatment of gas gangrene, surgical debridement will still retain an important place according to Wallyn and associates,⁴ and to Rifkind.⁶ This latter point was demonstrated in the case reported here. McNally and Crile⁷ showed that antibiotics gave good results in the treatment of this condition. Brummelkamp³ listed the following advantages of using oxygen under pressure in the treatment of gas gangrene: surgery can be performed on a patient in a nontoxic condition; only necrotic tissue need be removed and as a result radical surgery can be avoided; time gained allows necrotic tissue to be demarcated; and the complications of anti gas gangrene serum therapy can be avoided.

It would seem that if hyperbaric oxygen is used in the treatment of gas gangrene in the future, it may play a part in reducing the mortality and morbidity from this disease. The treatment of anaerobic infections may be shown to be one of the most rewarding fields for the application of hyperbaric oxygen. The relative values of surgery, antibiotics, anti gas gangrene serum, and hyperbaric oxygen in the treatment of gas gangrene still remain to be determined.

Acknowledgment

The authors express their thanks to Dr. Alfred W. Humphries, of the Department of Vascular Surgery, for permission to report this case.

References

1. Karasewich, E. G.; Harper, E. M.; Sharp, N. C. C.; Shields, R. S.; Smith G., and McDowall, D. G.: Hyperbaric Oxygen in Clostridial Infections, p. 36-40, *in* Boerema, I.; Brummelkamp, W. H., and Meijne, N. G. (editors): *Clinical Application of Hyperbaric Oxygen*; Proc. First Internat. Congress, Amsterdam, Sept. 1963. New York: Elsevier Publishing Co., 1964, 427 p.
2. Klopper, P. J.: Hyperbaric Oxygen Treatment After Ligation of Hepatic Artery in Rabbits, p. 31-35, *in* Boerema, I.; Brummelkamp, W. H., and Meijne, N. G. (editors): *Clinical Application of Hyperbaric Oxygen*; Proc. First Internat. Congress, Amsterdam, Sept. 1963. New York: Elsevier Publishing Co., 1964, 427 p.
3. Brummelkamp, W. H.: Treatment of Infections With *Clostridium welchii* by Oxygen Therapy at 3 Atmospheres; a Report on 37 Cases, p. 20-30, *in* Boerema, I.; Brummelkamp, W. H., and Meijne, N. G. (editors): *Clinical Application of Hyperbaric Oxygen*; Proc. First Internat. Congress, Amsterdam, Sept. 1963. New York: Elsevier Publishing Co., 1964, 427 p.

4. Wallyn, R. J.; Gumbiner, S. H.; Goldfein, S., and Pascale, L. R.: Treatment of anaerobic infections with hyperbaric oxygen. *S. Clin. North America* **44**: 107-112, 1964.
5. Van Zijl, J. J. W., and Maartens, P. R.: Discussion, p. 41-43, of reference 1.
6. Rifkind, D.: Diagnosis and treatment of gas gangrene. *S. Clin. North America* **43**: 511-517, 1963.
7. McNally, M. J., and Crile, G., Jr.: Diagnosis and treatment of gas gangrene of abdominal wall. *Surg. Gynec. & Obst.* **118**: 1046-1050, 1964.