

AMEBIASIS AND ULCERATIVE COLITIS

CHARLES H. BROWN, M.D., and EUGENE I. WINKELMAN, M.D.

Department of Gastroenterology

EPIDEMIOLOGICALLY, there seems to be no relation between amebiasis or amebic colitis and idiopathic ulcerative colitis. In geographic regions in which there is a high incidence of ulcerative colitis, such as in the United States and England, there is a low incidence of amebic dysentery, and vice versa. [Conversely, in those regions in which there is a high incidence of amebic dysentery (such as in some countries in South America and southwestern Asia), there is a low incidence of ulcerative colitis.] However, the apparent precipitation of typical ulcerative colitis by amebiasis in veterans returning from endemic amebic areas overseas suggests that the relationship between the two conditions may be closer than previously believed.

The diagnosis of ulcerative colitis is based upon typical proctosigmoidoscopic and roentgenographic features and the absence of pathogenic bacteria and parasites in the feces. Although it is generally accepted that the proctosigmoidoscopic findings in amebic colitis are specific, identification of the parasite *Endamoeba histolytica* is necessary for a definite diagnosis.

In amebiasis, large discrete ulcers with an overhanging edge are scattered throughout the rectosigmoid area with normal mucosa between the ulcers. In contrast, the mucosa of chronic ulcerative colitis is inflamed, edematous, and friable with many petechial ulcers. The roentgenographic changes in regard to ulcerative colitis may reveal an altered mucosal pattern, absence of haustral markings, or narrowing and shortening of the colon. These changes are dependent upon the severity and extent of the disease. They are diffuse and occur mostly in the sigmoid and descending colon; in contrast, the lesions of amebiasis are more localized to the cecum and ascending colon.

Although the confusion between amebic dysentery and ulcerative colitis is rare, several cases have been reported in which chronic idiopathic ulcerative colitis was apparently mimicked by amebiasis. McAllister¹ reported three cases in which typical proctoscopic and roentgenographic findings of idiopathic ulcerative colitis and *E. histolytica* were found. Specific antiamebic treatment of the three patients resulted in rapid remission of the symptoms.

Passarelli² reported that *E. histolytica* was found in 5 of 18 patients whose conditions had been diagnosed as chronic idiopathic ulcerative colitis. Paulley³ reported that he had seen six patients in whom amebic colitis resembled ulcerative colitis. Monaghan⁴ stated, "Great difficulty may be encountered in those rare cases of chronic amebic dysentery in which a diffuse ulcerative colitis develops as a result

From a paper presented at Asociacion Mexicana de Gastroenterologia, Mexico City, D.E., Mexico, April 29, 1964.

of secondary infection of the colonic mucous membrane."

One of us (E. I. W.) followed the progress of two patients who had typical proctosigmoidoscopic and radiologic findings of ulcerative colitis, confirmed by other experienced observers; both patients responded poorly to treatment for ulcerative colitis; *E. histolytica* eventually was found in the stools. Subsequently, antiamebic therapy* alone resulted in symptomatic improvement, and a return of rectal mucosa to normal. The response of one of the patients to treatment for ulcerative colitis was so poor that colectomy was planned for the next day, but when *E. histolytica* was found in the stool examination, colectomy was canceled.

Reed and Rochex⁵ reported that 7 of 30 patients with idiopathic ulcerative colitis had a history and findings of amebiasis immediately antedating the ulcerative colitis. Collins and Bynum⁶ treated four patients each of whom had amebiasis and in whom proctoscopic and roentgenographic evidence of idiopathic ulcerative colitis was found. Each patient was treated both for amebiasis and for idiopathic ulcerative colitis, and responded well to combined therapy.

Report of Findings

1. *Failure to recognize amebiasis associated with idiopathic ulcerative colitis.* Since the report of the four patients treated by Collins and Bynum,⁶ we have examined 12 patients with typical ulcerative colitis according to proctoscopic and barium enema studies, who also had *E. histolytica* in the feces.

All the patients had bloody diarrhea, abdominal cramping, and weight loss; proctoscopically all were seen to have the diffuse inflammation characteristic of idiopathic ulcerative colitis. In addition, barium enema examination of the colon showed various degrees of involvement of the colon typical of ulcerative colitis. The sigmoid colon and the descending colon were most frequently and more severely involved than the rest of the colon.

Seven patients had received no prior treatment except symptomatically, such as paregoric for the diarrhea. In each patient, at the time of the first examination at the Cleveland Clinic, both the typical proctoscopic and barium enema findings of idiopathic ulcerative colitis as well as numerous *E. histolytica* trophozoites were present. Each patient received therapy for amebiasis as well as for idiopathic ulcerative colitis. The antiamebic agent was arsthinol†⁷ in a dosage of 5 tablets (100 mg. each) every morning for from 5 to 7 days. While a good response was reported in regard to similar patients treated with antiamebic agents alone,¹ we hesitated to rely solely on that treatment. The patients also received one of the nonabsorbable sulfa drugs, special diets, vitamins, other supportive measures, occasionally steroids in small doses, and sometimes cortisone retention enemas,^{8,9} although steroids have been noted to cause a flare-up in amebic colitis and the systemic dissemination

*Emetine, Eli Lilly and Company.

†Balarsen, Endo Products.

of amoebas. All of the patients responded promptly and satisfactorily to treatment. It is not known to what extent the treatment other than the antiamebic therapy contributed to the patients' favorable progress.

Five patients were examined who had previously received various types of treatment for extensive idiopathic ulcerative colitis of long standing, but who had not been treated for amebiasis. Repeated warm-stage stool examinations of these patients were positive for the vegetative form of *E. histolytica*. Each patient had responded poorly to the prior treatment for ulcerative colitis, but improved on the combined therapy, strongly suggesting that the addition of the antiamebic drug was the decisive factor.

Case 1. A 58-year-old man was first examined at the Cleveland Clinic in 1957 because of typical ulcerative colitis of five years' duration. He stated that he had been treated with autogenous vaccine and other medication, but continued to have episodes of diarrhea. He was having 10 watery stools per day and had lost 25 pounds. Physical examination showed evidence of mitral stenosis and congestive cardiac failure. Proctoscopy disclosed a granular friable mucosa with loss of valve edges and much scarring. Barium enema examination showed extensive ulcerative colitis with pseudopolypoid changes throughout the entire colon (Fig. 1). Three warm-stage stool examinations revealed numerous *E. histolytica* trophozoites.

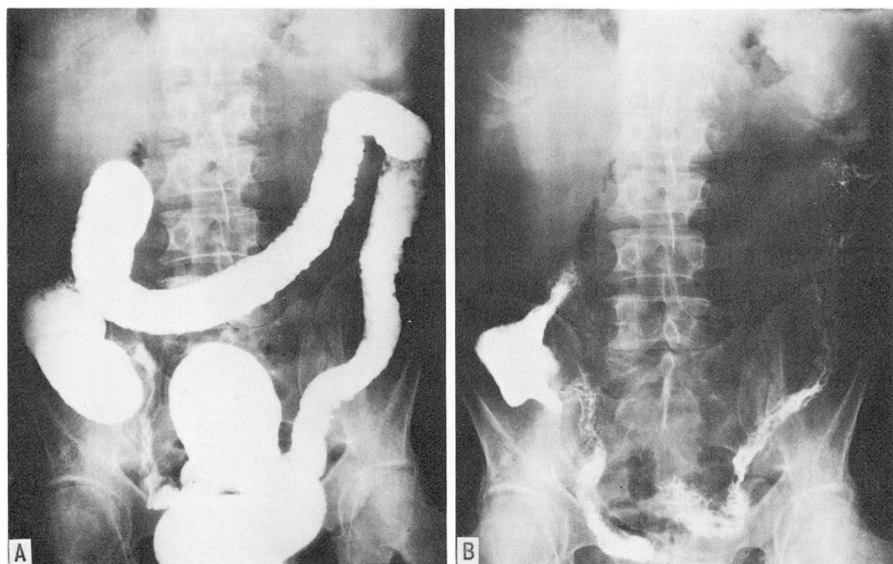


Fig. 1. Case 1 (7-30-57). A, Roentgenogram after barium enema, showing loss of haustral markings and evidence of ulceration. B, Evacuation roentgenogram after barium enema, showing distorted mucosal pattern.

The patient was given two courses of antiamebic therapy,⁷ phthalylsulfathiazole,* and supportive measures. Two months later he was having only two or three formed stools per day, and proctoscopic examination showed considerable improvement, with only a few scattered petechial ulcerations. For treatment of the mitral stenosis and congestive cardiac failure, a mitral commissurotomy was performed. Postoperatively there was no flare-up of ulcerative colitis.

*Sulfathalidine, Merck Sharp & Dohme.

Since October, 1957, the patient has remained well and has had no recurrence of ulcerative colitis. Proctoscopy has shown that the rectal mucosa has returned to normal. Repeated warm-stage stool examinations have been negative for amoebas. Barium enema examination showed a return of the colon to normal, with a return of haustral markings (Fig. 2). In 1959, the patient underwent bilateral herniorrhaphy and transurethral resection with difficulty. He has been examined annually and has remained asymptomatic in regard to the ulcerative colitis.

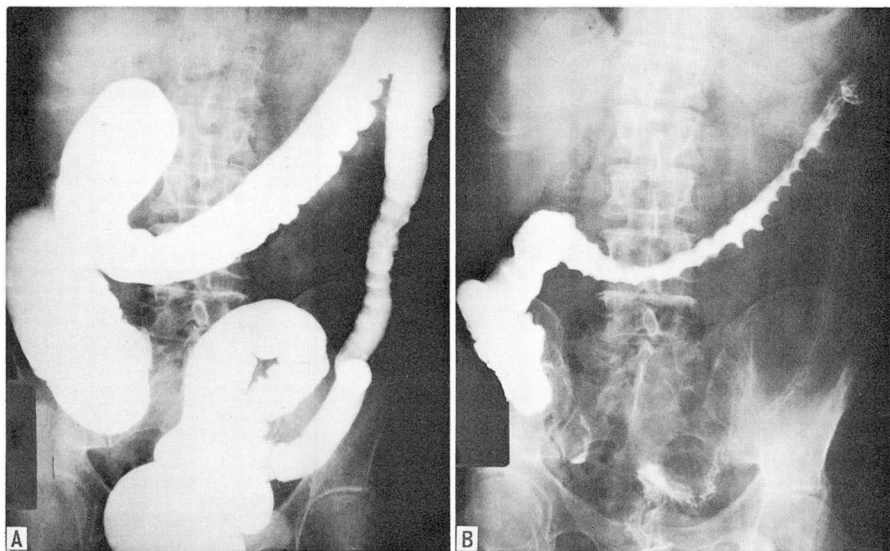


Fig. 2. Case 1 (6-10-58). A, Roentgenogram after barium enema, showing a return of haustral markings and a return of the colon to normal. B, Progress evacuation roentgenogram that also shows improvement.

The clinical course of the 12 patients is strong evidence that amebic colitis has masqueraded as ulcerative colitis. Lack of a thorough search for the parasite seems partially to account for the misdiagnosis. The fact that amebic colitis may produce sigmoidoscopic and roentgenographic changes identical to those of ulcerative colitis is also little realized. Unfortunately, a clinical picture of ulcerative colitis may decrease the index of suspicion of amebic colitis, and an intensive search for the parasite may not be made.

2. *Ulcerative colitis unresponsive to persistent antiamebic therapy.* In contrast to the previous group of patients, four patients we have examined were given many repeated courses of antiamebic therapy without any improvement. These four patients also had histories of bloody diarrhea, but amoebas were identified at warm-stage stool examinations at other hospitals. No information regarding barium enema and proctoscopic examinations was available to us. All four patients stated they had previously been given repeated courses of antiamebic therapy without favorable responses. One patient had received at least 12 courses of antiamebic therapy for more than a year without regression of symptoms.

On examination at the Cleveland Clinic, proctoscopic and barium enema studies

gave findings typical of chronic ulcerative colitis, and repeated warm-stage stool examinations were negative for amoebas. Each of the four patients had received more than ample antiamebic therapy, so this was not repeated. Intensive therapy for idiopathic ulcerative colitis^{8,9} relieved their symptoms, and improvement ensued in the results of proctoscopic and barium enema examinations.

In this group several assumptions are possible: (1) The initial misdiagnosis of amebic dysentery was made because the trophozoite of *E. coli* was mistaken for *E. histolytica*. Neither such information nor that regarding sigmoidoscopic or roentgenographic examinations is available to us, so that it is impossible to tell whether or not this was the case. (2) The two disorders existed concomitantly. (3) Amebiasis, although later satisfactorily treated, precipitated ulcerative colitis. Rarely does amebic dysentery fail to respond to adequate treatment. The persistence of the typical findings of ulcerative colitis after the disappearance of the trophozoites would favor the diagnosis of ulcerative colitis, particularly in view of its response to the treatment given for the latter; hence, a relationship between the two diseases may be reasonably postulated.

3. *Fatal and unrecognized amebic colitis.* In contrast to the previous 16 patients in whom both amebiasis and idiopathic ulcerative colitis were recognized and treated with a favorable outcome, we also have examined one patient who succumbed to the disease.

Case 2. A 76-year-old man was admitted to the Cleveland Clinic Hospital critically ill with severe toxicity, diarrhea, and dilated colon. The great extent of the disease prevented adequate study. Feces (not warm-stage stool examination) were negative for *E. histolytica*. The patient's condition deteriorated and toxic dilatation of the colon developed. Consequently, subtotal colectomy and ileostomy was performed. Pathologic examination of the specimen showed the typical changes of amebiasis, and direct smears from the colonic mucosa showed many trophozoites of *E. histolytica* (Fig. 3). Despite intensive antiamebic therapy in the postoperative period, the patient died. Postmortem examination was not performed.

This failure in treatment occurred in a patient whose primary symptoms were apparently of another condition: i.e., toxic ulcerative colitis. In this instance the diagnosis of amebiasis was not made preoperatively despite repeated stool examinations. The postoperative death, we believe, might have been prevented by the accurate diagnosis of amebiasis and the appropriate medical treatment.

Comment. It is extremely important to recognize amebiasis and to be aware that it may masquerade as idiopathic ulcerative colitis with its typical proctoscopic and roentgenographic findings. It is only by recognition of such possibilities that a concerted search for *E. histolytica* will be made, and appropriate treatment instituted. Every patient with diarrhea, with or without the findings of idiopathic ulcerative colitis, deserves this care. In addition to performing repeated warm-stage stool examinations of the patient with idiopathic ulcerative colitis, we employ an empiric trial of antiamebic therapy in a patient who has atypical ulcerative colitis.

We believe that there are numerous factors in the pathogenesis of ulcerative colitis. Any injury or insult to the colonic mucosa, whether due to severe emotional

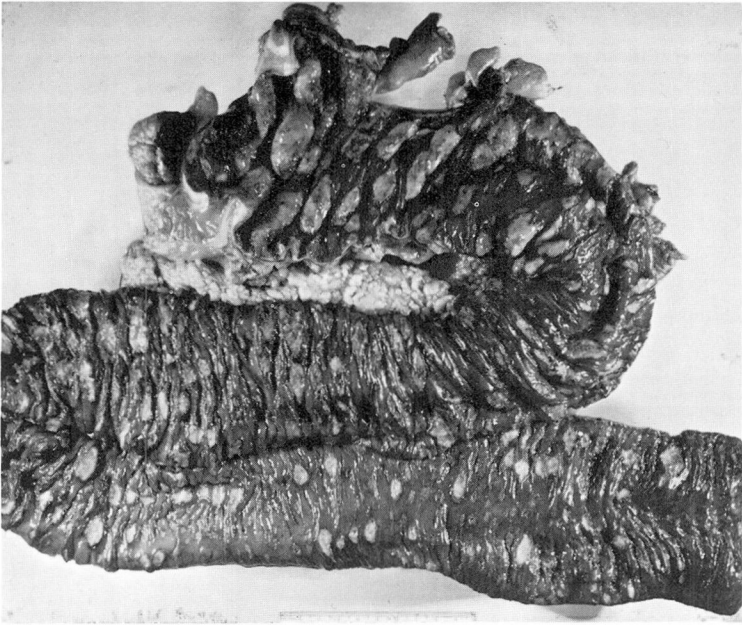


Fig. 3. Case 2. Gross specimen of colon with many large amebic ulcers.

stress,¹⁰ to local noxious agents,^{11, 12} or to specific infections such as bacillary or amebic dysentery, may precipitate ulcerative colitis in the susceptible individual. All of these factors should be considered in any patient with the findings of idiopathic ulcerative colitis.

Summary

Amebic colitis may mimic idiopathic ulcerative colitis. Twelve patients had typical proctoscopic and roentgenographic findings of idiopathic ulcerative colitis; all were found to have *Endamoeba histolytica* in their feces. Combined therapy for both ulcerative colitis and amebiasis resulted in the improvement of the clinical and abnormal proctoscopic and roentgenographic findings. Patients who have amebiasis respond poorly to the usual measures for ulcerative colitis, but respond well with the addition of antiamebic therapy.

Four other patients, with findings typical of ulcerative colitis, after repeated courses of antiamebic therapy without relief, responded to therapy for ulcerative colitis. Repeated antiamebic therapy is ineffective in patients with ulcerative colitis.

Amebiasis was not diagnosed in one patient who underwent surgical treatment and died postoperatively. Active search for *Endamoeba histolytica* is indicated in every patient with ulcerative colitis and in every patient whose clinical symptom is

bloody diarrhea.

In addition, a trial on antiamebic therapy may be indicated for any patient with atypical ulcerative colitis. When in doubt, the basis of treatment in patients with dysentery should be a trial course of antiamebic therapy.

References

1. McAllister, T. A.: Diagnosis of amoebic colitis on routine biopsies from rectum and sigmoid colon. *Brit. M. J.* **1**: 362-364, 1962.
2. Passarelli, N.: Chronic ulcerative colitis; introduction to its study; incidence in Brasil; general and etiologic considerations based on 18 cases. *Arq. brasil. med.* **50**: 55-82, 1960.
3. Paulley, J. W.: Amoebic liver abscess in Great Britain. *Brit. M. J.* **1**: 462-463, 1961.
4. Monaghan, J. F.: Ulcerative colitis, p. 549-614, *in* Bockus, H. L., and others: *Gastro-Enterology*, vol. **2**. Philadelphia: W. B. Saunders Co., 1944, 975 p.
5. Reed, A. C., and Rochex, F.: Treatment of chronic ulcerative colitis based on thirty cases. *Northwest Med.* **40**: 332-336, 1941.
6. Collins, E. N., and Bynum, F. L.: Amebiasis and indeterminate ulcerative colitis; combined therapy as applied to veterans from overseas. *M. Clin. North America* **32**: 408-418, 1948.
7. Brown, C. H.; Gebhart, W. F., and Reich, A.: Intestinal amebiasis. Incidence, symptoms, and treatment with arsthinol (Balarsen). *J.A.M.A.* **160**: 360-363, 1956.
8. Brown, C. H.: Treatment of acute and chronic ulcerative colitis. *Am. Pract. & Digest Treat.* **9**: 405-411, 1958.
9. Brown, C. H., and Merlo, M.: Topical steroid therapy for ulcerative colitis; report of fifty cases. *Am. J. Gastroenterol.* **36**: 343-354, 1961.
10. Brown, C. H.: Acute emotional crises and ulcerative colitis; report of seven cases. *Am. J. Digest. Dis.* **8** (new ser.): 525-536, 1963.
11. Brown, C. H.; Rankin, G. B.; Meaney, T. F., and Turnbull, R. B., Jr.: Normal mesenteric arteriograms in senile ulcerative colitis; report of case. *J. Am. Geriatrics Soc.* **12**: 215-220, 1964.
12. Brown, C. H., and Rankin, G. B.: Pathogenesis of ulcerative colitis; apparent precipitation of acute episodes by standard enemas. *Cleveland Clin. Quart.* **30**: 153-159, 1963.