

# NITROGEN MUSTARD IN THE TREATMENT OF CHRONIC ULCERATIVE COLITIS AND REGIONAL ENTERITIS

## A Preliminary Report

EUGENE I. WINKELMAN, M.D., and CHARLES H. BROWN, M.D.

*Department of Gastroenterology*

**D**RUGS originally developed for the treatment of malignant disease have been utilized in the therapy of certain nonneoplastic disorders—the various pathologic entities considered autoimmune diseases. Rheumatoid arthritis,<sup>1</sup> disseminated lupus erythematosus,<sup>2</sup> bronchial asthma,<sup>1,3</sup> and nephrosis<sup>4,5</sup> were treated with nitrogen mustard and other alkylating agents in the late 1940s and early 1950s, but then were almost entirely supplanted with corticosteroid preparations. In 1960, Damashek and Schwartz<sup>6</sup> reported the use of antimetabolite drugs in treating autoimmune hemolytic anemia and disseminated lupus erythematosus. In 1963, Taylor<sup>7</sup> reported the successful use of nitrogen mustard in the treatment of idiopathic autoimmune hemolytic anemia, but more recent reports have been concerned mostly with 6-mercaptopurine (6MP) or thioguanine (6-TG). These agents have been used to treat not only disseminated lupus erythematosus and autoimmune hemolytic anemia,<sup>6,8,9</sup> but the nephrotic syndrome,<sup>8</sup> lupoid hepatitis (plasma-cell hepatitis),<sup>8,10,11</sup> scleroderma,<sup>11</sup> atopic dermatitis,<sup>11</sup> psoriasis,<sup>12</sup> and hyperglobulinemic purpura.<sup>13</sup> A single case of ulcerative colitis successfully treated with 6-mercaptopurine has also been reported by Bean.<sup>14</sup> Bean<sup>15</sup> at present has treated seven patients with antimetabolites (6-mercaptopurine, 6-thioguanine, and busulfan\*); seven patients chronically ill with ulcerative colitis improved, as evaluated by serial biopsies of the rectum and serial barium-enema roentgenographic studies. Bowen, Irons, Rhodes, and Kirsner<sup>16</sup> have utilized the immunosuppressive drug, azathioprine,† to treat 10 patients with ulcerative colitis.

The frequent failure of chronic ulcerative colitis and regional enteritis and their complications to respond to medical treatment, the profound side effects of large doses of adrenocorticotrophic hormone (ACTH) and corticosteroids necessary to maintain remission, and the postulated autoimmune mechanism all suggested to us the feasibility of adding an alkylating or antimetabolic agent to our treatment program. Other anticipated benefits were an antiinflammatory effect as well as reduction of the steroid dosage to a level more easily tolerated by the patient, the so-called "steroid-sparing effect."<sup>8</sup> We selected nitrogen mustard because of

---

*From a paper presented at the Regional Meeting of The American College of Physicians, January 21-22, 1965, Cincinnati, Ohio.*

\*Myleran', Burroughs Wellcome & Co. (U.S.A.) Inc.

†Imuran', Burroughs Wellcome & Co. (U.S.A.) Inc.

familiarity with its use.<sup>17\*</sup>

The courses both of chronic ulcerative colitis and of regional enteritis are notoriously variable; hence, conclusions in regard to the value of treatment must be conservative. In this study we used the patient's history and lack of response to previous treatment as the control, and we treated only those patients in whom the prognosis appeared poor without a change in therapy. This then included patients with frequent exacerbations while on an optimal program of treatment, patients with side effects (from the course of therapy they were following) so severe as to require cessation of treatment, or patients with complications that seldom heal without surgical extirpation of the disease. Therefore, this was a selected group of patients studied solely on a preliminary basis to assess the value of a future strictly controlled study.

### Ulcerative Colitis

Fourteen patients with chronic ulcerative colitis were selected, on the basis of the criteria mentioned, for nitrogen mustard therapy. In all of the patients the proctosigmoidoscopic and roentgen findings typical of ulcerative colitis were present. There were seven males and seven females ranging in age from 15 years to 69 years. The duration of symptoms ranged from 1 year to 27 years for all but one patient who was symptomatic for only six weeks.

The clinical states at the onset of alkylation therapy were classified as (1) toxic, (2) acutely ill, and (3) chronically ill. The toxic state was defined as being present when the patient had two or more of the following findings: (a) an abrupt worsening of the clinical condition (from several hours to several days), (b) obtunded sensorium, (c) abdominal distention, (d) megacolon, (e) continual fever (102 F. and higher), (f) continuous tachycardia (pulse rate of 120 and higher), (g) anemia (blood hemoglobin, 8 gm. per 100 ml. or less), (h) electrolyte imbalance (hypokalemia, serum potassium value of 2.5 mEq. per liter or less), (i) diarrhea (profuse night and day), and (j) rectal bleeding.

The acutely ill patients were those for whom hospitalization was necessary, but whose symptoms were less severe than were those in the toxic state. Chronically ill patients were the adults who because of the disability were unable to assume their daily responsibilities, or the children who failed to thrive. These patients had diarrhea with or without rectal bleeding, systemic complications, and were unable to control the disease without excessive medication. Five patients were considered to be toxically ill, four acutely ill, and five chronically ill.

The responses to nitrogen mustard therapy were categorized as either satisfactory or unsatisfactory. The result was interpreted to be satisfactory when the patient returned to a normal productive life on a tolerable medical program, with disappearance or notable decrease in systemic and local complications. No improvement,

*\*The authors extend their thanks to Arthur L. Scherbel, M.D., of the Department of Rheumatic Disease, who originally suggested this study. He successfully treated a patient who had ulcerative colitis, with nitrogen mustard, and kindly gave us details of his experience with this drug.*

necessitating a recommendation for colectomy and ileostomy was considered as an unsatisfactory result.

All patients had been following a basic medical program that included a general diet, supplemental vitamins, an anticholinergic, antidiarrheal and/or a tranquilizing agent.<sup>18</sup> In addition, all but two patients received a combination of salicylazopyridine\* with either methylprednisolone acetate† retention enemas and/or ACTH‡, prednisone, or dexamethasone§.<sup>19</sup> One patient had received pre-ventricular electrolysis in addition to all of the above-mentioned medication.<sup>20,21</sup> Azulfidine alone was given to one patient, and prednisone solely to another.

*Treatment.* A nitrogen mustard, mechlorethamine hydrochloride||, was given slowly (over a five-minute period) into the tubing of an intravenous drip of dextrose and water containing 10 units of corticotropin which was given over an eight-hour period. ACTH was given to decrease nausea. A total of from 18 to 21 mg. was given over a six-day period in divided doses. Although this is not precisely calculated on a dosage per weight basis, it approximates a total dosage of 0.4 mg. per kilogram of body weight. The white blood cell count was determined every two days and the dosage was adjusted if significant leukopenia occurred during this period. To seriously debilitated patients, in whom leukopenia tended to develop rapidly, 10 mg. were given over a five-day period, with the remainder administered only after five days had elapsed and the white blood cell count remained within normal limits. All other medication was continued until completion of the intravenous administration of nitrogen mustard, when the steroid or ACTH was decreased as quickly as possible. Patients were discharged from the hospital with the advice to take small doses of prednisone (from 7.5 to 15 mg. daily) or ACTHAR-Gel\*\* (40 units three times a week). At the time of discharge from the hospital eight patients were given Uracil Mustard††, 1 mg., three times a week, in conjunction with their other medication. Two patients have taken from 2 to 3 mg. of Uracil Mustard each week for two years, while others have discontinued medication after from 3 to 12 months. All the patients were evaluated at monthly intervals clinically, proctoscopically, and hematologically. The program of medication was altered as necessary.

## Results

The results of the addition of nitrogen mustard to the therapeutic regimen for this group of 14 patients were regarded as satisfactory in 11 and unsatisfactory in three patients. Two of the chronically ill group had continuing symptoms despite

\*Azulfidine, Pharmacia Laboratories Inc.

†Depo-Medrol, The Upjohn Company

‡Corticotropin solution, Wilson Laboratories.

§Decadron, Merck Sharp & Dohme.

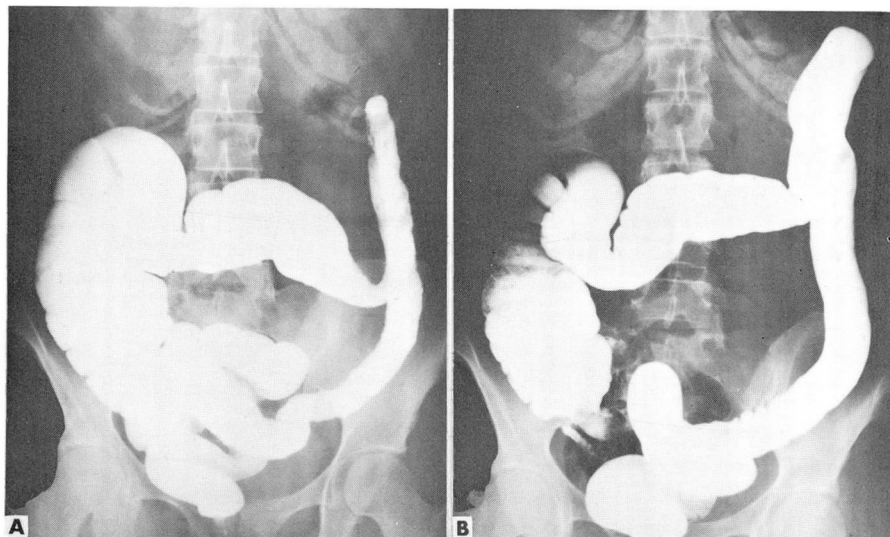||Mustargen HCl, Merck Sharp & Dohme.

\*\*H P ACTHAR Gel, Armour Pharmaceutical Company.

††The Upjohn Company.

optimum treatment. Both responded within two weeks to the addition of nitrogen mustard. One of these, a 35-year-old woman in remission for two years and without treatment for 14 months recently delivered a normal infant after an uneventful pregnancy. A patient with diarrhea, and the arthritis of chronic ulcerative colitis, noted disappearance of her symptoms within a month of her discharge from the hospital after alkylation therapy. One patient had been ill for four months with diarrhea, fever, weight loss and an enormous perianal fistula, with resulting fecal incontinence. Four months after the administration of nitrogen mustard the fistula had healed; he had regained 35 pounds and was back at work. Another patient had an intractable anemia that required frequent blood transfusions. This did not respond to the usual treatment, but after the addition of nitrogen mustard no further blood replacement was necessary.

Three of the acutely ill patients responded satisfactorily. They all improved within a month of the initiation of the alkylation therapy. One of these was a young woman with a rectovaginal fistula (*Fig. 1A*) that was no longer evident after three months. Two years later, findings on barium enema and proctosigmoidoscopic examinations were entirely normal (*Fig. 1B*).



**Fig. 1.** A, Roentgenogram showing evidence of active ulcerative colitis. Note the finely serrated margin of the rectosigmoid through the splenic flexure. B, Two years later; there is no evidence of ulcerative activity.

Within the toxically ill group three did well. One patient in whom toxic megacolon (*Fig. 2A and B*) developed now has a normal colon by barium enema study (*Fig. 2C*), and only minimal friability as observed at proctosigmoidoscopic examination. A second patient, who in addition had a Cushing's facies, striae, and

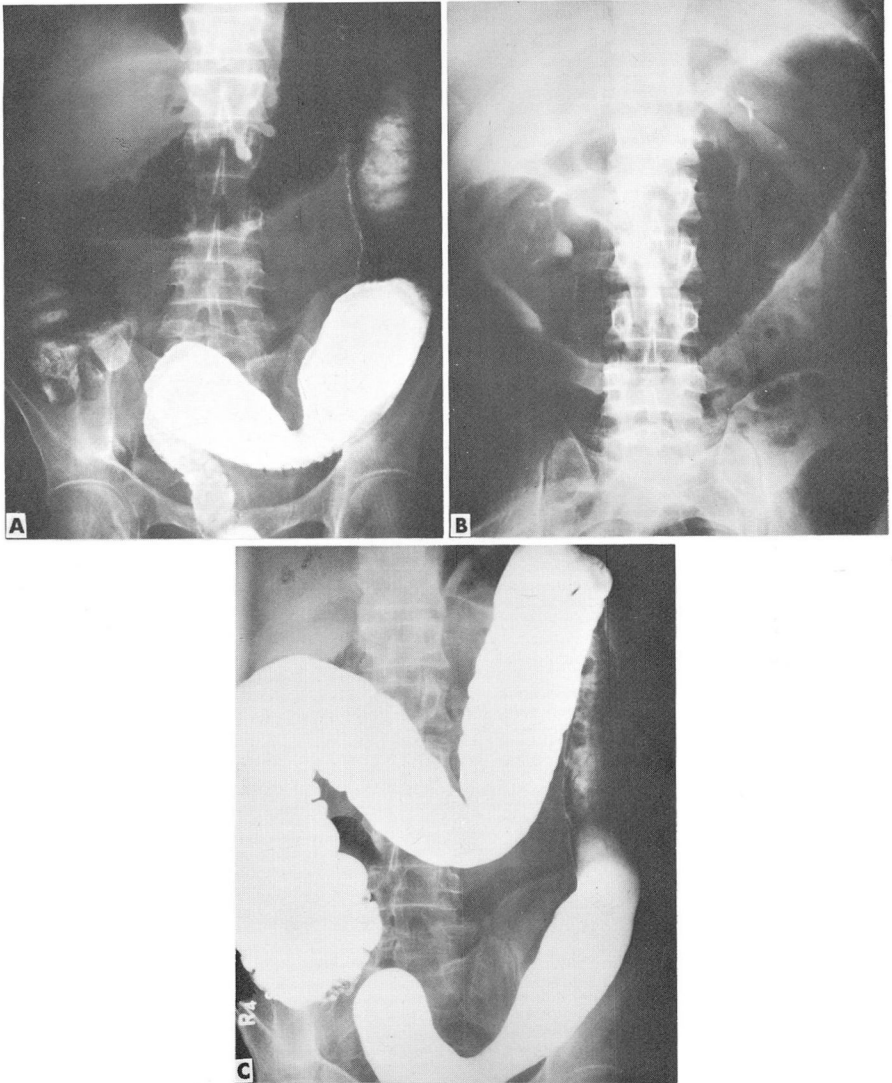


Fig. 2. A, Roentgenogram taken on September 7, 1963, showing evidence of acute ulcerative colitis. Note ulcerations throughout the colon. B, Roentgenogram taken on September 13, 1963, showing toxic megacolon. C, Roentgenogram taken on April 12, 1965, after nitrogen mustard therapy, showing no evidence of ulcerative activity.

acne while receiving large doses of dexamethasone, responded dramatically and 10 days later had normal stools. With the exception of a mild exacerbation nine months later he has been without treatment for two years and is back to full activity.

Sigmoidoscopic examination revealed only a minimal granularity and friability. The third member of this group required a month before his response was evident. One year later he is on minimal treatment and working regularly.

There were three patients who had unsatisfactory results, two within the toxically ill group. One patient died of progressive perforating enteritis six weeks after undergoing colectomy. The other patient was transiently improved after completion of the initial intravenous alkylating therapy, but megacolon developed thereafter and colectomy was required. Eighteen months later the patient was still chronically ill, principally from the mental depression that had been present previously. The sole failure in the acutely ill group was in a patient who subsequently died at home of acute myocardial infarction six weeks after his discharge from the hospital. He had refused to undergo the recommended colectomy.

*Side effects.* The side effects were predominantly those of a decrease in the number of white blood cells. The most profound decrease was to a level of 800 per cubic millimeter in one patient, while in three other patients the count fell to within a range of 1000 to 2000 per cubic millimeter. A fourth patient had a temporary decrease to 2100 per cubic millimeter. All values returned to normal ranges within a week after cessation of therapy and although the three patients who had an unsatisfactory result had depression of the white blood cell count, no temporal relationship was noted between the leukopenia and the poor outcome. Five patients reported that there was discoloration over the venous channels through which the nitrogen mustard was given, and in one patient a necrotic area developed where the nitrogen mustard inadvertently dripped on her skin while being injected into the tubing. Nausea was a rare complaint. In one patient a generalized erythematous maculopapular pruritic eruption developed three days after completion of his intravenous treatment, but the eruption disappeared within the next week.

### Regional Enteritis

Thirteen patients with regional enteritis, ranging in age from 14 years to 49 years, were selected to receive nitrogen mustard therapy. There were seven females and six males, in whom the duration of the disease, from the time of onset of symptoms to the start of alkylating therapy, was from 4 months to 16 years. A definite operative diagnosis had been made in nine patients; the remaining four were diagnosed by the typical clinical and roentgenographic changes. Each patient was classified as having complicated or uncomplicated regional enteritis depending upon the condition of the disease at the beginning of alkylating treatment. The group classified as uncomplicated cases, consisted of seven patients who had abdominal pain, diarrhea and/or constipation, anorexia, and weight loss, all of which were severe but not incapacitating or life-threatening. Those with simple fistula-in-ano or minimal perianal disease were included in this group. Patients with incapacitating or life-threatening systemic disease were classified among complicated

cases, as were those with obstruction, perforation, interabdominal abscesses, or severe abdominal and/or anal fistulization.

*Treatment.* The treatment program was the same as that given to the patients with ulcerative colitis. Although criteria for inclusion in the study were similar to those of the chronic ulcerative colitis group, only five patients had been on an intensive medical regimen before beginning nitrogen mustard therapy. Of those who had received intensive medical treatment, two had undergone hemicolectomy and ileocolostomy previously. None of the remaining eight patients had received either ACTH or corticosteroids but two had undergone previous surgery (one, a hemicolectomy and transverse ileocolostomy, the other, a transverse ileocolostomy).

### Results

The results of the use of nitrogen mustard in the treatment of regional enteritis were considered as satisfactory in nine and as unsatisfactory in four. Six of the satisfactory results were in patients who had previously been categorized as having uncomplicated regional enteritis whereas three were in those considered to have complicated regional enteritis. The complications that were resolved were a rectovaginal fistula in one patient, retroperitoneal perforation with abscess in one, and arthritis in one patient. Four patients who previously had received an intensive medical program that had not relieved the symptoms were among those patients who responded satisfactorily to the addition of nitrogen mustard to their therapeutic regimen.

Two of the four unsatisfactory results occurred in patients having uncomplicated regional enteritis. Both patients had the signs and symptoms of partial bowel obstruction when first seen and both were initially given nitrogen mustard and small doses of prednisone. They both did well for a month at which time complete obstruction occurred in one patient necessitating an ileotransverse colostomy. In the second patient an interabdominal abscess developed secondary to a perforation which was treated by drainage and resection.

The other two unsatisfactory results were in a group having complicated regional enteritis: a 46-year-old man with recurrence of diarrhea and several enterocutaneous fistulas 16 years after a hemicolectomy and transverse ileostomy; and an 18-year-old girl with cachexia, fever, diarrhea, abdominal pain and severe perianal disease. The latter patient received nitrogen mustard in addition to the 40 mg. of prednisone she had been receiving for the previous six weeks. There was brief improvement, but, three days after completion of a course of 12 mg. of nitrogen mustard, perforation of the terminal ileum occurred. An ileostomy was performed\* and the perforation closed. One week postoperatively a toxic course developed and despite the administration of heroic measures she died of fulminant perforating Crohn's disease of the colon and small intestine. The postoperative course had been complicated

\*Operation performed by Dr. Robert E. Hermann, Department of General Surgery.

by severe bone marrow depression, but two days before her death the white blood cell count and platelets had returned to normal.

*Side effects.* With the exception of the last patient mentioned, only two other patients exhibited decreases in the white blood cells. The white blood cell count in one was 2100 per cubic millimeter, in the other, 3100 per cubic millimeter, and in both, the counts returned to normal when the administration of nitrogen mustard was stopped. Four patients noted venous discoloration. Nausea was a rare complication.

### Discussion

All patients in this series had been on an intensive therapeutic program that utilized several drugs. The presence of these patients in this study signifies a failure of conventional drug therapy, just as the improvement after *the addition* of another potent agent implies a therapeutic effect. The healing of a rectovaginal fistula, the cessation of intractable anemia, and objective remission of a previously incapacitating arthritis in patients with ulcerative colitis are exceptionally impressive. That all failures were among the acutely and toxically ill suggests that this agent should not be used in the toxically ill patients.

As the majority of those patients with regional enteritis had not been on a complete medical program, the implication that nitrogen mustard was the effective drug cannot be inferred so strongly as in the ulcerative colitis group; however, a satisfactory result was obtained in four patients who previously had not been helped by an intensive medical regimen. The closure of a rectovaginal fistula and the resolution of crippling arthritis contrast with the usual clinical course; the most impressive result was the resolution of perforating enteritis after the failure of two surgical procedures. This occurred in a 16-year-old boy who, two months after the onset of the disease, underwent a right colectomy and transverse ileocolostomy. Shortly thereafter, at the site of the anastomosis, perforating ileitis developed and a retroperitoneal abscess resulted despite the use of corticosteroids. Three weeks later he was admitted to the Cleveland Clinic Hospital where the diseased segment was resected, the abscess was drained, and a new anastomosis made. Despite administration of ACTH and other supportive measures there was recurrence of the enteritis with partial obstruction, formation of a fistula, and involvement of the colon. Large volumes of steatorrheal stool produced dehydration, electrolyte imbalance, and protein depletion. Nitrogen mustard was added to the therapy and within 10 days the diarrhea had subsided. In three months he had returned to normal activity and six months later the results of proctoscopic and roentgen examinations were normal.

The sole fatality in the group of those who did not have definitive surgery occurred in a patient clinically diagnosed as having regional enteritis. Histologically the lesion was the same as that described by Morson and Lockhart-Mummery<sup>22</sup> as Crohn's disease of the colon with disease of the small intestine. At the time of the



perforation the patient was considered too ill to tolerate a resection, and thereafter bone marrow depression contraindicated further surgical intervention.

### Summary

Nitrogen mustard treatment was added to the therapeutic regimen of 14 patients with ulcerative colitis. There was a satisfactory response in 11 which included the resolution of complications usually resolved only with colectomy. Unsatisfactory results were obtained in three patients, two of whom were considered as having toxic ulcerative colitis.

Thirteen patients with regional enteritis were also treated with nitrogen mustard and satisfactory results obtained in nine—two of whom had closure of fistulas. There were four failures.

The evaluation of any therapeutic agent in ulcerative colitis and regional enteritis is difficult in that improvement with any change in therapy is not unusual. However, on the basis of these preliminary observations, characterized particularly by the resolution of complications rarely affected by medication and lack of response to previous therapy, we believe that the addition of nitrogen mustard to the usual medical regimen holds promise. No statement can be made in regard to the actual efficacy or the mechanism involved. It is recognized by the authors that to reach a valid conclusion a randomized group must be compared to an adequate control group. Such a study is underway.

### References

1. Díaz, C. J.; Garcia, E. L.; Merchante, A., and Perianes, J.: Treatment of rheumatoid arthritis with nitrogen mustard; preliminary report. *J.A.M.A.* **147**: 1418-1419, 1951.
2. Dubois, E. L.: Nitrogen mustard in treatment of systemic lupus erythematosus. *A.M.A. Arch. Int. Med.* **93**: 667-672, 1954.
3. Waldbott, G. L.: Nitrogen mustard in treatment of bronchial asthma. *Ann. Allergy* **10**: 428-432, 1952.
4. Taylor, R. D.; Corcoran, A. C., and Page, I. H.: Treatment of nephrotic syndrome with nitrogen mustard. (Abs.) *J. Lab. & Clin. Med.* **36**: 996-997, 1950.
5. Kelley, V. C., and Panos, T. C.: Nephrotic syndrome in children; clinical response to nitrogen mustard therapy. *J. Pediat.* **41**: 505-517, 1952.
6. Dameshek, W., and Schwartz, R.: Treatment of certain "autoimmune" diseases with antimetabolites; preliminary report. *Tr. A. Am. Physicians* **73**: 113-127, 1960.
7. Taylor, L.: Idiopathic autoimmune hemolytic anemia; response of patient to repeated courses of alkylating agents. *Am. J. Med.* **35**: 130-134, 1963.
8. Goodman, H. C. (moderator); Wolff, S. M.; Carpenter, R. R.; Andersen, B. R., and Brandriss, M. W.: Current studies on effect of antimetabolites in nephrosis, other non-neoplastic diseases, and experimental animals; combined clinical staff conference at National Institutes of Health. *Ann. Int. Med.* **59**: 388-407, 1963.

9. Demis, D. J.; Brown, C. S., and Crosby, W. H.: Thioguanine in treatment of certain auto-immune, immunologic and related diseases. *Am. J. Med.* **37**: 195-205, 1964.
10. Mackay, I. R., and Wood, I. J.: Course and treatment of lupoid hepatitis. *Gastroenterology* **45**: 4-13, 1963.
11. Page, A. R.; Condie, R. M., and Good, R. A.: Suppression of plasma cell hepatitis with 6-mercaptopurine. *Am. J. Med.* **36**: 200-213, 1964.
12. Kravetz, R. E., and Balsam, T.: Treatment of psoriasis with mercaptopurine. *Arch. Dermat.* **84**: 597-600, 1961.
13. Weiss, H. J.; Demis, D. J.; Elgart, M. L.; Brown, C. S., and Crosby, W. H.: Treatment of two cases of hyperglobulinemic purpura with thioguanine. *New England J. Med.* **268**: 753-756, 1963.
14. Bean, R. H.: Treatment of chronic ulcerative colitis with 6-mercaptopurine. *M. J. Australia* **49**: 592-593, 1962.
15. Bean, R. H.: Personal communication, June 29, 1965.
16. Bowen, G. E.; Irons, G. V., Jr.; Rhodes, J. B., and Kirsner, J. B.: Precautionary early experiences with immunosuppressive medication (azathioprine) in ulcerative colitis. (Abs.) *Am. Gastroenterological Association Meeting Programs, Montreal, Canada, May 28-29, 1965.*
17. Scherbel, A. L.: I. Intravenous administration of nitrogen mustard alone and with corticotropin for rheumatoid arthritis. *Cleveland Clin. Quart.* **24**: 71-77, 1957.
18. Brown, C. H., and Crile, G., Jr.: General treatment of ulcerative colitis. *GP* **6**: 35-41, 1952.
19. Brown, C. H., and Merlo, M.: Topical steroid therapy for ulcerative colitis; report of fifty cases. *Am. J. Gastroenterol.* **36**: 343-354, 1961.
20. Cattan, R.; Habib, R.; Libeskind, M., and Vésin, P.: *La Recto-Colite Hémorragique et Purulente (Ulcerative Colitis)*. Paris: Éditions Médicales Flammarion, 1959, 239 p.
21. Cattan, R.; Carasso, R.; Frumusan, P.; Nataf, P.; Soupault, R., and Boucaille, M.: Indications et résultats des interventions pré-frontales dans les recto-colites ulcéro-hémorragiques. *Semaine hôp. Paris* **33**: 15 p., 1957.
22. Morson, B. C., and Lockhart-Mummery, H. E.: Crohn's disease of colon. *Gastroenterologia* **92**: 168-172, 1959.