

Cleveland Clinic Quarterly

Volume 33

April 1966

No. 2

DIAGNOSIS AND TREATMENT OF RENAL NEOPLASM—A FRESH APPROACH

BRUCE H. STEWART, M.D.,

Department of Urology

AND

THOMAS F. MEANEY, M.D.

Department of Hospital Radiology

DIAGNOSIS of renal tumors in the past has been made principally on the basis of pyelography—either intravenous or retrograde. When there was definite radiographic evidence of a tumor deformity, renal exploration by the flank approach was usually advised. When a solid tumor was encountered, nephrectomy was performed; when a cyst was present, it usually was unroofed and drained.

Although this approach provided effective treatment in many cases, it nevertheless had several inherent drawbacks: (1) The tumor often has to be fairly well advanced before unequivocal pyelographic changes are evident, thereby causing a needless delay in establishing the diagnosis of neoplasm. (2) A cyst cannot be differentiated from carcinoma by pyelographic evidence alone, and therefore an operation usually was necessary to confirm the diagnosis. (3) When the mass proved to be malignant, extensive manipulation and exposure of the tumor was sometimes necessary before the diagnosis could be established and the renal pedicle secured. Undoubtedly, tumor cells were excessively disseminated into the bloodstream in many of these cases. (4) When exposure of the kidney revealed no obvious neoplasm, either the kidney was widely opened and biopsied, or removed entirely. Normal kidneys often were thus unnecessarily traumatized or even lost. (5) The presence of hepatic metastases, which profoundly alters prognosis and treatment, could not be readily determined.

Aortography has long been available for better preoperative delineation of the true nature of renal masses,^{1, 2} but relative lack of accuracy³⁻⁶ and not insignificant morbidity⁷⁻⁹ have prevented its routine use in this country in the study of all patients with suspected renal neoplasm.

The problems outlined above have been solved to a large extent by the use of selective renal angiography for diagnosis, and, when neoplasm is found, by definitive operative treatment in the form of radical transperitoneal nephrectomy. Transfemoral selective renal angiography is believed to be far superior to laminagraphy, nephrotomography, renal cystography, or the various types of aortography, for reasons that will be discussed.

MATERIALS AND METHODS

A series of 151 patients with clinical symptoms or signs and definite or suspicious pyelographic evidence of renal mass lesions were studied by selective renal arteriography. The methods of study were similar in all patients. The Seldinger technic was used: a radiopaque polyethylene catheter with a premolded tip was introduced percutaneously through the femoral artery and, under the guidance of image intensification, the catheter was manipulated into each of the renal arteries. Radiographs were obtained after the selective injection of from 4 to 8 ml. of 50 percent diatrizoate sodium into each renal artery, the amount depending upon the size of the renal artery. In all patients, aortography was also performed after pressure injection of 30 ml. of contrast material into the aorta with the catheter tip positioned just above the level of the renal arteries. In 10 patients a second selective injection was made into the renal artery of interest, 30 seconds after the injection of 10 μ g. of epinephrine into that renal artery. By this technic, the tumor-staining or hypervascularity of a tumor is enhanced. Epinephrine produces vasoconstriction of the normal renal arterial bed and has little, if any, effect upon the arteries within the tumor. In 15 patients in whom renal cell carcinoma was diagnosed arteriographically, the catheter was manipulated into the celiac axis, and a celiac arteriogram was made after the injection of 35 ml. of 75 percent diatrizoate sodium.

RESULTS

Of the 151 patients who were studied by selective arteriography for renal mass lesions, 72 were found to have arteriographic evidence of significant renal disease. Forty-six patients had diagnoses of renal cyst on the basis of the arteriographic patterns. Displacement of arteries and lack of a nephrographic pattern form the basis for the diagnosis of cyst. Twenty-seven of these patients underwent operation. In one patient, whose diagnosis of an avascular mass was made arteriographically, surgical exploration revealed an adenocarcinoma metastatic from the lung, involving the superior pole of the left kidney, the pancreas, and the retroperitoneal space.

Twenty-six patients had diagnoses of renal cell carcinoma. In every patient the diagnosis was confirmed at operation. Multiple arteries supplied seven of these kidneys.

DISCUSSION

Early diagnosis. In many patients the diagnosis of renal neoplasm is suspected, but the pyelographic evidence is either equivocal or lacking (*Fig. 1 A and B*). To wait until unequivocal pyelographic deformity develops may result in a small tumor that has grown beyond the limits of curability (*Fig. 1 C and D*). In a case of an equivocal or negative pyelogram, renal angiography can establish the diagnosis immediately and give the patient a much

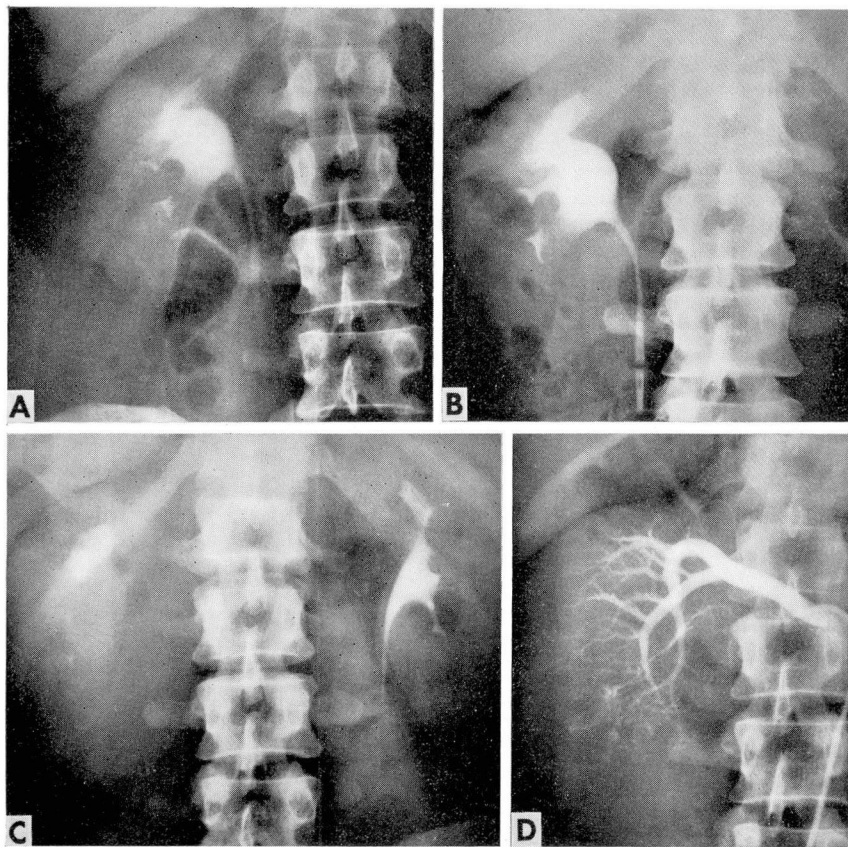


Fig. 1. A, intravenous pyelogram, interpreted as probably normal, of a young man with gross hematuria. B, retrograde pyelogram performed two months after A, when hematuria persisted. Lower pole calyces are not filled completely, but evidence was believed to be not sufficiently diagnostic to warrant operative intervention. C, intravenous pyelogram six months after B, showing obvious right tumor deformity. D, selective renal angiogram showing extensive replacement of the right kidney by renal cell carcinoma. Had this study been performed when the patient was originally examined, the diagnosis might have been made much earlier and afforded the patient a better chance of cure.

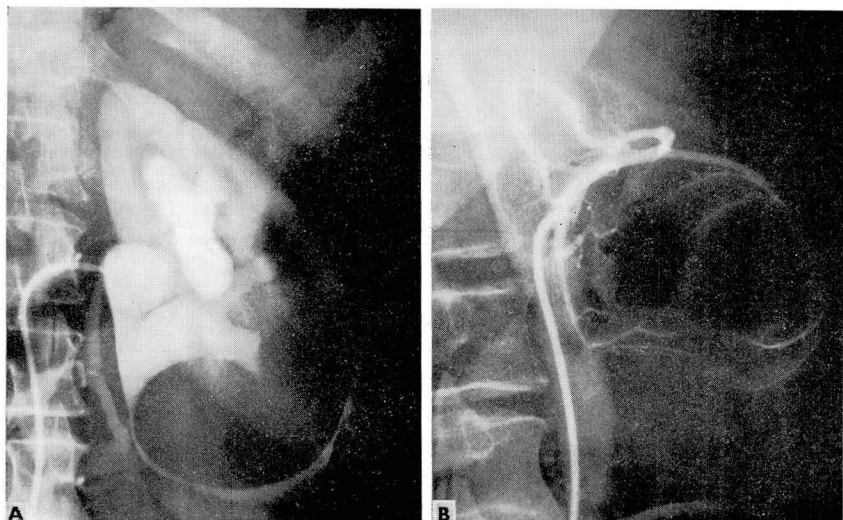


Fig. 2. A, retrograde pyelogram demonstrating tumor deformity stretching and deforming the lower pole infundibulum and producing obstruction of the caliceal system. B, selective renal angiogram showing typical displacement of renal vessels by an avascular cyst.

better chance for ultimate survival. In addition, the patient with a normal renal angiogram can be spared an unnecessary operation with its associated morbidity and possible loss of renal function.

Differential diagnosis. Cyst versus carcinoma. Differentiation between hypernephroma and renal cyst is important, since the ideal therapeutic approach to each of the two conditions is entirely different. If a cyst is demonstrated (Fig. 2 A and B, and Fig. 3 A), it is usually explored through a small incision in the flank; the cyst is then unroofed, biopsied, and drained (Fig. 3 B). Poor-risk patients need not be operated upon at all, and may be followed conservatively. The incidence of neoplasm within renal cysts is extremely low,¹⁰⁻¹² and when the operative risk is thought to exceed the probability of neoplasm, obviously it is better for the patient to be treated conservatively. To date, none of the patients in this series with an angiographic diagnosis of renal cyst have subsequently returned with evidence of neoplasm.

When the renal angiogram indicates the presence of renal cell carcinoma (Fig. 4 A and B, and 5 A and B), the preferred operation is radical transperitoneal nephrectomy performed as follows. Both rectus muscles are transected, and the ipsilateral eleventh rib is also resected when necessary in extremely large or high-lying tumors (Fig. 6 A and B). Excellent exposure is obtained without entering the chest. The renal artery and vein are isolated and ligated *first*, before the tumor mass itself is manipulated (Fig. 6 C). Prior knowledge of the patient's individual arterial anatomy, obtained from

arteriography, greatly facilitates this dissection. The kidney, within its surrounding fascial envelope and peritoneal covering, is then removed en bloc without ever exposing the tumor itself. A regional lymph node dissection can then be performed, removing the paraaortic and paracaval lymph nodes to the level of the crura of the diaphragm. Should tumor have invaded the renal vein, it can be removed and the vena cava easily repaired under direct vision. It is believed that this technic is distinctly superior to the conventional flank approach, where the tumor must be excessively manipulated before its vascular supply is isolated, and where exposure of the pedicle is often difficult because of the cumbersome tumor mass. All of the 26 patients in this series who underwent operative exploration because of arteriographic diagnoses of renal cell carcinoma, were proved to harbor this disease. The renal arteriogram has thus been 100 percent accurate in this respect.

Robson¹³ has clearly shown the superiority of radical versus simple nephrectomy in regard to overall survival rates, and its superiority is even more striking in cases where the renal vein is invaded by tumor. It is believed that the combination of early angiographic diagnosis and radical nephrectomy will improve the survival rate even further of patients with renal cell carcinoma.

Renal cell carcinoma versus transitional cell carcinoma of the renal pelvis. Occasionally a patient has gross hematuria and the pyelogram reveals

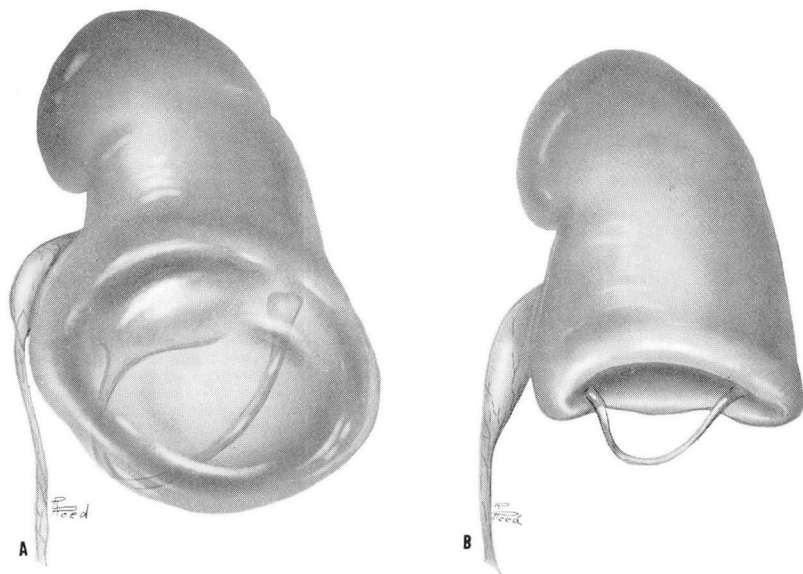


Fig. 3. Schematic representations of the renal cyst demonstrated in Figure 2. A, note unusual compression and attenuation of the lower pole of the infundibulum caused by the cyst. B, extrarenal portion of the cyst wall was excised through a small incision in the flank, decompressing the obstructed upper urinary tract.

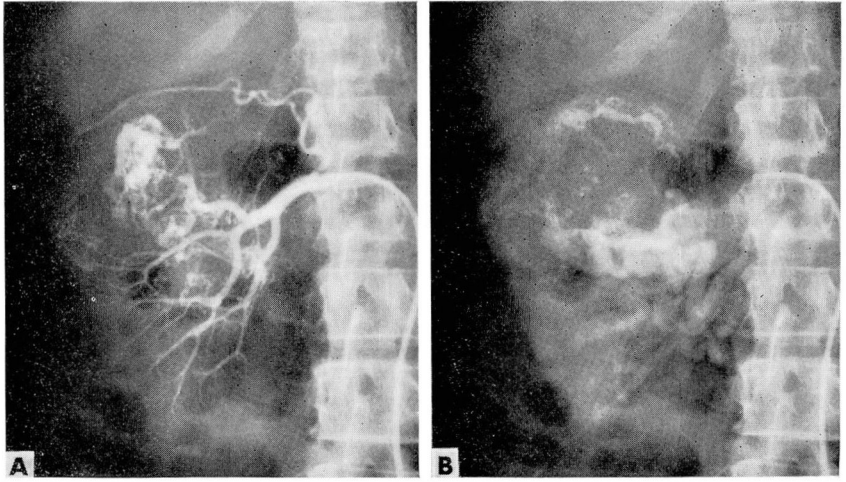


Fig. 4. Renal angiograms demonstrating typical pattern of renal cell carcinoma. A, early vascular injection phase, demonstrating "tumor stain" from numerous small arteriovenous fistulas within the neoplasm. B, nephrogram phase, demonstrating large venous sinuses draining the neoplasm.

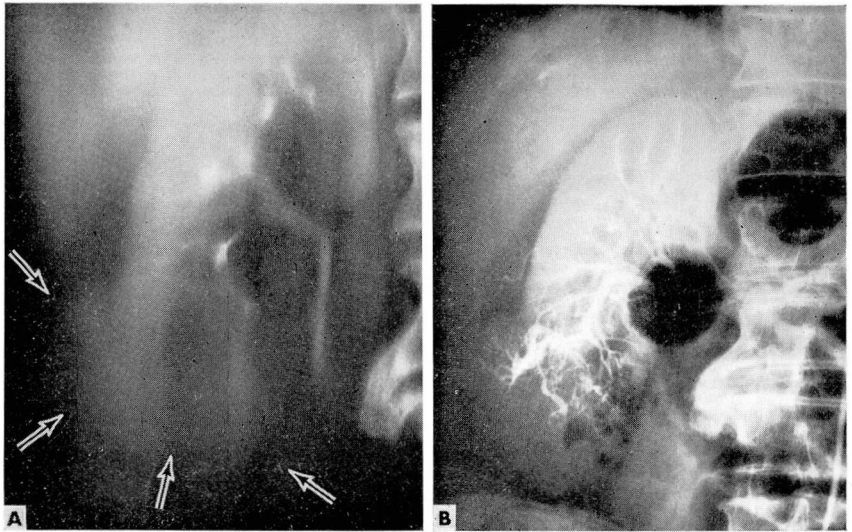


Fig. 5. A, intravenous urogram (laminagraphic view) demonstrates smooth contour of tumor deformity arising from the lower pole of the right kidney. The radiographic diagnosis was that of a probable cyst. B, renal angiogram demonstrates a typical renal cell carcinoma arising from the lower pole of the right kidney. The diagnostic value of an angiogram is demonstrated here, as all clinical evidence favored a diagnosis of simple renal cyst.

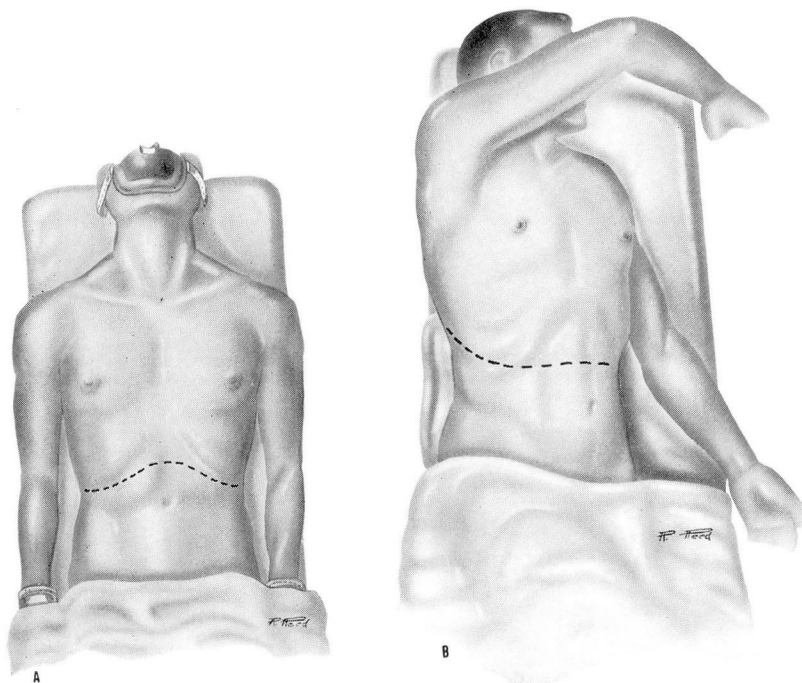


Fig. 6. Sketches of the technic of radical transperitoneal nephrectomy. A, standard transverse upper abdominal incision, transecting both rectus muscles and giving excellent exposure of the aorta, the vena cava, and renal vessels. B, modification of the standard incision extending along the course of the eleventh rib which is partially resected, giving better exposure in particularly large tumors involving the upper aspect of the kidney. C (next page).

multiple filling defects in the renal pelvis (*Fig. 7 A*). These defects may represent nonopaque calculi or blood clots, but also may be due to transitional cell carcinoma involving the renal pelvis or calices. A waiting period of two or three weeks, followed by another pyelographic study has been a form of management advised in the past. If the defects are due to blood clots, they usually disappear as lysis of the clots takes place, whereas defects from stones or papillary tumors will persist. Even so, this still leaves the exact source of the original bleeding in doubt in most cases.

A selective renal angiogram should be performed promptly in such cases, since treatment will vary greatly with the angiographic diagnosis. When the renal angiogram demonstrates a typical renal cell carcinoma (*Fig. 7 B*) as the source of the bleeding, radical transperitoneal nephrectomy should be performed. On the other hand, when the angiographic pattern indicates carcinoma of the renal pelvis (*Fig. 8 A and B*), retroperitoneal nephroureterectomy, utilizing an entirely different operative approach, is the treatment of

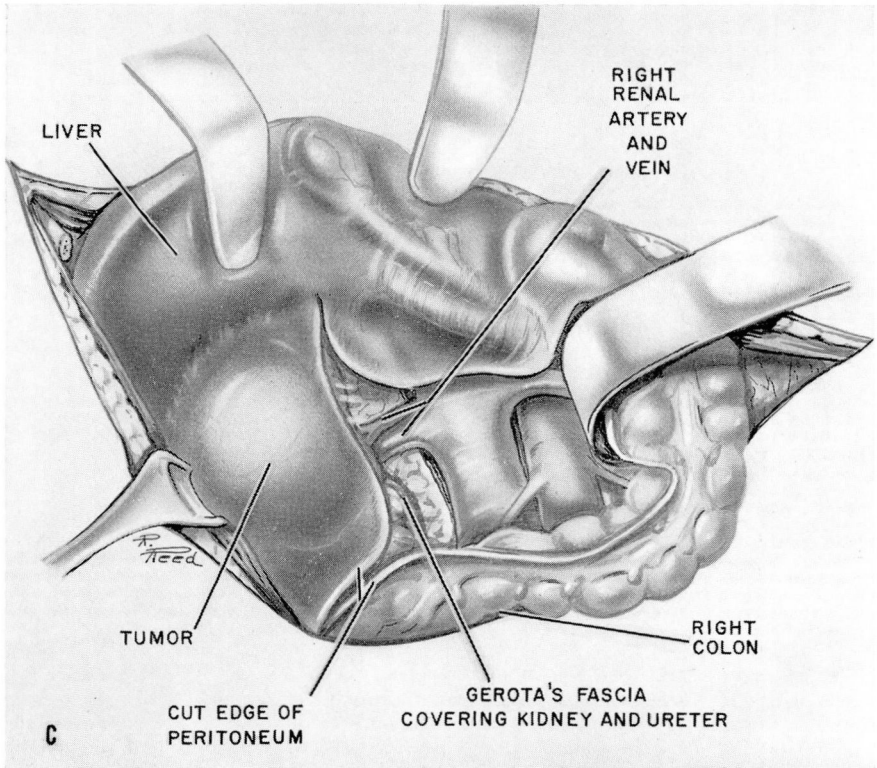


Fig. 6. C, exposure of the right renal artery and vein after medial reflection of the colon, permitting the blood supply of the kidney to be interrupted and the entire kidney removed within its fascial envelopes without exposure or manipulation of the tumor itself.

choice. Should the angiogram fail to demonstrate tumor vessels, and should the filling defects persist, a conservative flank approach with exploration of the renal pelvis is then indicated. When stones within the pelvis are palpable, they can be removed. When no stones are palpable the pelvis is carefully opened; the exact nature of the lesion is clarified; and an appropriate operation is then performed.

Multiple renal arteries. The kidney harboring neoplasm may be supplied with several renal arteries (Fig. 9 A and B), as occurred in six of seven patients in our series. The presence of this anomaly could be of tremendous practical value in a patient with a solitary kidney, where segmental nephrectomy might not only be technically feasible but offer a reasonable chance for cure. Furthermore, in regard to all patients who undergo radical nephrectomy because of renal cell carcinoma, prior knowledge of the vascular anatomy is of great value to the surgeon in performing the operation safely with a minimum loss of blood.

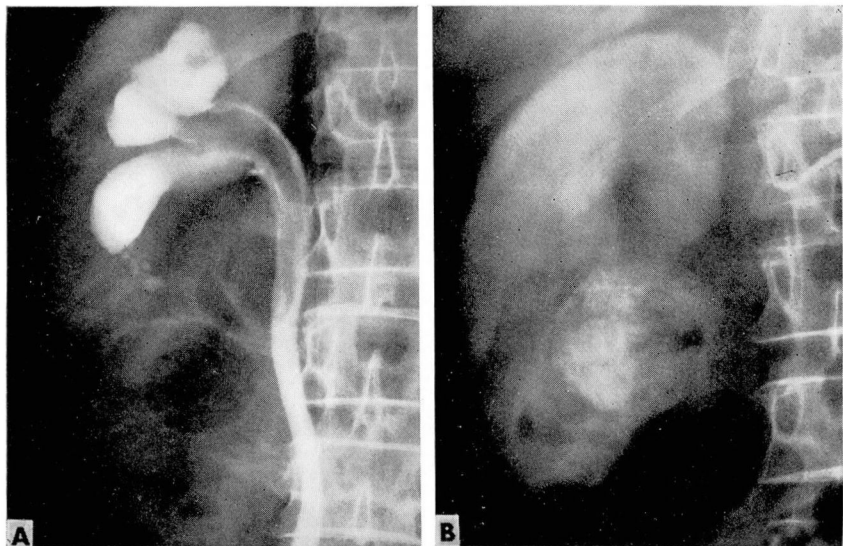


Fig. 7. A, retrograde pyelogram of a patient with gross hematuria demonstrates multiple filling defects in the right renal pelvis. B, renal angiogram reveals typical renal cell carcinoma affecting the lower pole of the right kidney and producing blood clots in the renal pelvis. Based on the angiographic diagnosis, immediate radical transperitoneal nephrectomy was performed.

Demonstration of disseminated neoplasm. Another advantage made possible by transfemoral angiography is the demonstration of disseminated neoplasm. Neoplasm involving the contralateral kidney may occasionally be revealed (Fig. 10 A and B), obviously altering the prognosis and treatment. In addition, in all patients in whom a malignant tumor is demonstrated by conventional selective renal angiography, the catheter is then advanced into the celiac axis, and subsequent visualization of the hepatic vasculature is accomplished. The angiograms may demonstrate the presence of hepatic metastases, which again greatly alters the therapeutic approach. These radiographic techniques, therefore, can be of considerable practical value.

Technic. The requirement for *selective* renal angiography rather than direct aortographic techniques for diagnosis of renal cell tumors should be emphasized. For visualization of the renal arterial tree by aortographic techniques, the contrast material, deposited in the aorta, must be carried into the renal circulation by the movement of the bloodstream. As a consequence of the deposition of contrast material in the aortic stream, immediate dilution of the agent occurs, so that the contrast material upon reaching the peripheral renal bed is often considerably diluted. Dilution of the agent results in loss of contrast on the radiograph. Since definition or resolving power is intimately related to photographic contrast, any loss that is due to dilution by

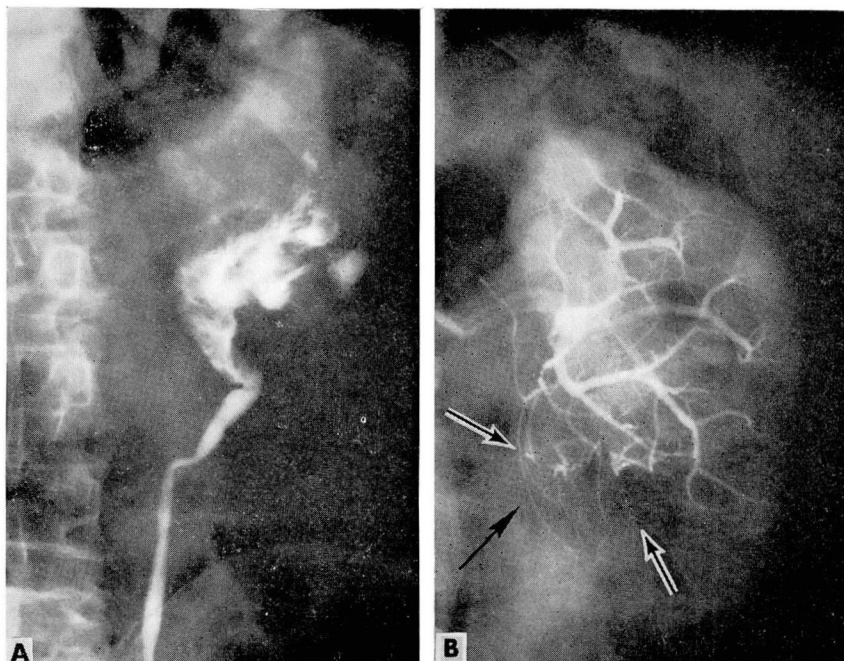


Fig. 8. A, retrograde pyelogram of another patient with gross hematuria demonstrates multiple filling defects in the left renal pelvis. Pyelographic findings were similar to those described in *Figure 7*. B, renal angiogram demonstrates small "tumor vessels" supplying carcinoma of the renal pelvis. Hypernephroma was ruled out as a source of bleeding, and retroperitoneal nephroureterectomy was therefore recommended and performed. The operative approach was dependent upon angiographic diagnosis.

blood, limits the ability of the observer to define the smaller vessels of the renal arterial bed. In the present series, it has been repeatedly observed that the diagnosis of tumor was possible only because of visualization of the renal artery branches of diameters of 1.0 mm. or less. This degree of visualization is often beyond the capability of aortographic technics.

Furthermore, selective opacification of the renal arteries in the patient who has more than one artery supplying the kidney, has revealed that the arterial supply of a renal cell carcinoma is usually derived from only one of the vessels. The surgical implications of such a finding have been discussed. By aortographic technics, it would not be possible to determine whether a tumor was receiving its blood supply totally from one artery or from multiple arteries.

Limitations. The limitations of selective renal angiography are few, and consist primarily of the need for special radiographic equipment and experienced physicians to perform the examination. Strict adherence to prin-

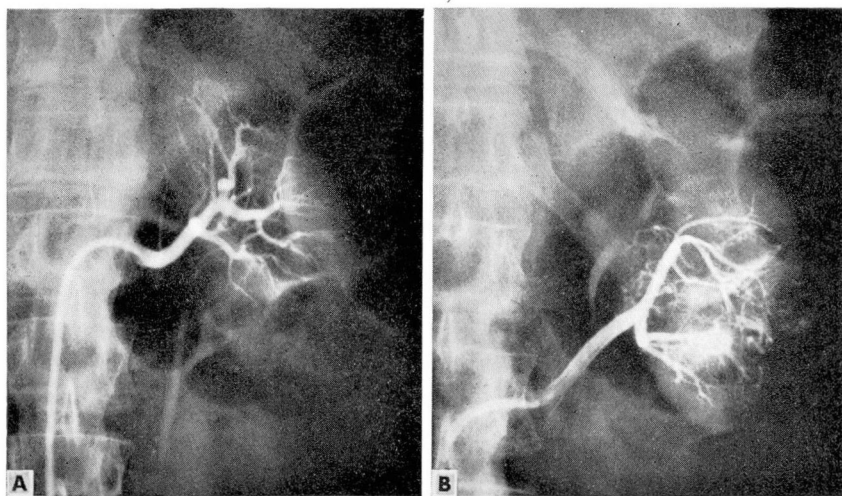


Fig. 9. Renal angiograms show hypernephroma present in a kidney supplied by multiple renal arteries. A, normal renal artery to the upper pole of the right kidney is entirely free of neoplasm. B, a second renal artery, to the lower pole of the right kidney, demonstrates extensive "tumor stain" typical of renal cell carcinoma. The operative removal of such a kidney is greatly facilitated by prior knowledge of the patient's individual vascular anatomy.

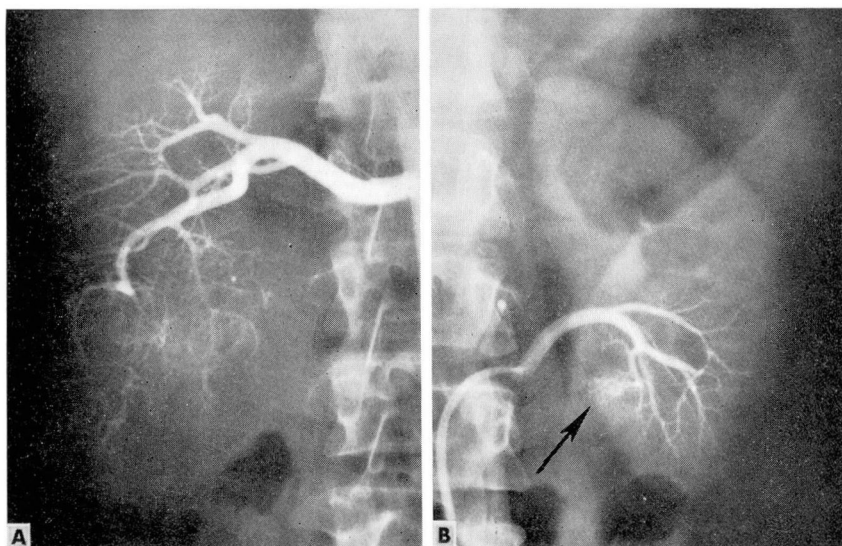


Fig. 10. Bilateral renal cell carcinoma demonstrated by selective renal angiography. A, arteriographic phase, demonstrates a large renal cell carcinoma affecting the right kidney. B, selective arterial injection of the lower polar artery of the left kidney demonstrates a small area of "tumor stain" (arrow). Remainder of the kidney was supplied by two other arteries, which were free of neoplasm.

ciples of technic, and a certain amount of skill on the part of the physician performing the examination are absolutely essential if excellent films are to be obtained with a minimum of morbidity to the patient. It is hoped that, as training programs in angiographic methods improve, these limitations in applicability of the method will be corrected and that the technic will therefore become more widely available.

SUMMARY AND CONCLUSIONS

Transfemoral selective renal angiography performed by experienced personnel is a safe and reliable method of determining the presence and nature of renal-mass lesions.

Selective renal angiography is helpful in detecting the presence of small renal neoplasms in patients in whom other radiographic studies may be equivocal, thus leading to earlier operation and better survival rates of patients with malignant renal disease.

The differential diagnosis among renal cell carcinoma, transitional cell carcinoma of the renal pelvis, and simple renal cyst can be made with a high degree of accuracy utilizing selective renal angiography. This differentiation is extremely important, since renal cell carcinoma should be treated by radical transperitoneal nephrectomy, and renal pelvic carcinoma by retroperitoneal nephroureterectomy; whereas cysts may be explored through a small incision in the flank or in some cases may be treated conservatively without operation.

Selective renal angiography is of tremendous help to the surgeon in better defining the renal vascular anatomy and in determining the presence or absence of disseminated neoplasm, which in turn can profoundly alter the therapeutic approach in a specific patient.

REFERENCES

1. dos Santos, R.; Lamas, A., and Pereira Caldas, J.: L'artériographie des membres de l'aorte et de ses branches abdominales. *Bull. et mém. Soc. nat. de chir.* 55: 587-601, 1929.
2. Evans, A. T.: Renal cancer: translumbar arteriography for its recognition. *Radiology* 69: 657-663, 1957.
3. Creevy, C. D., and Price, W. E.: Differentiation of renal cysts from neoplasms by abdominal aortography: pitfalls. *Radiology* 64: 831-839, 1955.
4. Nesbitt, T. E.: A criticism of renal angiography. *Am. J. Roentgenol.* 73: 574-583, 1955.
5. Lasser, E. C., and Staubitz, W. J.: Translumbar aortography in urologic diagnosis: limitations and possible pitfalls. *J.A.M.A.* 163: 1325-1329, 1957.
6. Uson, A. C.; Melicow, M. M., and Lattimer, J. K.: Is renal angiography (aortography) a reliable test in the differential diagnosis between kidney cysts and neoplasms? *J. Urol.* 89: 554-558, 1963.
7. McAfee, J. G.: A survey of complications of abdominal aortography. *Radiology* 68: 825-838, 1957.

DIAGNOSIS AND TREATMENT OF RENAL NEOPLASM

8. Kincaid, O. W., and Davis, G. D.: Abdominal aortography (concluded). *New England J. Med.* **259**: 1067-1073, 1958.
9. Lang, E. K.: A survey of the complications of percutaneous retrograde arteriography: Seldinger technic. *Radiology* **81**: 257-263, 1963.
10. Gibson, T. E.: Interrelationship of renal cysts and tumors: report of three cases. *J. Urol.* **71**: 241-252, 1954.
11. Brannan, W.; Miller, W., and Crisler, M.: Coexistence of renal neoplasms and renal cysts. *South. M. J.* **55**: 749-752, 1962.
12. Emmett, J. L.; Levine, S. R., and Woolner, L. B.: Co-existence of renal cyst and tumour: incidence in 1,007 cases. *Brit. J. Urol.* **35**: 403-410, 1963.
13. Robson, C. J.: Radical nephrectomy for renal cell carcinoma. *J. Urol.* **89**: 37-42, 1963.