

Angiographic diagnosis of carcinoma of the cecum

REPORT OF A CASE

THOMAS F. MEANEY, M.D.,
Department of Hospital Radiology

CHARLES H. BROWN, M.D.,
Department of Gastroenterology

ROBERT E. HERMANN, M.D., AND
CALDWELL B. ESSELSTYN, M.D.*
Department of General Surgery

SELECTIVE angiography has proved to be useful in the diagnosis of intraabdominal neoplasm, particularly tumors of the pancreas, stomach, and liver.¹⁻⁴ The procedure also has been helpful in diagnosing tumors of the small and large intestine and their mesenteries. Angiography has often been used for investigation of a known disease process or abdominal mass. However, because of the more simply performed barium studies, angiography is not often considered a practical aid in diagnosing tumors in the small and the large intestine. In the colon, the cecum is most likely to harbor a tumor that escapes detection by conventional examination. In this region, good detail on barium studies is often limited by inadequate cleansing of the intestine or by the emptying of small-bowel contents into the cecum. Often barium enema examinations of the colon are inconclusive although the patients have clinical signs and symptoms strongly suggestive of cecal cancer. Serial barium enema studies finally reveal the presence of a tumor that then can be retrospectively identified, usually smaller in size than that shown on a previous colon examination.

The following case report illustrates a common problem in diagnosis of carcinoma of the cecum which finally was identified by means of selective superior mesenteric arteriography.

REPORT OF A CASE

A 68-year-old woman was first admitted to the Cleveland Clinic Hospital on March 15, 1966, because of persistent nausea, anorexia, and abdominal cramps in the mid abdomen

* Formerly Fellow, Department of General Surgery; present address: 606 Short Ridge Road, Fayetteville, North Carolina.

for the previous two years. During this period she had lost 18 pounds. Coincident with the onset of these symptoms, she acquired new dentures.

On physical examination, the blood pressure was 110/70 mm Hg, pulse rate was 88, temperature 98 F, and weight 112 pounds. Physical findings were limited to the abdomen. The sigmoid colon was palpable and somewhat tender, as was the ascending colon. There were no fixed masses. Results of the proctosigmoidoscopic examination were normal. The referral report indicated that the patient was anemic, and blood hemoglobin values were in the range of 10 g per 100 ml despite therapy with iron, and several guaiac tests of stool specimens were positive. Results of previous radiologic examinations were within normal limits, with the exception of a small sliding hiatal hernia and a small diverticulum of the second portion of the duodenum. Before admission to this institution, four separate barium studies were made between November 1965 and January 1966. A review of these roentgenograms showed only numerous diverticula in the sigmoid colon.

Laboratory examination revealed: blood hemoglobin, 10.5 g per 100 ml; cell volume, 33 ml per 100 ml; leukocyte count, 8,300 per cubic millimeter; a normal differential count; urinalysis, normal; gastric analysis, with betazole hydrochloride as a stimulant, showed 74 units of free hydrochloric acid and a total acidity of 88 per cent. Serum values of alkaline phosphatase, amylase, lipase, and carotene were normal; blood urea value, glucose tolerance test, and sulfobromophthalein test of liver function were all normal; an electrocardiogram showed no diagnostic changes.

Radiologic examinations included a barium enema study of the colon, which had a normal appearance except for multiple diverticulosis in the sigmoid portion. A pancreatic scintigram showed the pancreas to be well defined, with no abnormality.

At this time, the patient was treated symptomatically with sedation, antidepressants, antispasmodics, vitamins, and iron. She was asked to return in two months for further studies.

Two weeks before the patient's scheduled return, on May 14, 1966, she was readmitted to the hospital because of persistent anemia. Blood hemoglobin was 9 g per 100 ml, and results of the general physical examination were essentially as previously recorded. Laboratory studies showed persistent anemia, with a blood hemoglobin value of 10.4 g per 100 ml, a cell volume of 32 ml per 100 ml, and a leukocyte count of 9,000 per cubic millimeter; again, the differential count was normal. Serum values of amylase, glutamic oxaloacetic transaminase (SGOT), bilirubin, alkaline phosphatase, electrolytes, and electrophoretic protein pattern, as well as values for blood urea and serum protein-bound iodine, results of a sulfobromophthalein liver function test, and the prothrombin time, again were all normal.

At this time, additional radiologic studies were carried out, including examination of the esophagus, stomach, duodenum, and chest. All results were within normal limits.

Selective celiac and mesenteric arteriography was performed in an attempt to find a hidden malignant process that had escaped detection by the conventional radiologic studies. A medium-sized preformed radiopaque catheter was introduced percutaneously into the femoral artery according to the Seldinger⁶ technic. With image-intensification fluoroscopy, the catheter was manipulated into the celiac and superior mesenteric arteries. The selective opacification of the celiac artery revealed no abnormality. The superior mesenteric artery was catheterized and opacified and was shown to be normal at its origin. However, the ileocecal branch was larger than usual and its distribution revealed numerous arteriovenous shunts in the cecal area (*Fig. 1*), with rapid flow of contrast material into the venous drainage of the cecum (*Fig. 2*), and opacification of the draining tributary of the superior mesenteric vein (*Fig. 3*). The angiographic evidence was that of a malignant tumor in the cecum.

On May 20, 1966, the patient underwent operation and a large tumor of the cecum was found (*Fig. 4*). The colon on the right side and the terminal ileum were resected and an ileocolic anastomosis was performed. The excised specimen revealed adenocarcinoma of the cecum, moderately differentiated, grade 3. The proximal and distal lines of the resection were free of the tumor, and no secondary carcinoma was present in the lymph nodes (none of six). The tumor extended no more than 3.0 mm into the pericecal fat. The patient made a satisfactory recovery and was discharged from the hospital on May 30, 1966.

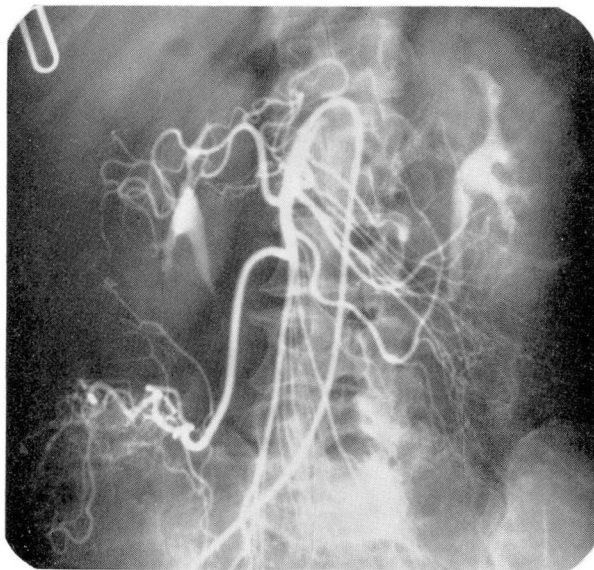


Fig. 1. Early arterial phase of the selective opacification of the superior mesenteric artery. The branches of the ileocolic artery filled more rapidly than the other branches of the superior mesenteric artery.

DISCUSSION

It is generally conceded, although difficult to prove statistically, that the earlier the diagnosis of carcinoma can be made, the more likely it will be that the lesion will be resectable for cure. The period of time from the onset of a cancer of the colon until the diagnosis can be made is difficult to judge. In their study of 3,763 cases of cancer of the colon or rectum, Welch and Burke⁶ estimated that the median delay, before treatment, decreased from approximately eight months in 1937, to three months in 1959. During the last 20 years, the percentage of all tumors that could be resected for cure increased; correspondingly, there was also an increase in the percentage of resected tumors that did not have lymph node metastases. When intestinal symptoms exist, physicians have become increasingly suspicious of malignant disease. Diagnostic examinations that include stool guaiac studies, sigmoidoscopy, and barium enema roentgen examinations have made it possible to diagnose cancer of the colon more frequently at a curable stage.

As stated previously, one of the most difficult carcinomas to identify at an early stage is that arising in the cecum, a part of the colon which continues to be difficult to examine adequately and to visualize on barium enema roentgen studies. Early lesions affecting only mucosa are difficult to see, and

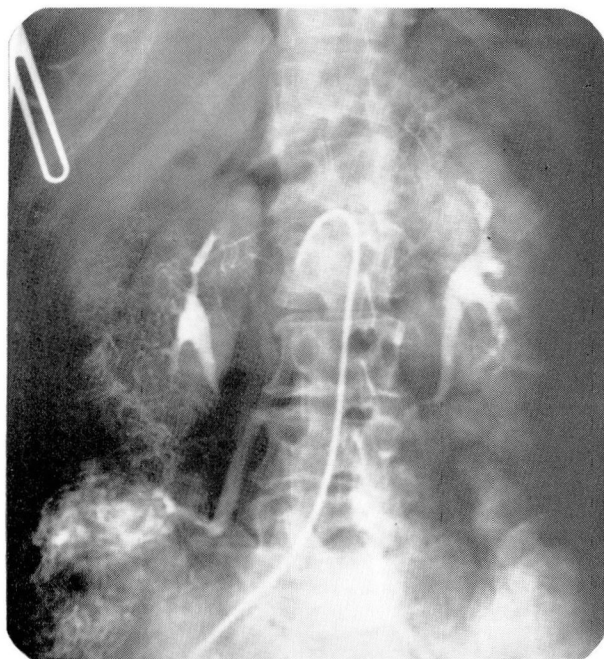


Fig. 2. Late arterial phase showing hypervascularity in the cecal area and pooling of the contrast material in the tumor. The ileocolic vein was opacified before other tributaries of the superior mesenteric vein.

large bulky lesions arising posteriorly are easily missed. Air-contrast barium studies have contributed to earlier diagnosis of cancer in this area, but many lesions are still not demonstrated in their initial stages. In the case we are reporting the carcinoma was a flat, plaquelike lesion on the posterior wall of the cecum, with minimal encroachment of the lesion into the lumen of the bowel.

The detection of a large cecal carcinoma by arteriographic examination was particularly noteworthy in this patient on whom five previous barium enema examinations had been performed because of suspected cecal carcinoma. The patient's symptoms of nausea, poor appetite, and inability to sleep were more suggestive of a gastric or pancreatic lesion than of cecal carcinoma. The persistent anemia, despite vitamin and iron therapy, and the mid abdominal cramping were the only symptoms suggestive of a tumor of the colon.

The role of arteriography in the diagnosis of malignant tumors of the brain, kidneys, and soft tissues has been clearly established, and more recently its usefulness in the detection of neoplasms in the stomach, liver,

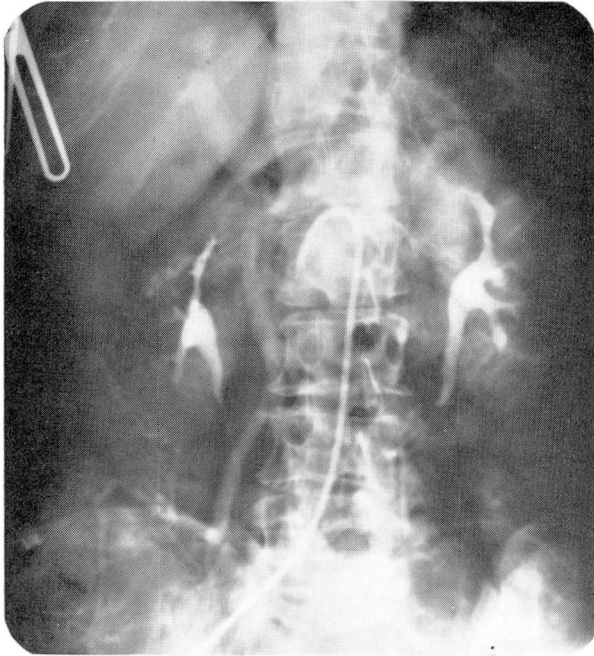


Fig. 3. Venous phase demonstrating persistent venous opacification in the tumor and the ileocolic vein. The portal vein is also defined.

and pancreas has found increasing value. However, as stated, the technic has not been generally applied to detection of tumors of the small and large intestine. In all areas studied arteriographically, the findings of malignancy are identical. In the cases of vascular malignant tumors, there is abnormal perforation of small arteries, producing a hypervascular pattern that is associated with arteriovenous shunting within the tumor (so-called tumor-staining). The establishment of the technic of selective arteriography that permits the introduction of contrast material into the branches of the abdominal aorta has resulted in a high degree of definition of the smaller vessels associated with tumors.

In spite of the difficulty in early diagnosis of these lesions, carcinoma of the cecum and carcinoma of the ascending colon remain relatively favorable lesions. The tumors may be sessile or polypoid; they frequently ulcerate and bleed; yet they tend to metastasize late. In the patient whose case is presented, despite the two-year duration of symptoms, no lymph nodes were found to be affected by tumor. The lymphatic drainage system of the colon on the right side is susceptible to wide resection, with control of any localized tumor and its regional metastases. The surgical removal of car-

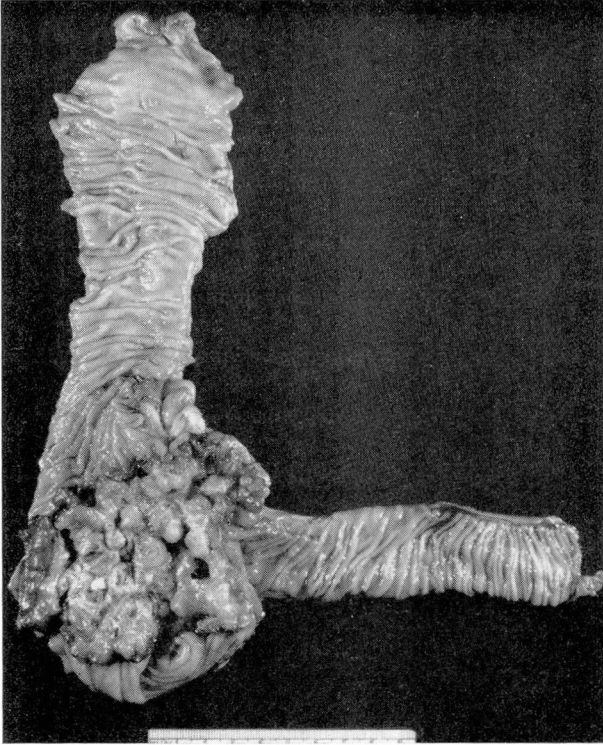


Fig. 4. Photograph of the excised surgical specimen of the distal portion of the ileum and the right side of the colon, showing a large tumor affecting the posterior wall of the cecum.

cinomas of the cecum and ascending colon should include resection of the distal 10 cm of ileum, the entire ascending colon, and the right half of the transverse colon. Ancillary technics such as preliminary interruption of the arterial supply and lymphatics, and venous drainage with isolation and division of the involved bowel segment proximal and distal to the lesion before mobilization have contributed to an increase in five-year survivals. The most fruitful areas for further advances continue to be those of earlier diagnosis of the disease.

CONCLUSION

A case report of a patient in whom a carcinoma of the cecum was diagnosed by selective superior mesenteric angiography is presented. Five prior barium enema examinations failed to make possible the detection of the tumor. The angiographic findings consisted of hypervascularity of the neoplasm, arteriovenous shunts, and rapid opacification of the venous drainage.

ANGIOGRAPHIC DIAGNOSIS OF CARCINOMA OF THE CECUM

The tumor was successfully resected and no evidence of metastatic disease was found.

REFERENCES

1. Meaney, T. F.; Winkleman, E. I.; Sullivan, B. H., and Brown, C. H.: Selective splanchnic arteriography in diagnosis of pancreatic tumors. *Cleveland Clin. Quart.* **30**: 193-197, 1963.
2. Meaney, T. F., and Buonocore, E.: Arteriographic manifestations of pancreatic neoplasm. *Am. J. Roentgenol.* **95**: 720-726, 1965.
3. Lunderquist, A.: Angiography in carcinoma of the pancreas. *Acta radiol. suppl.* **235**: 1-143, 1965.
4. Ödman, P.: Percutaneous selective angiography of the coeliac artery. *Acta radiol. suppl.* **159**: 1-168, 1958.
5. Seldinger, S. I.: Catheter replacement of the needle in percutaneous arteriography; a new technique. *Acta radiol.* **39**: 368-376, 1953.
6. Welch, C. E., and Burke, J. F.: Carcinoma of the colon and rectum. *New England J. Med.* **266**: 211-219, 1962.