

Treatment of lupoid hepatitis with azathioprine*

REPORT OF A CASE

HIRSCH RASTOGI, M.D.,†

Department of Gastroenterology

SHARAD D. DEODHAR, M.D., PH.D.,

Division of Pathology

CHARLES H. BROWN, M.D.

Department of Gastroenterology

LUPOID HEPATITIS, a well-recognized entity affecting only young women, is characterized clinically by persistent hepatitis with or without jaundice, recurrent arthritis, dermatitis, and splenomegaly. Histologically, there is parenchymatous infiltration of plasma cells and lymphocytes with various degrees and patterns of hepatic fibrosis. Serologically, there is a great elevation of γ -globulins and the presence of antinuclear and other autoantibodies in the blood. The prognosis in patients with lupoid hepatitis is usually poor, since relentless progression to chronic hepatic disease with subsequent portal hypertension and hepatic failure occurs despite treatment. The features of this disease suggest that lupoid hepatitis is an autoimmune disease.

The possible beneficial results of corticosteroid treatment are thought to be due to their antiinflammatory and immunosuppressive effects, the latter being attributed to inhibition of lymphoid tissue, which is presumably the site of development and proliferation of the forbidden clones responsible for the production of autoantibodies. The use of cytotoxic drugs, because of their immunosuppressive reactions, was suggested by Dameshek and Schwartz¹ in 1960 for the management of autoimmune disorders. Alkylating agents and antimetabolites have since been used with variable success in several disease states such as rheumatoid arthritis,^{2, 3} systemic lupus erythematosus,⁴ lupoid hepatitis,⁵ and chronic ulcerative colitis.⁶ The poor prognosis in lupoid hepatitis⁵ and the strong possibility that it may be based on autoimmunity, justify the use of potent immunosuppressive drugs in treatment.

* *Imuran, Burroughs Wellcome & Co. (U.S.A.) Inc.*

† *Fellow, Department of Gastroenterology.*

Table 1.—*Liver function studies of patient with lupoid hepatitis*

Date	Serum values				Thy- mol tur- bidity test, units (nor- mal, 0-5)	SGOT,* units (normal <40)	BSP† test, mg/100 ml in 45 min- utes (nor- mal, 5-8)	Pro- thrombin time
	Bilirubin, mg/100 ml		Alkaline phos- phatase, King- Armstrong units (normal, 4-14)	Cephalin- choles- terol flocula- tion test (normal, negative)				
	Direct (0.1- 0.4)	Total (0.7- 1.0)						
1965								
November	1.7	5.8	15.8	4 plus/48 hours	22.2	1080	—	14 sec (con- trol, 13)
November	0.7	1.9	11	4 plus/48 hours	—	202	—	—
1966								
January	0.1	0.7	—	—	—	34	—	13 sec (con- trol, 13)
April	0	0.6	—	—	—	36	17	—
July	0.1	0.7	5.3	Negative	1.9	44	7	14 sec (con- trol, 12)
November	0.2	1.2	7.3	Negative	6.3	38	11	13 sec (con- trol, 12)

* Serum glutamic oxaloacetic transaminase.

† Sulfobromophthalein.

The case that we are reporting illustrates some of the outstanding features of lupoid hepatitis and its course under the effect of azathioprine.

REPORT OF A CASE

A 17-year-old schoolgirl was first examined at the Cleveland Clinic, in November 1965, because of recurrent jaundice since December 1964. Two prior episodes of jaundice, associated with anorexia, nausea, and diarrhea, occurred in December 1964 and in July 1965. These had been treated as infectious hepatitis. There was no history of injections, blood transfusions, or ingestion of icterogenic or hepatotoxic drugs. The patient had had no pruritis, purpura, skin lesions, photosensitivity, or arthralgias. Her family history was noncontributory. The patient has a twin sister who, to date, has not experienced any similar illness.

On examination, the patient appeared jaundiced, with scleral icterus. There was no lymph node enlargement. The abdomen felt soft, with no tenderness or organomegaly. The oral temperature was 99 F; pulse rate was 80, and the blood pressure was 126/78 mm Hg.

Laboratory studies revealed the following: blood hemoglobin content, 12.6 gm per 100 ml; cell volume, 38 per 100 ml; leukocyte count, 10,800 cells per cubic millimeter. Urinalysis showed bilirubinuria. The results of the various liver function tests performed are presented chronologically in *Table 1* and those of the immunologic tests in *Table 2*. The heterophil test was positive in a titer of 1:32, and the hepatitis—infectious mononucleosis (HIM) test⁷ in a titer of 1:40. Two LE (lupus erythematosus) tests were negative. The antinuclear factor test was positive, 1:40. The serum protein electrophoretic pattern re-

TREATMENT OF LUPOID HEPATITIS WITH AZATHIOPRINE

Table 2.—*Immunologic studies of patient with lupoid hepatitis*

Determination	1966				
	1965 November	January	April	July	November
Immunoglobulins (mg/100 ml, normal)					
G (500-1500)	4170	4400	3200	1200	1225
A (50-200)	282	400	290	320	230
M (50-150)	148	330	150	185	175
Thyroglobulin antibodies titer	Positive 1:25	—	Positive 1:5	Negative	Negative
Antinuclear factor	Positive 1:40	Positive 1:40	Positive 1:1	Positive 1:1	Negative
Liver antibodies	—	Positive 1:16	—	Positive 1:16	Negative
Smooth-muscle antibody	—	Positive	—	—	Negative
Parietal cell and skeletal-muscle antibodies	—	Negative	—	Negative	Negative
Serologic tests for syphilis					
Kahn	Negative	—	—	—	—
Kolmer's	Positive (1:21,000)	—	—	—	Negative
VDRL	Negative	—	—	—	Negative

vealed a great increase in γ -globulin (*Fig. 1*). Liver biopsies were performed in November 1965 (*Fig. 2*), January 1966, and July 1966 (*Fig. 3*).

Treatment was begun in November 1965, consisting of azathioprine, 150 mg daily, and triamcinolone,* 8 mg daily, and vitamins. Azathioprine is a derivative of 6-mercaptopurine (6-MP). Within a few months there was remarkable clinical improvement that was also reflected in the results of the laboratory studies (*Fig. 1 through 3, and Tables 1 and 2*).

Before initiating therapy, a total leukocyte count was 10,800 cells per cubic millimeter as compared to 5,800 cells per cubic millimeter in July 1966.

The patient reported no untoward symptoms to the therapy. The jaundice regressed; her appetite improved; and she felt well. She undertook more activities than previously in July 1966, without the development of a flare-up of symptoms or jaundice.

IMMUNOLOGIC STUDIES

The quantitative immunoglobulin assay was performed by the method of Fahey and McKelvey.⁸ The materials used in this procedure were obtained from Hyland Laboratories, Los Angeles, California. The antinuclear factor test was performed by the indirect fluorescent technic, with unfixed, normal, human spleen slide imprints as the source of nuclear material, and fluorescent antihuman γ -globulin (Baltimore Biological Laboratories). The parietal cell, smooth-muscle, and skeletal-muscle antibodies were

* *Aristocort, Lederle Laboratories.*

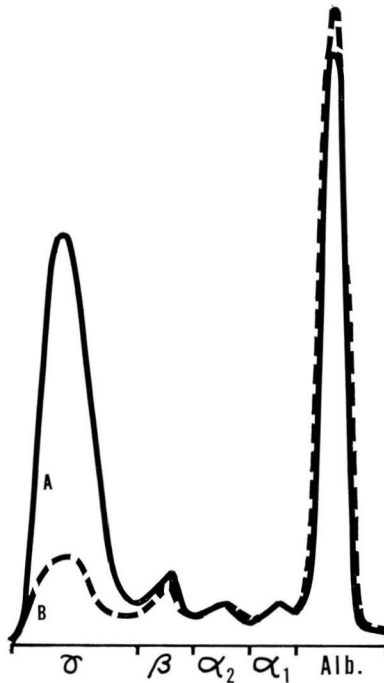


Fig. 1. Serum protein electrophoretic patterns. A, November 1965 (solid line). B, November 1966 (dotted line). Note the decrease in γ -globulin.

investigated also by the indirect immunofluorescent technics.⁹⁻¹¹ Thyroid antibodies and liver antibodies were studied by the tanned red-cell agglutination and complement-fixation technics, respectively.¹²

For immunofluorescent studies, appropriate frozen tissue sections, cut on a cryostat (Lipshaw Co.) at 6- μ thickness, were treated, first with the patient's serum, and then with the fluorescent antihuman γ -globulin. The treated sections were then examined under a fluorescent Zeiss microscope.

LIVER BIOPSY STUDIES

The microscopic appearances of liver biopsy specimens studied at various periods are shown in *Figures 2 and 3*. In the liver biopsy of November 1965 (*Fig. 2*) the portal areas showed a definite lymphocytic infiltrate and there were focal hepatic cell degeneration and necrosis. There was minimal bile stasis in the bile canaliculi and in the parenchymal cells. A moderate degree of fibrosis was present mainly in the portal areas. The inflammatory cell infiltrate consisted mostly of mature lymphocytes, but the plasma cell component typical of lupoid hepatitis was not evident in

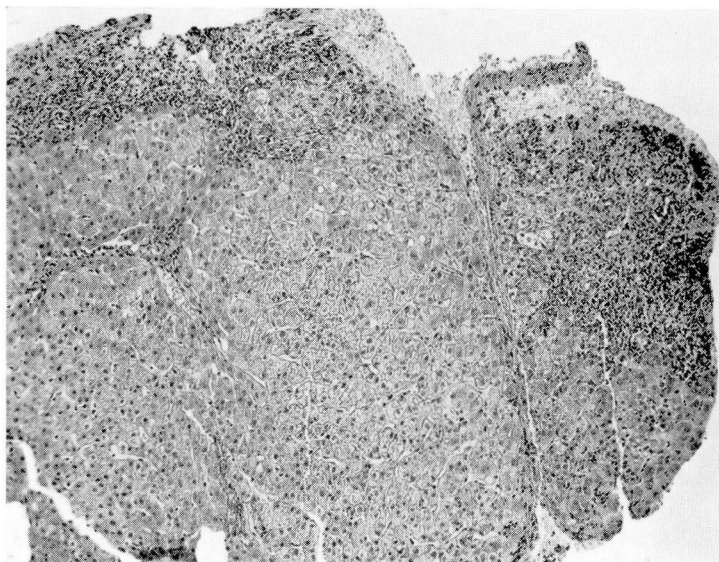


Fig. 2. Liver biopsy section (November 1965), showing active, chronic, portal hepatitis with early cirrhosis. Note the portal lymphocytic infiltrate and fibrosis.

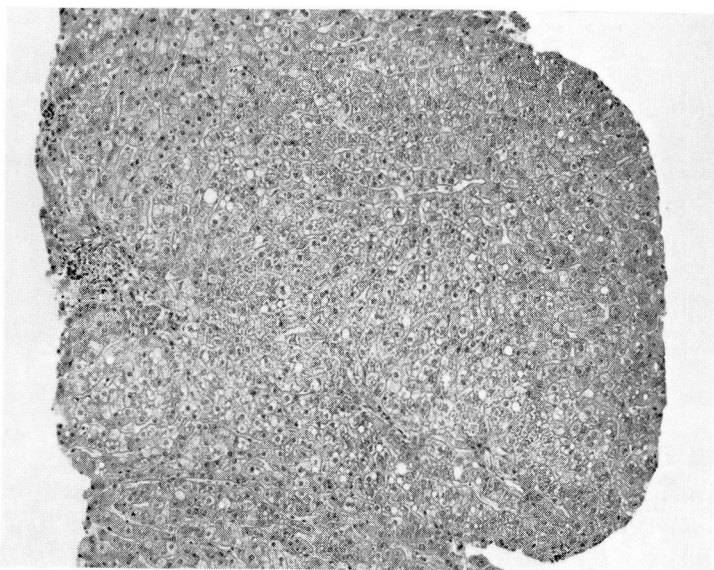


Fig. 3. Liver biopsy section (July 1966) showing morphologic improvement as compared to the biopsy section in *Figure 2*.

any of the sections. The microscopic changes are best characterized as active, chronic, portal hepatitis, with early cirrhosis. In the biopsy specimen of January 1966, the changes were essentially similar to those seen in *Figure 2*. The biopsy specimen taken six months later (*Fig. 3*) showed a notable decrease in the inflammatory cell infiltrate and also a striking regression of all the other changes previously seen.

DISCUSSION

The various clinical and laboratory observations strongly suggested the diagnosis of lupoid hepatitis in this patient. The striking increase in immunoglobulins (IgG) and the presence of antinuclear, hepatic, and, especially, smooth-muscle antibodies, are highly characteristic of lupoid hepatitis. In a recent report by Whittingham and associates,¹⁰ the antinuclear and smooth-muscle antibodies were found in more than 80 percent of the 32 cases of lupoid hepatitis studied by them.

Mackay and Wood⁵ reviewed the progress of 24 patients who had lupoid hepatitis, three of whom also had ulcerative colitis; 12 died. They observed a decrease in the serum transaminase in six of seven patients after courses of azathioprine therapy. The case we report, as well as others reported previously by Mackay and Wood,⁵ confirm the efficacy of azathioprine in the therapy of autoimmune diseases. Mackay and Wood surmised that lymphoid cells active in immune phenomena stimulate malignant lymphoid cells in their vulnerability to antimetabolites. Untoward reactions such as anorexia, nausea, vomiting, and diarrhea, decrease in the number of leukocytes, and hyperbilirubinemia often associated with these drugs, did not develop in the patient we treated. Clinical remission concomitant with improvement in the histologic patterns, and reduction in IgG, with disappearance of antinuclear, liver, smooth-muscle and thyroid antibodies, places antimetabolite therapy on a firm rationale in the control of lupoid hepatitis. This disease usually pursues a relentless course to cirrhosis and its attendant complications.

The patient we treated has been on a course of low-dosage steroid therapy as well, just as were the patients in other cases reported. However, we believe this therapy by itself to be insufficient to reverse the pathologic changes, much less to produce any evidence of hypercortisolemia. We have not observed that the pathologic progress reversed in other cases of lupoid hepatitis treated solely with steroids even in large doses. Prednisolone acetate alone did not ameliorate symptoms or effect improvement in patients reported by Mackay and Wood.⁵ Furthermore, there is evidence that cases refractory to steroids have responded to cytotoxic treatment. What, if any, effect steroids alone exert on the course of lupoid hepatitis is, at pres-

ent, a matter of conjecture. It is possible that azathioprine and steroids may act by summation or synergism in inhibiting immunologic injury to tissue by suppression of lymphoid cells destined to form the forbidden clones.

SUMMARY

A young girl with chronic hepatitis was considered to have lupoid hepatitis because of an increase in γ -globulin (mostly IgG) and the presence of antinuclear, smooth-muscle, liver, and thyroid antibodies.

Therapy comprising rest, vitamins, and small doses of cortisone and azathioprine resulted in a complete remission of lupoid hepatitis. Immunoglobulin values have returned to normal; there has been improvement in the morphologic changes in the liver, according to biopsy sections, and the various antibodies are no longer present.

The excellent response in this patient to immunosuppressive treatment suggests that this therapy should be considered for other patients who have lupoid hepatitis.

ACKNOWLEDGMENTS

The authors gratefully acknowledge the competent assistance of Miss Sue Matz, Mrs. Karen Vagianos, and Miss Angela Fantauzzo in performing the immunologic tests in this study.

REFERENCES

1. Dameshek, W., and Schwartz, R.: Treatment of certain "autoimmune" diseases with antimetabolites; a preliminary report. *Tr. A. Am. Physicians* **73**: 113-127, 1960.
2. Jiménez Díaz, C., and others: Treatment of rheumatoid arthritis with nitrogen mustard; preliminary report. *J.A.M.A.* **147**: 1418-1419, 1951.
3. Scherbel, A. L.: I. Intravenous administration of nitrogen mustard alone and with corticotropin for rheumatoid arthritis. *Cleveland Clin. Quart.* **24**: 71-77, 1957.
4. Plaza de los Reyes, M.; Monsalve, J., and Antillo, A.: Dos casos de lupus eritematoso generalizado tratados con mostazas nitrogenadas. [Two cases of generalized lupus erythematosus treated with nitrogen mustard.] *Rev. med. Chile* **80**: 176-179, 1952.
5. Mackay, I. R., and Wood, I. J.: Course and treatment of lupoid hepatitis. *Gastroenterology* **45**: 4-13, 1963.
6. Winkelman, E. I., and Brown, C. H.: Nitrogen mustard in the treatment of ulcerative colitis and regional enteritis; a preliminary report. *Cleveland Clin. Quart.* **32**: 165-174, 1965.
7. Weaver, D. R.; King, J. W., and Brown, C. H.: The hepatitis-infectious mononucleosis (HIM) test: a clinical evaluation. *Cleveland Clin. Quart.* **33**: 153-161, 1966.
8. Fahey, J. L., and McKelvey, E. M.: Quantitative determination of serum immunoglobulins in antibody-agar plates. *J. Immunol.* **94**: 84-90, 1965.
9. Taylor, K. B., and others: Autoimmune phenomena in pernicious anaemia: gastric antibodies. *Brit. M. J.* **2**: 1347-1352, 1962.

10. Whittingham, S., and others: Smooth muscle autoantibody in "autoimmune" hepatitis. *Gastroenterology* **51**: 499-505, 1966.
11. Strauss, A. J. L., and others: Immunofluorescence demonstration of a muscle binding, complement-fixing serum globulin fraction in myasthenia gravis. *Proc. Soc. Exper. Biol. & Med.* **105**: 184-191, 1960.
12. Fulthorpe, A. J., and others: A stable sheep cell preparation for detecting thyroglobulin auto-antibodies and its clinical applications. *J. Clin. Path.* **14**: 654-660, 1961.