

Vascular localization of immunoglobulin IgM in a renal homotransplant

REPORT OF A CASE

SHARAD D. DEODHAR, M.D., PH.D.,

KENNETH S. K. TUNG, M.D.*

Division of Pathology

IT is generally accepted that the rejection of renal homografts, in experimental animals and in man, is mediated by cellular rather than humoral immune mechanisms. Thus, immunologically competent cells from the recipient have been demonstrated to be in close contact with the vascular endothelial cells of the donor graft, thereby suggesting their role as graft-rejection cells.¹ The role of humoral antibodies in graft rejection is not so well documented. Recently, the presence of humoral antibodies produced in response to renal transplantation has been demonstrated by various technics.^{2, 3} Immunofluorescent technics have been particularly useful in this respect, and, in most of the studies reported,⁴⁻⁶ the immunoglobulin localized in arterial vessels and glomeruli of the renal homograft has been IgG. We are reporting a case in which the renal homograft showed a striking deposition of the immunoglobulin IgM in the walls of small arteries, suggesting to us a possible role for this immunoglobulin also in the graft rejection reaction. This, to our knowledge, is the first reported example of IgM localization in a renal homograft.

REPORT OF A CASE

Clinical history. A 56-year-old Caucasian man received a renal homotransplant from a cadaver donor on August 2, 1964, because of progressive renal failure of 2½ years' duration. The patient's primary renal disease was chronic pyelonephritis associated with severe hypertension. The blood group of the cadaver donor was AB positive and that of the recipient was A positive. After transplantation, there was a period of oliguria lasting about seven days, after which diuresis commenced and his renal function improved progressively with return of his blood pressure to the normal range. Beginning on the day of the transplantation he was started on an immunosuppressive regimen of azathioprine, 150 mg, and prednisone, 150 mg, daily. The dosages of these drugs were decreased gradually, and during the subsequent 14 months the patient continued with the course of azathioprine (100 mg) and prednisone (75 mg) daily. During this time the patient was sufficiently well so that he resumed his full time work of teaching. On October 8, 1965, he was readmitted to the hospital for severe hematemesis, and possible pneumonia in the left lung. In addition, he showed poor renal function, with a blood urea content of 162 mg per 100 ml, serum creatinine content of 3.6 mg per 100 ml, and urinary protein content of 2.3 g per 24 hours.

* *Fellow, Division of Pathology.*

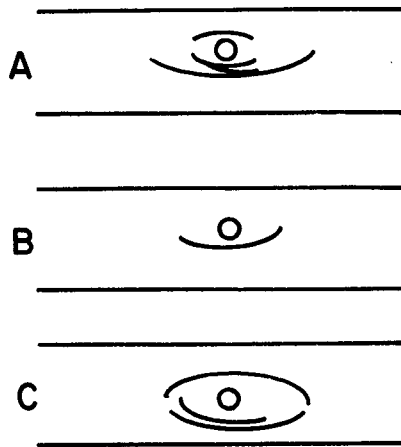


Fig. 1. Drawing of immunoelectrophoretic patterns testing the purity of fluorescent antiserum to IgM. The top troughs in A, B, and C were filled with fluorescent antiserum to IgM, and the bottom troughs with trivalent antiserum to IgG, IgA, and IgM. The center wells were filled with sera as follows: A, normal serum; B, serum from a patient with agammaglobulinemia; C, serum from a patient with macroglobulinemia. Note the single lines with fluorescent antiserum to IgM in A and C, and the absence of any lines in B. The single line in B, with trivalent antiserum, corresponds to that of IgG.

These values were thought to represent active rejection of the renal graft. The patient was given an intravenous injection of actinomycin C, and local irradiation of cobalt⁶⁰ to the renal graft; however, the renal function continued to deteriorate, and he died in uremia (blood urea content was 300 mg per 100 ml) on December 13, 1965, 14½ months after renal transplantation.

Pathologic findings

Materials and methods. At autopsy, blocks of renal tissue were removed, were treated with Zenker's fixative, and were processed according to routine technics. The sections were stained with hematoxylin and eosin and periodic acid-Schiff stains. Methyl green pyronin stain was used after fixation of tissues in absolute alcohol.

For fluorescent studies, fresh frozen renal tissue was cut into sections from 5 to 6 μ thick (on the Lipshaw cryostat microtome), and the sections were treated with fluorescent antisera to human IgG, IgA, IgM, and β_{1C}/β_{1A} components of complement (from Hyland Laboratories, Los Angeles, California). The purity of the various fluorescent antisera, especially that of antiserum to IgM, was tested in the following manner. Immunoelectrophoretic patterns were studied of reactions between fluorescent antiserum of IgM and (1) normal serum, (2) serum from a patient with agammaglobulinemia, and (3) serum from a patient with macroglobulinemia. The results of such studies (Fig. 1), indicated the presence of the single, specific type of antibody in the preparation of the fluorescent antiserum to IgM.

Results. The significant pathologic findings were limited to the renal homograft and the lungs. There was extensive, hemorrhagic, and necrotizing pneumonitis in both lungs, with only scanty inflammatory cellular infiltrate. No bacteria or fungi were found in the lung sections. Several cytomegalic viral inclusion bodies were seen in alveolar cells. The renal homograft weighed 250 g and was moderately edematous. The most striking microscopic changes were in the arterial tree (Fig. 2). At the interlobar artery and the arcuate artery levels there was intimal fibroplasia that had resulted in severe stenosis. Concentric intimal fibroplasia was pronounced in the interlobular and the preglomerular arterioles. In some

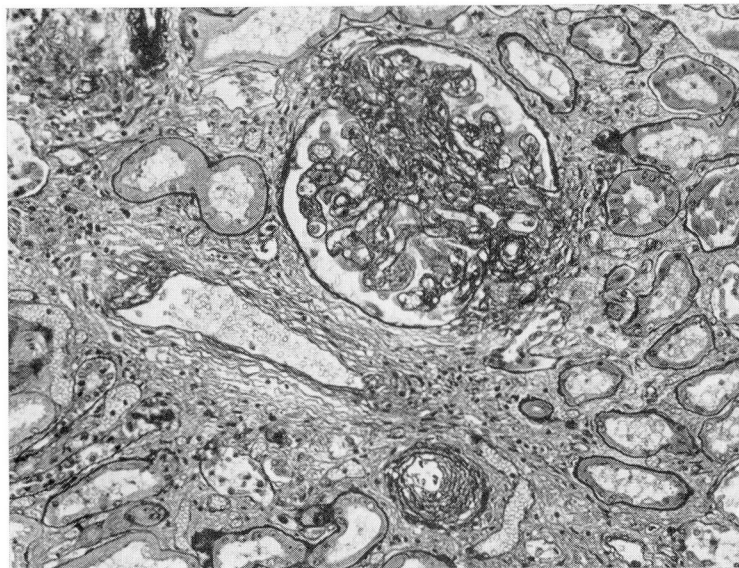


Fig. 2. Photomicrograph showing arterial and glomerular changes (chronic rejection) in the renal homograft. Note the intimal fibroplasia and thickening of a small artery and a preglomerular arteriole. The glomerulus also shows focal thickening, proliferation, and capsular adhesion of the basement membrane. Hematoxylin and eosin stains; magnification $\times 150$.

of the preglomerular arterioles there were focal fibrinoid changes. The glomerular changes were highly variable and included slight epithelial proliferation, slight thickening of the basement membrane, and rarely adhesions between the glomerular tuft and the Bowman's capsule. In addition, there were mild tubular atrophy, interstitial fibrosis, and focal interstitial infiltration of small lymphocytes. No pyroninophilic cells were present. The immunofluorescent studies showed significant deposition of IgM in the walls of small arteries (arcuate and interlobular) and preglomerular arterioles (*Fig. 3 and 4*). There was also slight focal deposition of IgM in the glomeruli, although this was distinctly less prominent than that in the small arteries and arterioles. IgG and the β_1c/β_{1A} components of complement also showed a deposition similar to that of IgM; this also was much less prominent than that of IgM. In contrast, IgA did not appear to be localized at any of these sites.

DISCUSSION

The arterial changes noted in the renal transplant, namely the severe intimal fibroplasia of arteries and arterioles, were compatible with a chronic rejection reaction. Similar arterial changes were not seen anywhere else in the body, again suggesting that they are probably related to the rejection process in the renal homograft. The striking deposition of IgM, and to a less extent that of IgG, and the components of complement in the walls of these arteries, is compatible with the probably immunologic nature of the vascular injury during rejection of the renal homograft.

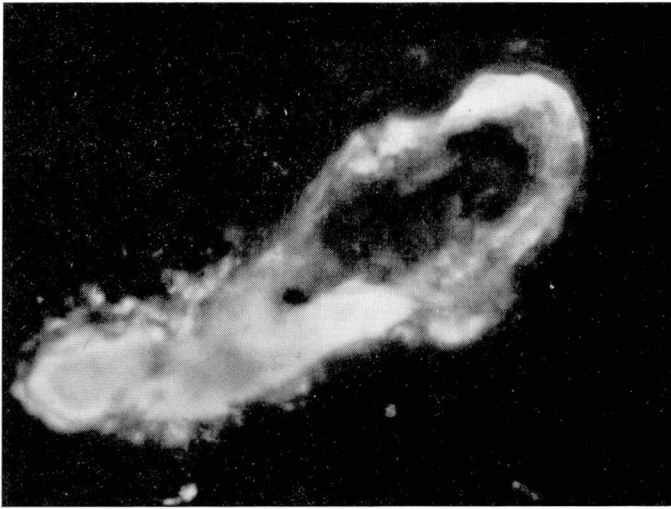


Fig. 3. Photograph showing arterial deposition of immunoglobulin IgM in the renal homograft. Note the evidence of intense fluorescence (IgM) in the wall of an arcuate artery.

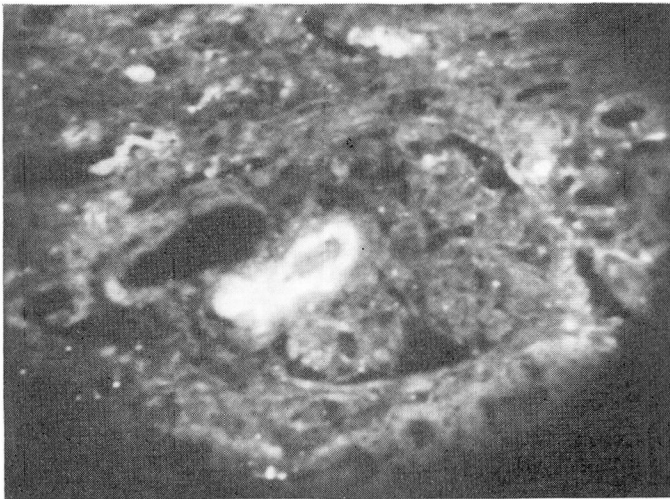


Fig. 4. Photograph showing deposition of immunoglobulin IgM in an afferent arteriole in the renal homograft.

Horowitz and associates⁵ have shown that during rejection of canine renal homografts the immunoglobulin IgG and complement become localized in the walls of small arteries, and recently Porter and associates,⁴ and Hadley and Rosenau⁶ made similar observations in human renal homografts with evidence of rejection. However, in none of these

studies did the immunoglobulin IgM appear to be localized in small arteries or in the glomeruli of the renal homograft. The localization of IgM in the patient we studied, suggests that in some cases antibodies related to the IgM variety may also play a role in the immunologic rejection of the homograft. It is not clear at the present time whether these IgM antibodies are related to isohemagglutinin anti B (donor AB, recipient A in this particular case) or they are antibodies against other antigens in the renal homograft. The latter possibility appears more likely, since we have seen similar IgM localization in ABO compatible renal homografts also. It should be pointed out, however, that the mere presence or localization of an immunoglobulin at a specific site does not conclusively prove its role in an immunologic reaction, nor does it prove the immunologic nature of the specific pathologic process. In addition to that in renal transplants we have seen localization of IgG and IgM in the arterial walls of kidneys of patients with malignant hypertension or with scleroderma. The significance of these antibodies will be made clear only through direct studies involving first, isolation of these antibodies, and secondly their interaction with the specific antigens in the arterial tree of the renal homograft.

SUMMARY

A 56-year-old Caucasian man, with terminal renal failure due to chronic pyelonephritis, received a renal homograft from a cadaver donor. The renal homograft functioned well for about 11 months, and thereafter showed progressive deterioration due to rejection. The patient died in uremia 14½ months after the transplantation.

Light-microscope and immunofluorescent studies showed definite arterial changes in the renal homograft, compatible with a chronic rejection reaction, and a striking deposition of immunoglobulin IgM in the walls of small arteries and arterioles. These studies suggest that antibodies of the IgM type may play a role in the immunologic rejection of renal homografts.

ACKNOWLEDGMENTS

We gratefully acknowledge the assistance of Miss Marian Sue Matz and of Mrs. Karen Vagianos in performing the immunofluorescent studies.

REFERENCES

1. Porter, K. A.: Chap. 21, Renal Transplantation, p. 601-643, in Heptinstall, R. H.: Pathology of the Kidney, 1st ed. Boston: Little, Brown and Company, 1966, 836 p.
2. Milgrom, F., and others: Humoral antibodies in renal homograft. *J.A.M.A.* **198**: 226-230, 1966.
3. Iwasaki, Y.; Talmage, D., and Starzl, T. E.: Humoral antibodies in patients after renal transplantation. *Transplantation* **5**: 191-206, 1967.

4. Porter, K. A., and others: Human renal transplants. I. Glomerular changes. *Lab. Invest.* **16**: 153-181, 1967.
5. Horowitz, R. E., and others: Immunologic observations on homografts. II. The canine kidney. *Transplantation* **3**: 318-325, 1965.
6. Hadley, W. K., and Rosenau, W.: Study of human renal disease by immunofluorescent methods. *Arch. Path.* **83**: 342-351, 1967.