

Carcinoma of the pancreas

A REVIEW OF ONE HUNDRED CASES

HIRSCH RASTOGI, M.D.,*

CHARLES H. BROWN, M.D.

Department of Gastroenterology

CARCINOMA of the pancreas constitutes from 3.6 to 4.1 percent of all malignant disease in the general population.¹ The early diagnosis of neoplastic lesions of the pancreas seems just as difficult today as it was in 1933 when so described by Rigler.² The retroperitoneal location of the pancreas renders physical examination and radiologic procedures ineffective in determining the size and state of the pancreas. Thus, of necessity, various diagnostic criteria are directed toward detection of change in the viscera close to the pancreas. Clinical features suggestive of neoplasm of the pancreas may be so diverse and nonspecific, or late in developing, that the clinician cannot rely on them as a basis for early diagnosis. Further, to delay the diagnosis till the pathognomonic signs of the disease—pain, loss of weight, and jaundice—appear, seriously jeopardizes even a remote chance of the patient's survival. In every suspected case, even laparotomy might not be diagnostic, and is certainly not the most desirable or practical approach. The five-year surgical "cure rate" is so low in regard to pancreatic cancer that the prognosis in most cases has not been altered by delayed operative treatment.

Diagnosis is relatively easy in regard to some of the functioning neoplasms, such as ulcerogenic tumor of the pancreas, and carcinoma of the β -islet cells of the pancreas. Tumors causing hypercalcemia,^{3, 4} carcinoid-like syndrome,⁵ and refractory diarrhea leading to hypokalemia^{4, 6} have also been reported but they occur infrequently. The hormonal effects of these tumors may precede manifestations resulting from the size and mechanics of the neoplasm and, hence, lead to a definitive diagnosis before the tumor becomes incurable; however, even in regard to the functioning carcinomas of the pancreas, the cure rate is low.

The nonfunctioning tumor poses the major diagnostic problem. Numerous enzymatic studies have been evaluated, and specialized radiologic procedures devised, in an attempt not only to establish an early diagnosis, but also to determine neoplastic extent and size, so as to permit prompt and adequate treatment. At present, these studies are not completely relia-

* *Fellow, Department of Gastroenterology.*

ble, and the advantages of some of them are offset by prohibitive costs, thereby disqualifying them as screening tests in all suspected cases. Our study was undertaken to review the clinical data and to evaluate the various tests currently used in the diagnosis of carcinoma of the pancreas.

MATERIALS AND METHODS

One hundred patients, each with histologically proved malignant neoplasm of the pancreas, observed at the Cleveland Clinic Hospital between 1962 and 1967, comprise the series of the study. All pertinent clinical, biochemical, and radiologic data were recorded. Histologic diagnosis in each case was established, by biopsy, at operation (88 patients) or at necropsy (12 patients).

The diagnosis of carcinoma of the pancreas was made in a number of other patients by clinical and operative findings, and subsequent course, but they have not been included for lack of histologic proof. In most of these cases biopsy specimens were not obtained, but, in some, biopsy revealed pancreatitis, which we believe was secondary to an underlying malignant neoplasm.

RESULTS

Age range and sex ratio. The distribution of carcinoma of the pancreas according to age and sex in this series is presented in *Table 1*. The youngest patient was 16 years of age and the oldest 86 years old. The majority of patients (64 percent) were in their sixth and seventh decades. The male to female ratio was 1.56:1.

Location of the tumor. The head of the pancreas was the most common location (35 patients), the next was the body (20 patients). In only three patients was the tumor confined to the tail; whereas the tumors in nine pa-

Table 1.—*Age and sex of 100 patients with carcinoma of the pancreas*

Age group, years	Number of patients		
	Male	Female	Total
Less than 20	1	0	1
20-29	0	0	0
30-39	1	0	1
40-49	8	7	15
50-59	20	16	36
60-69	17	12	29
70-79	12	3	15
80-89	2	1	3
Total	61	39	100

Table 2.—Symptoms of 100 patients with carcinoma of the pancreas

Symptoms	Number of patients, subtotal						Number of patients, total (100)
	Carcinoma of the pancreas, site						
	Head (35)	Head and body (14)	Body (20)	Body and tail (19)	Tail (3)	Indeterminate (9)	
Weight loss	26	11	15	16	3	8	79
Abdominal pain	26	11	18	15	3	6	79
Anorexia	14	6	8	6	1	5	42
Back pain	8	3	9	7	0	3	30
Jaundice	20	6	0	0	0	3	29
Psychiatric manifestations	2	3	6	7	0	1	19
Diarrhea	5	6	2	2	0	2	18
Weakness	5	3	4	5	0	1	18
Nausea	6	1	4	3	0	3	17
Constipation	2	1	7	4	0	2	16
Vomiting	4	1	2	1	0	2	10
Colic	2	0	0	0	0	0	2
Edema	2	0	1	0	0	0	1

tients could not be adequately classified because of involvement of the entire gland. In 14 patients the head and the body of the pancreas were affected, and in 19 the body and the tail were involved.

Symptoms. The presenting symptoms of the patients are listed in *Table 2*. Weight loss and abdominal pain occurred with equal frequency in patients having tumors at various locations. Loss in weight ranged from 5 pounds to more than 55 pounds in a time ranging from 1 month to 14 months. Most patients lost between 10 and 30 pounds in from two to six months.

Abdominal pain was reported by 79 patients, 14 of whom characterized the pain as dull, gnawing, and constant, 10 as burning and/or boring, and two as crampy. Pain most often occurred in the epigastrium (16 of 26 patients). Pain in the right upper quadrant of the abdomen occurred in seven patients, and in the left upper quadrant in three. Radiation of pain to the back occurred in five patients. Isolated backache was reported by three patients. Postprandial exacerbation of pain was noted by six patients. The incidence and character of abdominal pain were almost similar in regard to other sites of carcinoma of the pancreas. Back pain was more frequent with involvement of the body of the pancreas, and in 30 patients occurred in a distribution ranging from the infrascapular region to the lumbar spine, including the left flank. Pain in the left upper quadrant of the abdomen was also more frequent in cases of tumors of the body of the pancreas than else-

where. Only two patients reported colic, and both had tumors of the head of the pancreas.

Jaundice was reported as a symptom by 29 patients, of whom 20 had cancer in the head of the pancreas. In all but four patients, jaundice was progressive. In two of them, cholecystojejunostomy had been performed at other hospitals, and the patients had residual icterus. The other two patients each had a history of reduction in intensity of jaundice with questionable fluctuation. Of 14 patients with involvement of the head and body of the pancreas, six had jaundice, as did three from the unclassified group.

Anorexia occurred in 42 patients, most frequently in those with tumor in the head of the pancreas, and this was the presenting symptom in four patients. Eighteen patients had diarrhea, chiefly those patients with tumors of the body and head of the pancreas. Stools averaged three or four per day, and were described as frothy, bulky, and explosive, by five patients. Sixteen patients had constipation. Emotional disturbances were mentioned by 19 patients and were of maximum frequency when the neoplasm was in the body and tail of the pancreas. The disorders were classified as: depression (eight patients), agitated depression (five patients), anxiety state (six patients).

Physical findings. The most frequent physical sign in this series was hepatomegaly (45 percent) (*Table 3*). The degree of enlargement of the liver ranged from 1.5 cm to 15 cm palpable below the right costal margin. Isolated enlargement of the left lobe was present in seven patients. The consistency of the hepatic enlargement was: soft in eight, firm in 11, and hard in 26 patients. Tenderness over the liver was elicited in all patients in various degrees, and distinct nodules or irregularity was felt in eight patients who had "hard" hepatomegaly. Jaundice was reported by 29 patients, but examination revealed another three who were unaware of gradually developing icterus. No patients who had tumors that affected the body and/or tail of the pancreas were icteric at the time of examination.

An abdominal mass was palpable in 23 patients; locations were in the epigastrium in 14 patients; in the left upper quadrant in four; in the umbilical region in four; and in the left groin in one patient. In six patients, the epigastric mass was pulsatile. A palpable gallbladder was noted in each of seven patients, all of whom were jaundiced.

Appreciable muscle wasting and malnutrition were evident on physical examination in 14 patients. Upper abdominal systolic bruits were audible in 13, of whom 11 had involvement of the body of the pancreas. Phlebitis was noted in four patients, with unilateral lymphedema secondary to thrombophlebitis in one patient.

Laboratory studies (*Table 4*). Increase in bilirubin content (according to both total and direct determinations) occurred most frequently in pa-

CARCINOMA OF THE PANCREAS

Table 3.—Physical findings of 100 patients with carcinoma of the pancreas

Signs	Number of patients, subtotal						Number of patients, total (100)
	Carcinoma of the pancreas, site						
	Head (35)	Head and body (14)	Body (20)	Body and tail (19)	Tail (3)	Indeterminate (9)	
Hepatomegaly	20	6	7	6	0	6	45
Jaundice	23	7	0	0	0	2	32
Abdominal mass	5	3	5	8	0	2	23
Malnutrition, muscle wasting	8	1	1	3	0	1	14
Bruits	1	2	3	6	0	1	13
Abdominal tenderness	4	2	2	3	0	1	12
Palpable gallbladder	6	1	0	0	0	0	7
Ascites	3	1	1	1	0	1	7
Edema	0	0	2	1	0	1	4
Phlebitis	1	0	2	1	0	0	4
				(Lymphedema)			
Signs from metastasis	1	0	0	0	0	1	2
	(Hemiplegia)						
Miscellaneous	1	0	0	0	0	0	1
	(Pancreatic fistula)						

tients who had tumors of the head of the pancreas, as did an increase in serum alkaline phosphatase content and increased sulfobromophthalein retention. Though symptomatic jaundice was present in 20 of 35 patients with tumors affecting the head of the pancreas, hyperbilirubinemia was detected in 24. The sulfobromophthalein retention was determined in 51 anicteric patients; 27 of 32 with greater than 5 percent retention were found to have hepatic metastases. The overall range of sulfobromophthalein retention ranged from 8 to 66 percent. The serum alkaline phosphatase content was determined in 81 patients and was increased in 52, ranging from 14 to 145 King-Armstrong units. An accurate correlation of elevated serum alkaline phosphatase content with hepatic metastases is not feasible, since all patients were not tested, reliance being placed on other studies for evaluation of the hepatic status. *Table 5* presents the data available concerning enzyme activity in our series. A disturbance in carbohydrate tolerance was present in 40 patients as detected from urinalysis, fasting blood sugar content, and glucose tolerance tests. Nine patients with glycosuria had preexisting diabetes mellitus. All patients with an abnormal fasting

Table 4.—Laboratory data of 100 patients with carcinoma of the pancreas

Determination or test	Number of patients, subtotal						Number of patients with abnormal values/total number of patients tested (100)
	Carcinoma of the pancreas, site						
	Head (35)	Head and body (14)	Body (20)	Body and tail (19)	Tail (3)	Indeterminate (9)	
Blood hemoglobin, 12 g/100 ml	14/35	3/14	2/20	9/19	0/3	1/9	29/100
Bilirubin:							
Direct, 0.3 mg/100 ml	24/35	7/14	1/20	2/19	0/3	4/9	38/100
Total, >0.1 mg/100 ml	24/35	7/14	1/20	2/19	0/3	4/9	38/100
Fasting blood sugar, >100 mg/100 ml	6/19	1/5	1/13	2/12	0/2	3/8	13/59
Abnormal glucose tolerance test	12/13	3/4	4/8	6/8	0/1	6/8	31/42
Glycosuria present	3/35	1/14	1/20	2/19	0/3	2/9	9/100
Serum amylase, >200 mg/100 ml	8/24	6/12	8/13	6/13	1/2	3/6	32/70
Serum lipase, >1 unit	3/9	2/4	1/7	1/8	0/1	1/3	8/32
Serum alkaline phosphatase, King-Armstrong units	20/27	11/13	5/15	10/16	1/3	4/7	52/81
Sulfobromophthalein retention, 5%/45 minutes	9/11	5/8	5/11	7/14	2/2	5/5	37/51
Stool guaiac test, positive	4/30	3/14	3/20	1/19	0/3	1/9	12/95
Serum proteins, <6 g/100 ml	4/18	2/9	1/10	1/7	0/2	0/4	8/48
Serum carotene, <35 mg/100 ml	4/5	2/3	1/1	1/1	0/0	0/0	8/10
D-xylose, <2 g/100 ml	3/5	2/3	0/1	1/1	0/0	0/0	6/10
Secretin:							
Vol., <2 ml/kg body weight	1/3	4/6	4/5	3/5	0/1	0/1	12/20
HCO ₃ , <90 mEq/liter	1/3	5/6	4/5	2/5	0/1	0/1	12/20
Cytologic study, positive	1/3	0/6	1/5	0/5	1/1	0/0	3/20

Table 5.—Serum alkaline phosphatase values in relation to hepatic metastases of carcinoma of the pancreas

Carcinoma of the pancreas		Number of patients with serum alkaline phosphatase content in excess of 14 King-Armstrong units	Proved hepatic metastasis, number of patients
Site	Number of patients		
Head	27	20	9
Body and head	13	11	6
Body	15	6	5
Body and tail	16	10	7
Tail	3	1	1
Indeterminate	7	4	4
Total	81	52	32

blood sugar content underwent glucose tolerance tests. Eighteen patients each had a family history of diabetes.

Of 70 patients, 32 had serum amylase values exceeding 200 units; in only one patient was it more than 600 units. Serum lipase content was abnormal in 8 of 32 patients tested. The association of acute and/or chronic pancreatitis with pancreatic carcinoma is detailed in a subsequent section.

CARCINOMA OF THE PANCREAS

Twelve patients had guaiac-positive stools. Four of these had duodenal erosion; one patient had involvement of the ampulla of Vater. One patient had involvement of the duodenum and pyloric obstruction, and one had involvement of the posterior wall of the stomach. Only one patient with involvement of body and tail of the pancreas had occult blood in the feces.

Ten patients whose histories were suggestive of pancreatitis or steatorrhea

Table 6.—*Roentgenographic evidence of disease in 100 patients with carcinoma of the pancreas*

Observations	Number of patients, subtotal						Number of patients, total (100)
	Carcinoma of the pancreas, site						
	Head (35)	Head and body (14)	Body (20)	Body and tail (19)	Tail (3)	Indeterminate (9)	
Upper gastrointestinal series	23	10	15	17	3	6	74
Displacement	3	2	0	3	1	0	9
Antral deformity	3	1	2	1	0	1	8
						(Gastric ulcer)	
Pad sign	1	0	0	0	0	1	2
Pyloric obstruction	0	1	2	1	0	0	4
				(Duodenal obstruction)			
Wide duodenal loop	2	2	1	0	0	1	6
Abnormal duodenal mucosa	2	1	1	2	0	1	7
				(Compression)			
Barium enema	5	3	13	6	3	2	32
Extrinsic pressure	0	0	0	1	0	1	2
				(Hepatic flexure)			
Obstruction	0	0	0	0	0	1	1
Small bowel series	2	5	4	2	1	0	14
Motility disorder	0	1	1	0	0	0	2
			(Dilated ileum)				
Cholecystogram	19	6	7	8	3	3	47
Not visible on roentgenogram	5	1	0	0	0	1	7
Stones in gallbladder	6	1	1	0	0	0	8
Dilated duct	6	2	1	1	0	1	11
Pancreatic calculi	1	0	0	0	0	0	1
Celiac angiogram	7	4	9	13	2	2	37
Encasement/displacement							
Celiac artery	3	1	2	7	0	0	13
Splenic artery	1	0	4	4	1	0	10
Hepatic artery	3	1	2	3	0	0	9
Superior mesenteric artery	0	1	2	4	0	0	7
Gastroduodenal artery	3	0	0	2	0	0	5.5
Transverse pancreatic artery	0	0	0	2	0	0	2
Tumor stain	3	0	1	2	0	1	7
Abnormal hepatogram	3	0	2	0	0	0	5
Tortuosity	2	2	1	1	0	1	6
				(Stretched)		(Stretched)	

were studied for malabsorption, by determination of serum carotene content and amount of d-xylose absorption. Eight patients had biochemical evidence of malabsorption.

Duodenal drainage was performed after secretin stimulation in 20 patients, and yielded valuable information in regard to 12 who had low volumes of secretion (<2 ml per kilogram of body weight) and low sodium bicarbonate concentration (<90 mEq per liter). Atypical cells suggestive of malignancy were recovered by duodenal drainage from three patients.

Roentgenographic observations (Table 6). Upper gastrointestinal serial roentgenograms were made of 74 patients. Some abnormality, usually non-specific for pancreatic carcinoma, was present in 36 instances. Significant findings were most frequently confined to those patients who had neoplasm of the head of pancreas. Displacement, antral deformity, abnormality in duodenal mucosa, and a wide duodenal loop, were the most common observations (Fig. 1 and 2). A small-bowel series of roentgenograms was abnormal but of no diagnostic significance in 2 of 14 patients. Roentgeno-

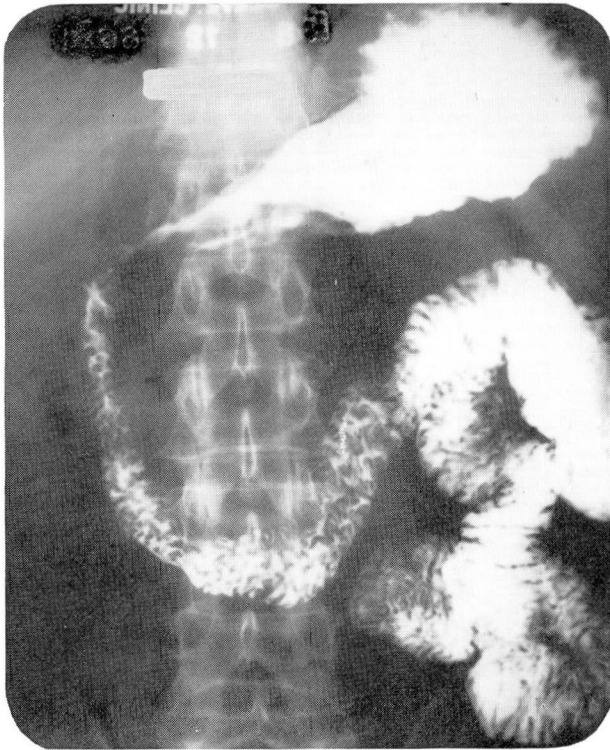


Fig. 1. Roentgenogram demonstrating compression with upward displacement of the antrum and widening of the duodenal loop (c-loop).

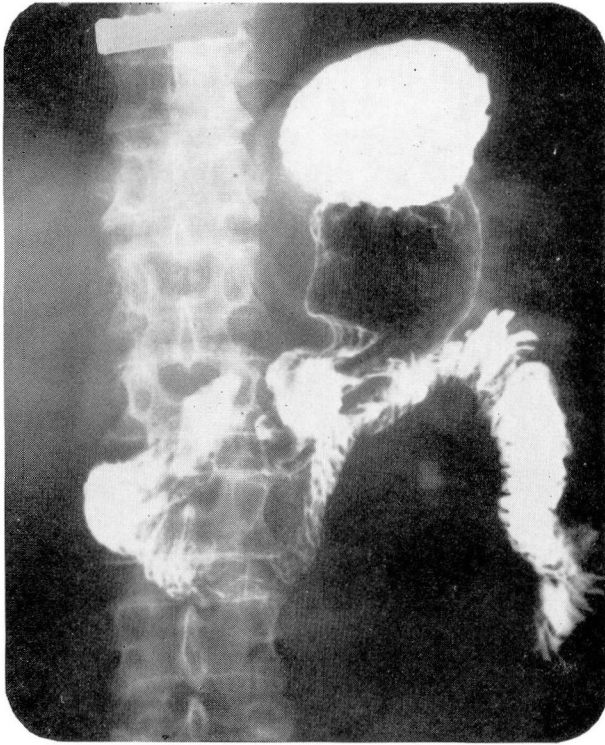


Fig. 2. Roentgenogram showing effacement of the duodenal mucosa and spikes on the medial wall.

grams made after barium enemas offered little diagnostic help. One patient had an extrinsic pressure defect at the hepatic flexure. Cholecystograms revealed gallstones in 8 of 47 patients, of whom six had tumor in the head of the pancreas. The gallbladders of seven patients were not demonstrated, and in 11 patients dilated common bile ducts were found. Evidence of pancreatic calculi was seen on one roentgenogram (*Fig. 3 and 4*).

Splanchnic angiograms of 37 patients were made by means of the percutaneous transfemoral technic; 31 provided evidence for definitive diagnoses. Tumor encasement of the celiac trunk was demonstrated in 13, and of the splenic trunk in 10. Evidence of tumor encasement of hepatic, superior mesenteric, gastroduodenal, and transpancreatic arteries was demonstrated infrequently. Tumor staining, or "blush," in the pancreas was demonstrated in two angiograms, and in the liver in five. The capillary phase of the hepatic arteriogram (hepatogram) was suggestive of metastatic or replacement disease in five patients. Increased tortuosity of hepatic arterial branches or their stretching was found to be a reliable index of hepatic involvement (*Fig. 5 through 8*).

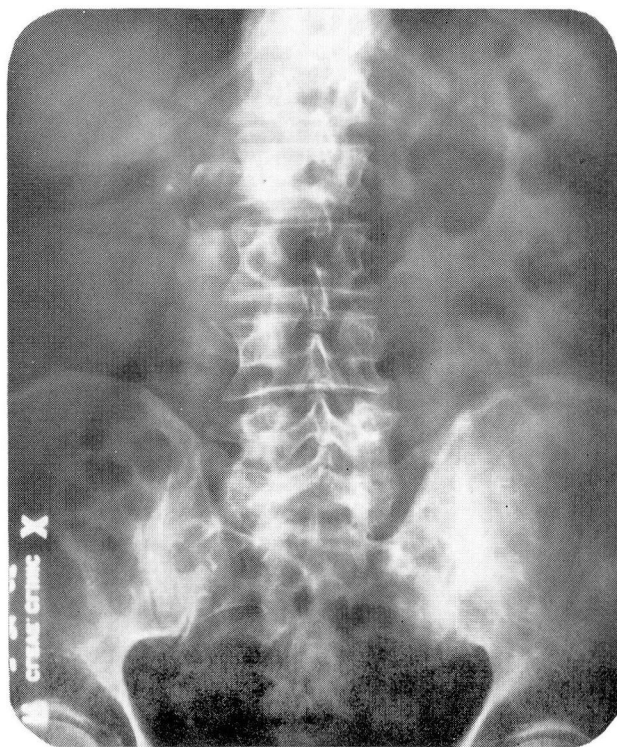


Fig. 3. Roentgenogram showing calcification in the head of the pancreas.

All seven patients with carcinoma of the head of the pancreas had abnormal celiac angiograms as did the two with extensive tumefaction of the entire gland. Of four patients with tumors in the head and body of the pancreas, the angiograms of three were suggestive of carcinoma of the pancreas. Angiographic abnormalities were demonstrated in seven of nine patients with tumor in the body of the pancreas, 11 of 13 with tumor in the body and tail, and one of two with tumor confined to the tail of the pancreas.

The presence of abdominal bruits correlated reasonably well with subsequent angiographic observations. Of 13 patients with bruits, seven had arteriograms that demonstrated encasement or vessel stenoses.

Of 37 scintigrams of the pancreas, made after injections of selenium⁷⁵-tagged methionine, 24 were interpreted as showing tumor. Selective lack of radioactivity or complete failure to demonstrate the gland were the two most common observations (Fig. 9 and 10).

Sites and incidence of metastases. Eighty-three patients had identifiable metastatic lesions at the time of diagnosis. Hepatic lesions were observed at

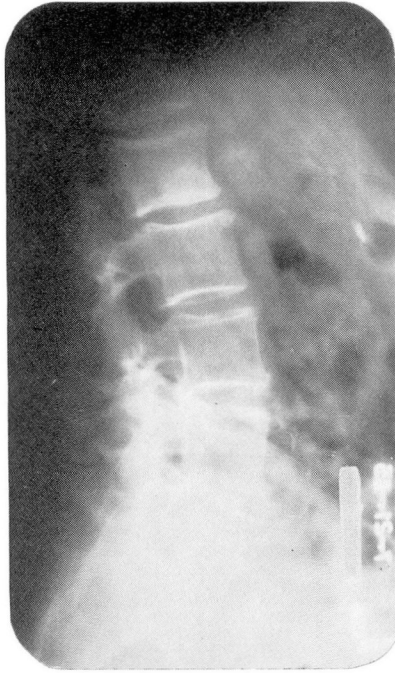

Fig. 4. Roentgenogram, lateral view showing pancreatic calculi.

the time of operation or at autopsy in 53 patients; 26 had mesenteric involvement, and 24 had tumefaction in regional nodes. The peritoneum and omentum were affected with equal frequencies. Diffuse abdominal carcinomatosis was seen in 13 patients and distant spread in five patients.

Histologic diagnosis. The histopathologic character of the neoplasm was established from biopsy specimens excised at the time of operation for each of 88 patients, and at autopsy for 12. The following data were obtained: adenocarcinoma—51, undifferentiated or poorly differentiated carcinoma—43, scirrhous carcinoma—2, and cystadenocarcinoma—5. In the course of this study, we observed one patient with reticulum cell sarcoma, one with an acinar cell carcinoma, and two with malignant islet cell adenomas; these latter four patients, since the histologic character differed from the usual findings in carcinoma of the pancreas, are not included in this series. Associated inflammatory change with some fibrosis was present in 11 patients.

Surgical treatment. The surgical procedures performed in 88 patients are listed in *Table 7*. Only exploration and biopsy were feasible in 67, and bypass palliative operations in 17 patients. Of 17 patients who had no metastatic disease, three underwent Whipple's operation, and one with involvement of body and tail of the pancreas underwent a partial pancreatec-

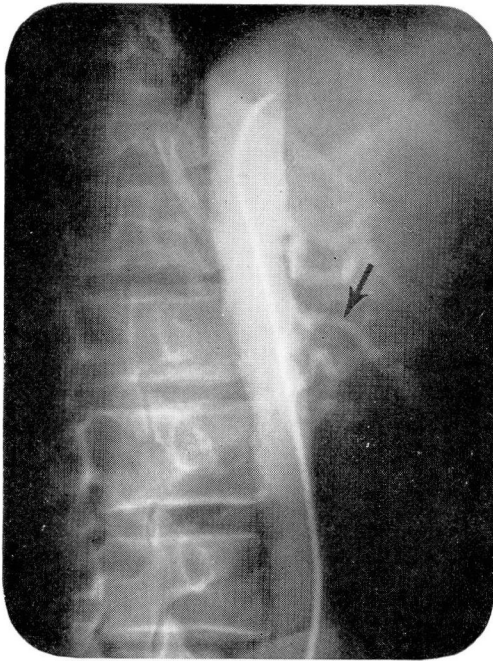

Fig. 5. Aortogram, lateral view showing proximal encasement of the celiac axis.

tomy. A resection was not considered in the others because of encroachment of the portal vein and/or the superior mesenteric vessels.

Survival. The lengths of survival of the patients from the onset of the first symptoms are shown in *Figure 11*. Eighty-two patients have died. The range of survival was from 2 months to 36 months, with an average of 12.8 months. The length of survival of those who underwent resection did not differ significantly from that of those given palliation. In a series of 100 patients reported by Lowe and Palmer,⁷ those undergoing palliative surgery survived longer than the others; however, the longest survival was only 14 months. The survival was relatively longer among patients having islet cell tumor or cystadenocarcinoma.

DISCUSSION

A correct diagnosis before operation (88 patients) or autopsy (12 patients) was made in 59 percent of the cases in this series. In 13 percent a neoplastic process was suspected from the history, physical examination, and laboratory studies, although the locus of the tumor was incorrectly assigned. A diagnosis of pancreatitis was made in six, cholecystitis in four, and pancreatic cysts in two patients. The latter three diagnoses were not entirely erroneous, since the disorders were present as secondary manifestations of

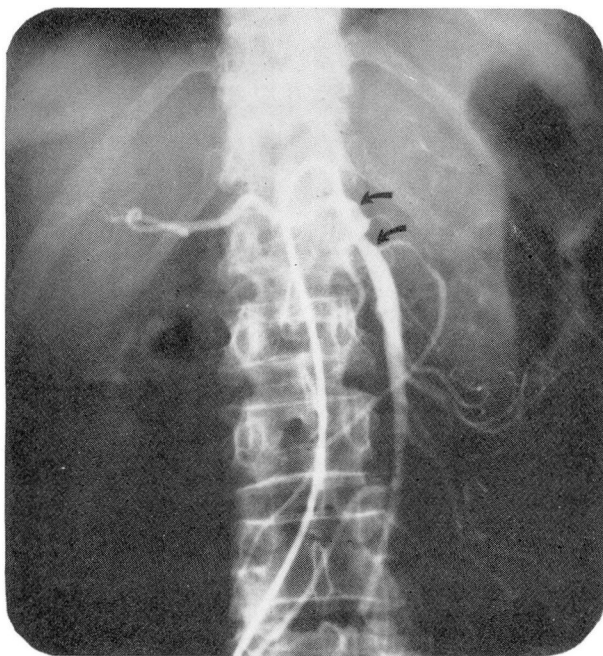


Fig. 6. Roentgenogram showing encasement of the proximal part of the superior mesenteric artery. The hepatic artery, which branches off the superior mesenteric artery, is also encased.

pancreatic neoplasms. However, the clinician failed to realize that these signs and symptoms were secondary to the basic and more lethal carcinoma of the pancreas.

The usual course of carcinoma of the pancreas is one of swift, relentless progression. An early diagnosis would appear to be mandatory for survival. However, there are no early signs. Persistent abdominal pain and weight loss are two of the most frequent symptoms of carcinoma of the pancreas. Gullick⁸ reported weight loss of between 20 and 40 pounds within from two to six months. Abdominal pain is variable, but its persistence and association with back pain should alert one to the possible presence of a pancreatic lesion. The proximity of the pancreas to the celiac plexus could be the explanation of pain. Distension of the biliary ducts or the pancreatic ducts or both have also been postulated as the cause of pain.⁹ Biliary colic may herald pain,¹⁰ as may also duodenal erosion simulating an ulcer. Pain in most cases is in the epigastrium, though tumors in the head of the pancreas are likely to cause pain in the right upper quadrant of the abdomen, and tumors of the body and tail on the left side, as supported by the electric experiments of Bliss and associates.¹¹ Back pain occurred

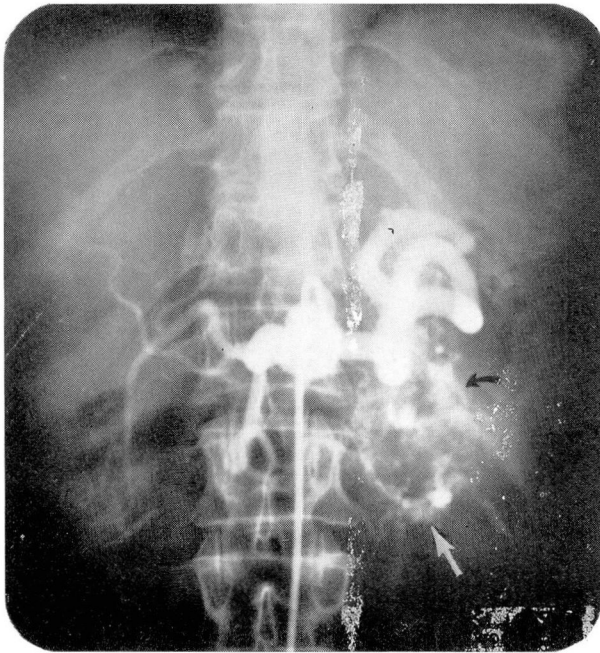


Fig. 7. Roentgenogram demonstrating tumor-staining in the region of the body and the tail of the pancreas.

more frequently with lesions affecting the body and tail of the pancreas than with those affecting the head.

Eighty-eight patients in our series underwent operation. Exploration with biopsy, surgical resection, bypass operations, and splanchnic nerve division for intractable pain were the main procedures done. The type of procedure depended upon the size of the lesion, its location, and extent. It is the practice of most surgeons to biopsy localized lesions where resection is most feasible. In extensive lesions with metastasis, biopsy of the pancreas is avoided and a regional lymph node or the liver is generally biopsied. For cancer of the head of the pancreas, the operation introduced by Whipple is used only when the tumor has not extended beyond the limiting areas of resection.¹² Unfortunately the prognosis of carcinoma of the pancreas is gloomy even among the patients selected for curative resection. Palliative surgical procedures include bypass operations and division of the splanchnic nerve. The former procedures are undertaken when a carcinoma of the head of the pancreas, which causes biliary obstruction, cannot be safely resected. Cholecystojejunostomy or choledochojejunostomy is the operation of choice. A bilateral splanchnicectomy for relief of excruciating back pain, in some instances, may be preferable to reliance on narcotics.

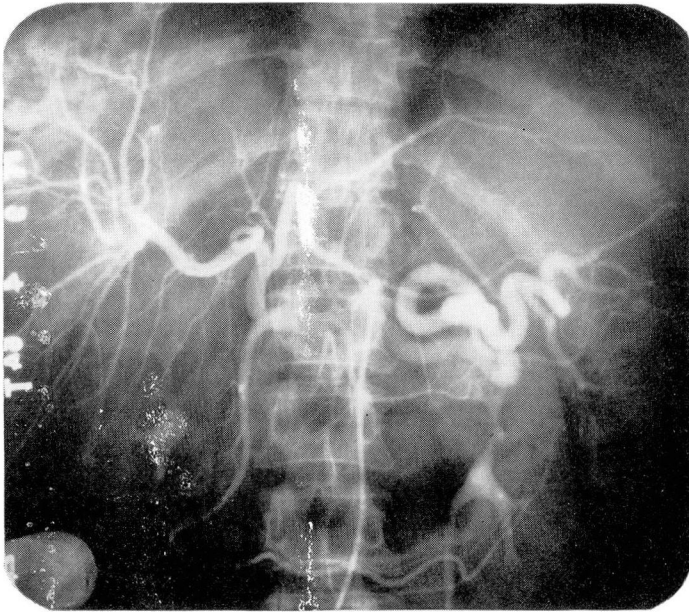


Fig. 8. Roentgenogram showing tumor-staining in the upper part of the right hepatic lobe with stretched intrahepatic arteries.

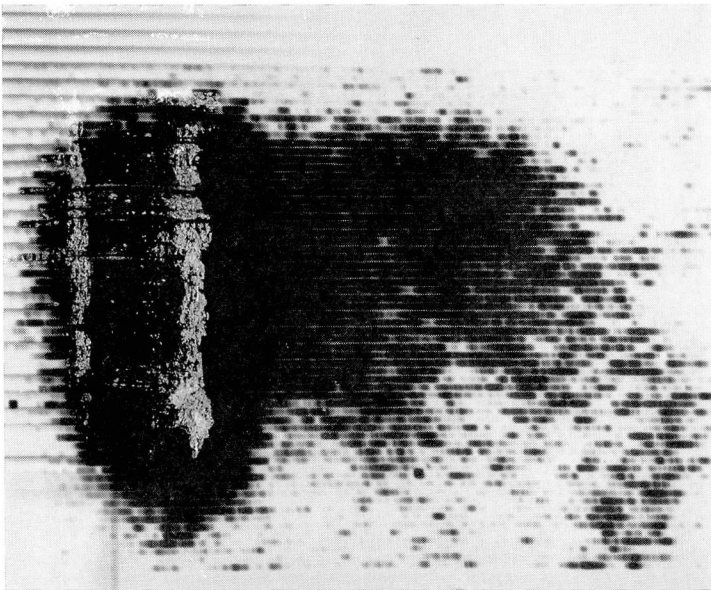


Fig. 9. Scintigram showing lack of radioactivity in the head and the body of pancreas, with hepatic metastasis.




Fig. 10. Se⁷⁵-methionine scintigram showing failure of demonstration of the pancreas.

Table 7.—Surgical and autopsy data

Site of pancreatic carcinoma	Number of patients			
	Surgical exploration and biopsy	Bypass procedures	Resection	No operation, diagnosis at autopsy
Head	19	8	1	7
Head and body	8	5	1	0
Body	16	1	1	2
Body and tail	14	2	1	2
Tail	3	0	0	0
Not classified	7	1	0	1
Total	67	17	4	12

Emotional disturbances occur more often in patients with tumors of the body and tail of the pancreas than in those with neoplasms in the head of the pancreas. An incidence of emotional abnormality as high as 33 percent has been reported.¹³ The mechanism of genesis of these symptoms is not known, but they are often the first to appear.¹⁴

Hepatomegaly occurs more often with tumors located in the head of the pancreas, than in the body or tail, and is not necessarily indicative of metastasis. Biliary stasis and cholangitis are contributory causes. Hepato-

CARCINOMA OF THE PANCREAS

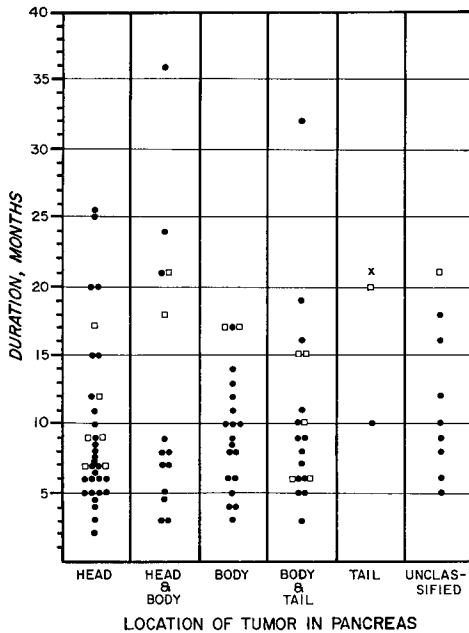


Fig. 11. Scattergram showing lengths of survival of 100 patients in relation to locations of carcinoma of the pancreas. Symbols: *black dot*, patient who died; *white square*, patient who is living; *X*, patient who has been lost to follow-up study.

megaly, in association with tumors in the body and tail of the pancreas, usually is indicative of metastatic disease.

In our series of patients, the gallbladder was palpable only in those patients with tumor in the head of the pancreas, in all cases being accompanied by jaundice (Courvoisier's law).

Audible abdominal bruits strongly suggest vessel encasement or constriction, and are indicative of tumor involving the body and/or the tail of the pancreas.¹⁵

Thrombophlebitis or venous thrombosis occurred in four patients in this series, of whom three had tumors in the body and tail of the pancreas. The incidence of arterial and venous thromboembolic phenomena as high as 42 percent was reported to occur in patients with carcinoma involving the body and tail of the pancreas.¹⁶ It is believed that the frequency of venous thrombosis is greater in patients having highly undifferentiated tumors, and in those having mucin-producing ones.¹⁷

In regard to our series of patients, laboratory studies helped little in locating the tumors. Of general diagnostic importance, however, were the glucose tolerance test, secretin-stimulated duodenal drainage analysis, and tests for malabsorption.

Diabetes or disturbance in carbohydrate tolerance is believed to result

from destruction of islet cells. Since most islet cells are located in the body and tail of the pancreas, lesions at these sites would be expected to cause diabetes most frequently. We did not observe this correlation in our series. It has been pointed out that tumors in the head of the pancreas, which cause destruction and atrophy of islet cells by distal obstruction, can also result in diabetes.⁸

It is of interest that the arbitrary level of 30 King-Armstrong units of alkaline phosphatase did not serve to distinguish medical from surgical jaundice in all cases. With 18 exceptions it did parallel conjugated hyperbilirubinemia. A similar conclusion was reached in another study at the Cleveland Clinic.¹⁸

Bleeding into the gastrointestinal tract from carcinoma of the pancreas can result from erosion or invasion of stomach or intestines or from hypoprothrombinemia after prolonged obstruction of the biliary duct. Such bleeding occurred in 12 patients in our series.

Upper gastrointestinal roentgenograms were abnormal in 36 of 74 patients. The abnormalities, however, were nonspecific, and did not indicate whether the changes were due to pancreatitis, a pancreatic cyst, or carcinoma of the pancreas. The roentgenograms were suggestive of some abnormality in the pancreas in from 50 to 70 percent of the patients with lesions in the head or body of the pancreas, but were of no diagnostic significance in lesions confined to the tail of the pancreas. These percentages are similar to those in another report.¹⁹ The most common finding is seen in patients with lesions in the head of the pancreas, and is characterized by displacement of the gastric antrum and the duodenum.

Gallstones were demonstrated in a total of eight patients, six of whom had lesions in the head of the pancreas. Since cholecystograms were made of only 47 patients in our series, we cannot with certainty compare the incidence of cholelithiasis in carcinoma of the pancreas with that of the general population. However, it is evident that cholelithiasis, dilatation of the common bile duct, and a nonfunctioning gallbladder occur more frequently in patients who have tumors affecting the head of the pancreas than in other parts of the organ.

Selenium⁷⁵-methionine scintigrams of the pancreas demonstrated carcinoma in 73 percent of the patients. Some inaccuracy in interpretation of pancreatic scintigrams is due to the avidity with which the liver concentrates methionine, masking the head of the pancreas.²⁰ A scintigram of the liver, made before one of the pancreas, facilitates outlining of the liver. Administration of large doses of methionine to saturate the liver before injecting selenium⁷⁵-methionine for pancreatic scanning has also been attempted in order to prevent obliteration of the pancreas, but without much success.²¹

Celiac and superior mesenteric arteriograms were made of 37 patients.

Extrinsic compression of celiac, splenic, or hepatic arteries was the commonest finding. We are studying this method of diagnosis for pancreatic and hepatic lesions more extensively at the present time, using magnification technics to demonstrate abnormal pancreatic vessels. Our results have been encouraging, and it is our belief that such technics, including catheterization of small pancreatic vessels, will be useful in demonstrating pancreatic vascular abnormalities produced by tumors.

SUMMARY AND CONCLUSIONS

A survey of 100 proved cases of carcinoma of the pancreas was made and is reported, with special reference to clinical features and diagnostic studies. A tissue diagnosis was obtained in each case; 12 diagnoses were made at autopsy. An attempt was made to associate signs, symptoms, and results of currently used diagnostic studies in identifying the location of tumors preoperatively. The following conclusions were reached:

1. Pain and weight loss are the chief symptoms in patients who have carcinoma of the pancreas. The predominant site of pain is in the right upper quadrant of the abdomen in cases of carcinoma of the head of the pancreas, and in the epigastrium and left upper quadrant in those with involvement of the body and tail of the pancreas. Back pain is common.

2. Emotional disturbances occur most frequently in patients who have carcinoma of the body and tail of the pancreas.

3. Jaundice is often a late manifestation of carcinoma of the head of the pancreas. It is rarely painless.

4. Nonspecific gastrointestinal manifestations are most frequently encountered in patients with carcinoma of the head of the pancreas.

5. Patients with carcinoma of the tail of the pancreas often have no symptoms other than weight loss and/or pain.

6. Hepatomegaly and jaundice are often the only physical abnormalities in patients with carcinoma of the head of the pancreas. Hepatomegaly does not necessarily indicate hepatic metastasis unless the tumor in the pancreas is distal in location (body and/or tail).

7. The presence of bruits and venous phlebitis is most common with neoplasm of the body and/or tail of the pancreas.

8. An abnormal glucose tolerance test occurs in about 50 percent of the patients.

9. A positive stool guaiac test, albeit infrequent, is suggestive of a lesion in the head and/or the body of the pancreas, with duodenal invasion.

10. In anicteric patients, the sulfobromophthalein retention was a more accurate indicator of hepatic metastasis than was serum alkaline phosphatase content. As a corollary, the serum alkaline phosphatase content could not be regarded as a sensitive test to distinguish medical from surgical jaundice.

11. The yield of positive results from duodenal drainage was not so rewarding as those reported in the literature.

12. An upper gastrointestinal series of roentgenograms and a cholecystogram showed direct or indirect evidence of pancreatic disease in from 50 to 55 percent of the patients.

13. Selective splanchnic angiography and photoscanning of the pancreas appeared to be promising diagnostic methods. The former procedure yielded a better result than the latter in our series.

14. Survival and prognosis in regard to carcinoma of the pancreas is poor. Patients who have islet cell tumors or cystadenocarcinoma have a somewhat better survival rate than those who have ductal adenocarcinoma.

15. All currently available aids in the diagnosis of carcinoma of the pancreas leave much to be desired. They are expensive and are definitive only late in disease.

16. A high index of suspicion on the part of the clinician is necessary to make an early diagnosis of pancreatic carcinoma.

REFERENCES

1. Cohen, G. F.: Early diagnosis of pancreatic neoplasms in diabetics. *Lancet* **2**: 267-269, 1965.
2. Rigler, L. G.: Diagnosis of extra-gastro-intestinal abdominal masses. *Radiology* **21**: 229-238, 1933.
3. Underdahl, L. O.; Woolner, L. B., and Black, B. M.: Multiple endocrine adenomas: report of 8 cases in which parathyroids, pituitary and pancreatic islets were involved. *J. Clin. Endocrinol.* **13**: 20-47, 1953.
4. Brown, C. H., and Crile, G., Jr.: Pancreatic adenoma with intractable diarrhea, hypokalemia, and hypercalcemia. *J.A.M.A.* **190**: 30-34, 1964.
5. Murray, J. S.; Paton, R. R., and Pope, C. E., II: Pancreatic tumor associated with flushing and diarrhea; report of a case. *New England J. Med.* **264**: 436-439, 1961.
6. Verner, J. V., and Morrison, A. B.: Islet cell tumor and a syndrome of refractory watery diarrhea and hypokalemia. *Am. J. Med.* **25**: 374-380, 1958.
7. Lowe, W. C., and Palmer, E. D.: Carcinoma of the pancreas; an analysis of 100 patients. *Am. J. Gastroenterol.* **47**: 412-420, 1967.
8. Gullick, H. D.: Carcinoma of the pancreas. A review and critical study of 100 cases. *Medicine* **38**: 47-84, 1959.
9. Doubilet, H.; Sage, H. H., and Mulholland, J. H.: The diagnosis of biliary-pancreatic cancer. *S. Clin. North America* **33**: 461-478, 1953.
10. Franco, S. C.: Carcinoma of the head of pancreas: a review of forty cases. *Am. J. Dig. Dis.* **8**: 65-69, 1941.
11. Bliss, W. R., and others: Symposium on pancreatic disease; localization of referred pancreatic pain induced by electric stimulation. *Gastroenterology* **16**: 317-323, 1950.
12. Hermann, R. E.: Current concepts in the surgical management of cancer of the pancreas and peripancreatic region. *M. Times* **94**: 571-584, 1966.
13. Kohn, L. A.: The behavior of patients with cancer of the pancreas. *Cancer* **5**: 328-330, 1952.

CARCINOMA OF THE PANCREAS

14. Fras, I., and Litin, E. M.: Mental symptoms in carcinoma of the pancreas. (Abs.) *Gastroenterology* **50**: 843, 1966.
15. Serebro, H.: A diagnostic sign of carcinoma of the body of the pancreas. *Lancet* **1**: 85-86, 1965.
16. Levy, H., and Lichtman, S. S.: Clinical characterization of primary carcinoma of the body and tail of the pancreas. *Arch. Int. Med.* **65**: 607-626, 1940.
17. Kenney, W. E.: The association of carcinoma in the body and tail of the pancreas with multiple venous thrombi. *Surgery* **14**: 600-609, 1943.
18. Elibol, T., and others: Evaluation of serum alkaline phosphatase values in differentiating hepatocellular from obstructive jaundice. In preparation.
19. Thompson, C. M., and Rodgers, L. R.: Analysis of the autopsy records of 157 cases of carcinoma of the pancreas with particular reference to the incidence of thromboembolism. *Am. J. M. Sci.* **223**: 469-478, 1952.
20. Burke, G., and Goldstein, M. S.: Radioisotope photoscanning in the diagnosis of pancreatic disease. *Am. J. Roentgenol.* **92**: 1156-1161, 1964.
21. Rodríguez-Antúnez, A., and others: Photoscanning in diagnosis of carcinoma of the pancreas. *Ann. Int. Med.* **65**: 730-737, 1966.