

Retrograde jejuno gastric intussusception

REVIEW OF THE LITERATURE AND REPORT OF A CASE

HIRSCH RASTOGI, M.B.B.S., M.D. (Medicine),*

Department of Gastroenterology

RALPH J. ALFIDI, M.D.,

Department of Hospital Radiology

ROBERT E. HERMANN, M.D.,

Department of General Surgery

CHARLES H. BROWN, M.D.

Department of Gastroenterology

RETROGRADE jejuno gastric intussusception occurs rarely after operations on the stomach. In the American literature only 45 cases have been reported. Although the complication was observed and described much earlier,¹ a report on the radiologic diagnosis was published in 1924.¹ On the basis of previously recorded cases, it has been established that retrograde jejuno gastric intussusception is a late complication of gastrojejunostomy or of a Billroth II anastomosis, predominantly of the latter procedure.² We believe that in view of the infrequency of reported instances of this complication after operations so commonly and widely performed, the report of a recent case is of special interest.

The declining incidence of cancer of the stomach in the United States,³ together with a trend toward a more physiologic operation for peptic ulcer disease will certainly make retrograde jejuno gastric intussusception even rarer than it has been to the present time.

REPORT OF A CASE

A 60-year-old Negro man who had undergone partial gastrectomy and Billroth II anastomosis for peptic ulcer in 1948, was first examined at the Cleveland Clinic Hospital in March 1965 because of a three-year history of recurrent episodes of bilious vomiting and abdominal distension, occurring every two or three weeks and lasting about four days. Frequent urination preceded emesis, which was accompanied and followed by epigastric pain. Between attacks he felt well, but he had lost 13 pounds during the course of his illness. His family history and a review of systems were noncontributory.

On examination, the patient was ill-nourished, dehydrated, and depressed, weighing only 125 pounds. There were generalized neurofibromatosis of the skin, and enlargement of the prostate gland.

* *Fellow, Department of Gastroenterology.*

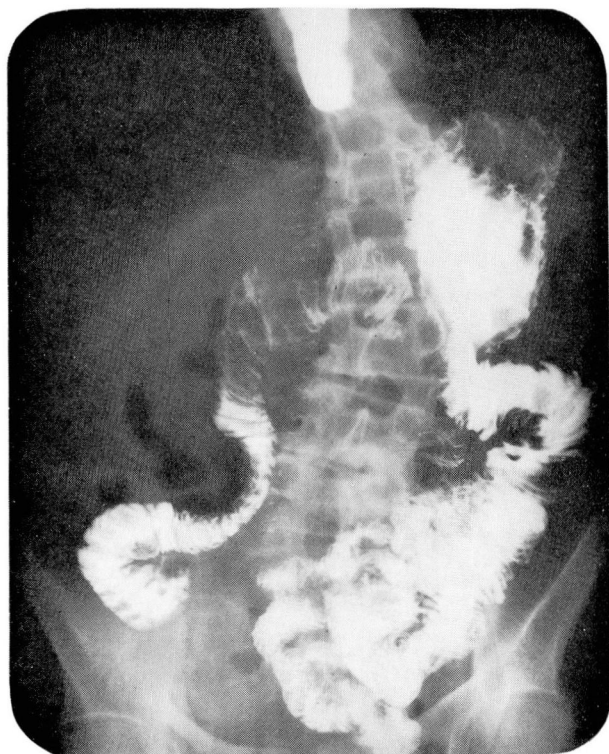

Fig. 1. A roentgenogram from a normal gastrointestinal series obtained in November 1966. This study was made after repeated episodes of vomiting, which were attributed to bile gastritis and psychogenic reaction.

A roentgenogram of the chest, a plain roentgenogram of the abdomen, and an upper gastrointestinal series of roentgenograms showed normal function, as did the intravenous and the retrograde pyelograms. No further episodes of vomiting occurred during the two weeks of observation in the hospital. Upon discharge from the hospital he was advised to follow a diet for dumping syndrome and to take vitamins. He was reexamined periodically, and by November 1, 1966, had experienced five episodes of persistent vomiting. At no time was he observed during one of these "spells." Bile gastritis and psychogenic reactions were considered to be contributory to the symptoms. An upper gastrointestinal roentgenogram in November 1966 revealed a normal gastrojejunostomy. The gastric remnant, stoma, and both loops appeared unremarkable (*Fig. 1*).

The patient was readmitted to the hospital on February 28, 1967, in a dehydrated state from persistent vomiting for two days. The vomitus was the color of coffee grounds. His temperature was 98 F, pulse rate 130, and blood pressure 102/76 mm Hg. The abdomen was normal. Laboratory studies consisted of determinations of: blood hemoglobin content, 15.6 g per 100 ml; cell volume, 45 percent; leukocyte count, 7,700 per cubic millimeter; urinalysis, traces of protein; and serum values—carbon dioxide, 21.6 meq per liter; chloride, 99 meq per liter; potassium, 3.9 meq per liter; sodium, 130 meq per liter; calcium, 9 mg per 100 ml; phosphorus, 5.8 mg per 100 ml; amylase, 600 units. A flat roentgenogram of the abdomen showed dilated loops of the small bowel in the right upper quadrant, and a fluid level in the stomach suggestive of obstruction of the efferent loop.

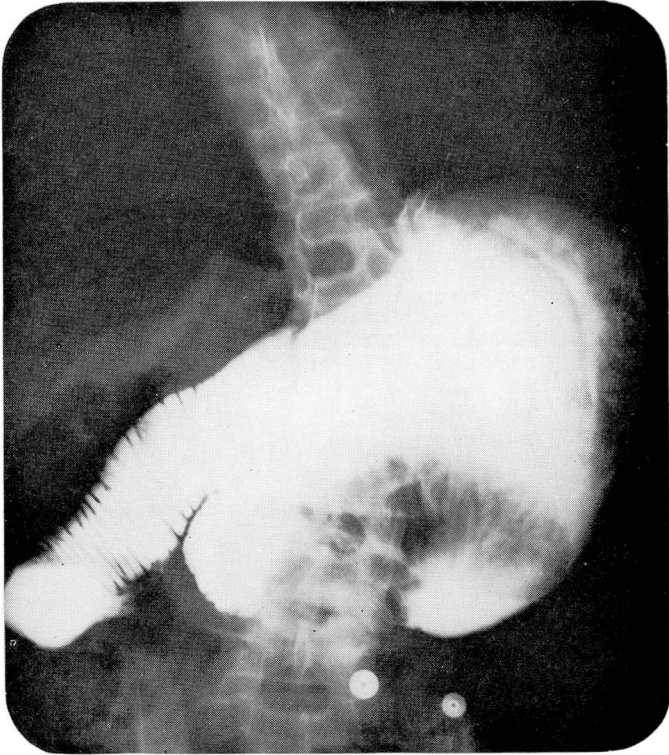


Fig. 2. A roentgenogram from a gastrointestinal series obtained on March 1, 1967, showing a loop of intestine in the dilated gastric remnant. The intussuscepted loop is characterized by a coiled-spring appearance; the afferent loop is dilated.

An electrocardiogram showed tachycardia, enlargement of the right atrium, and non-specific myocardial changes.

The patient was treated for upper gastrointestinal obstruction and electrolyte imbalance. The next morning, a gastrointestinal series of roentgenograms demonstrated an elongated sausage-shaped defect with a coiled-spring appearance in the distal portion of the gastric remnant. There was evidence of severe dilatation of the gastric remnant and afferent loop, but no filling of the efferent limb (Fig. 2).

A diagnosis of intussusception of the small bowel into the stomach was made, and on March 3, 1967, laparotomy was performed. At operation, the retrograde intussusception of the efferent loop into the gastric pouch had spontaneously reduced. Another intussusception, 12 inches from the ligament of Treitz (jejunojejunal), was found and reduced. Multiple neurofibromas were on the serosal surfaces of the stomach and intestines, and biopsy specimens were obtained. The jejunal intussusception was believed to have been caused by one of the neurofibromas, consequently nothing could be done to prevent recurrence of this problem.

The patient made a slow but uneventful recovery. The upper gastrointestinal roentgenogram made before he was discharged from the hospital is shown in Figure 3. The patient was readmitted to the hospital on April 17, 1967, because of symptoms suggesting recurrence of intussusception. A plain roentgenogram of the abdomen confirmed the

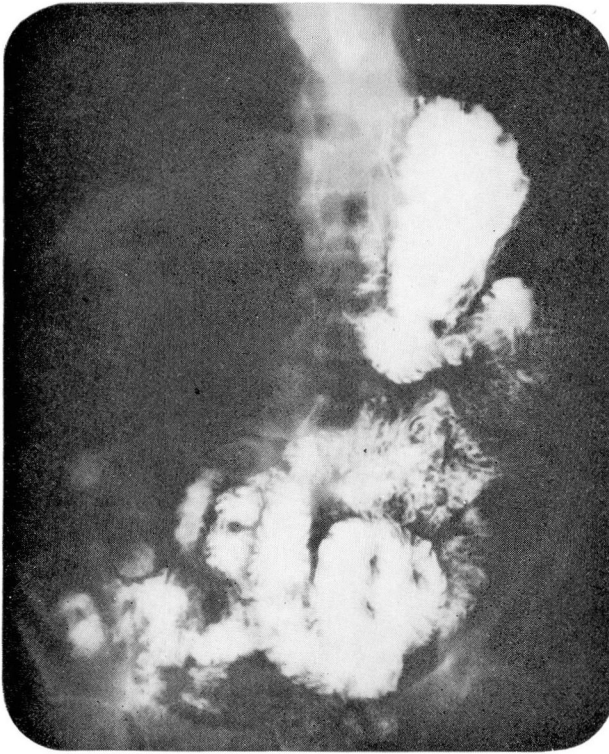


Fig. 3. A roentgenogram from the postgastroscopy gastrointestinal series showing a normal gastric remnant and efferent loop.

suspicion of upper gastrointestinal obstruction. Gastroscopy revealed a segment of small intestine in the stomach, but a subsequent gastrointestinal series of roentgenograms showed a normal anastomosis with free passage of barium, suggesting that reduction of intussusception took place during gastroscopic examination (*Fig. 3*).

DISCUSSION

Intussusception of a portion of the small bowel into the gastric remnant occurs rarely. The abnormal physiologic mechanism involved is not yet known. No organic lesion, such as an ulcer, a polyp, or a tumor, has generally been thought to initiate invagination. According to Palmer,¹ Amberger reported a case in which a fibroma on the jejunum was noted at operation, but this did not involve the stoma. Although several neurofibromas were noted on the serosal surface of the stomach and jejunum in the patient treated, their role in the causation of the jejunogastric intussusception is open to question; none were present in the region of anastomosis. The distal, jejunojejunal intussusception did appear to be caused by one of the neurofibromas.

Shackman⁴ classified jejunogastric intussusception into three categories: type 1, in which the afferent loop intussuscepts into the stomach; type 2 in which the efferent loop invaginates; and type 3 in which both loops intussuscept. Type 3 generally occurs in the early postoperative period; whereas types 1 and 2 seem to occur many months or years after operation. Our case fits the type 2 category. The patient remained well for 12 years after operation, and symptoms of intermittent high obstruction developed subsequently, which were attributed variously to dumping syndrome, recurrent ulceration, bile gastritis, and psychogenic reaction.

Chamberlin⁵ believed there were two modes of presentation characteristic of jejunogastric intussusception. The presenting symptoms of fulminant cases of acute upper gastrointestinal obstruction are abdominal pain, vomiting, and the attendant effects of electrolyte and fluid deficit. Hematemesis is frequent because of gangrene of the jejunum, and leads ultimately to shock. In such cases, prompt surgical intervention is the treatment of choice. In chronic cases, usually there is a long history of intermittent symptoms, as exemplified by the patient we treated, though he had several acute episodes also, which subsided with spontaneous reduction. Only his final episode was accompanied with hematemesis.

Foster⁶ suggested that a palpable mobile epigastric mass associated with manifestations of upper gastrointestinal obstruction in a patient who previously underwent operation is diagnostic of retrograde intussusception. Nonetheless, the diagnosis remains elusive due to clinicians' lack of awareness of this complication.

Roentgenographic findings are diagnostic when an upper gastrointestinal series is made during the episode. The diagnosis in the case reported here would not have been established without such evidence. Wisoff⁷ commented on the typical coiled-spring appearance of a filling defect in the stomach because of the Kerckring's valves of the small bowel. Aleman⁸ reported one case, and from a review of 65 reported cases found that this appearance applied to 85 percent of patients with retrograde jejunogastric intussusception. In addition, dilatation of the gastric remnant is often prominent in acute cases. Diagnosis can be confirmed by gastroscopy. Palmer¹ stated that invagination of jejunal mucosa through the stoma in these cases is readily recognized. Secondary changes due to intestinal strangulation, gangrene, and obstruction can also be identified.

Caudell and Lee⁹ reported two cases, and believed that many cases of chronic intermittent jejunogastric intussusception are never recognized. They stressed barium contrast roentgen studies in the presence of active symptoms.

The cause and mechanism of the development of retrograde intussusception are still a matter of conjecture. Indeed, one would more often expect

to find the reverse—prolapse of the gastric mucosa into the jejunum. Various mechanical and functional factors have been proposed as causes. The site of anastomosis or the size of the stoma has no correlation with the cases that have been reported. According to Reyelt and Anderson,² the stomas in reported cases have ranged in size from 2 to 5 cm. Occurrence of adhesions in the vicinity of the stoma,⁸ a lengthy afferent loop or a mobile efferent loop² have been suggested as precipitating causes, but remain unconfirmed. Segmental spasm in the proximal jejunum and retrograde peristalsis have been mentioned as inducing intussusception. However, the underlying factors that occasion such neuromuscular incoordination and motility disorders have not been elucidated with certainty.

The roles of diet, gastric acidity, and the dumping phenomenon, individually or collectively, have been questioned. Aleman⁸ reviewed two cases in which the patients were addicted to morphine, which presumably caused spasm. A thick, contracted mesocolon⁸ has also been suggested as a probably predisposing factor. According to Wisoff,⁷ Dunlop reported a case of acute intussusception that was associated with a perforated jejunal diverticulum. The latter may well have caused sufficient spasm and reverse peristalsis to result in invagination of the jejunum into the gastric remnant.

The importance of a high index of suspicion on the part of the clinician is emphasized by mortality figures cited by Lawson and Whitener.¹⁰ Retrograde jejuno gastric intussusception resulted in death of all patients who did not receive surgical treatment.

SUMMARY

Retrograde jejuno gastric intussusception is an infrequent and often undiagnosed complication of gastric surgery. The literature has been briefly reviewed and a recent new case has been presented. The initial symptoms are those of upper gastrointestinal obstruction in a patient who has previously undergone a gastric resection. Prompt recognition of this condition is necessary, since there is a high mortality rate without surgical intervention.

REFERENCES

1. Palmer, E. D.: Retrograde intussusception at the gastrojejunal stoma: two cases and a bibliography. *Am. J. Dig. Dis.* **21**: 309-313, 1954.
2. Reyelt, W. P., Jr., and Anderson, A. A.: Retrograde jejuno gastric intussusception. *Surg. Gynec. Obstet.* **119**: 1305-1311, 1964.
3. Hoerr, S. O., and Hodgman, R. W.: Carcinoma of the stomach; an interpretive review. *Amer. J. Surg.* **107**: 620-636, 1964.
4. Shackman, R.: Jejuno gastric intussusception. *Brit. J. Surg.* **27**: 475-480, 1940.
5. Chamberlin, G. W.: Chronic recurrent jejuno gastric intussusception through a gastroenterostomy stoma. *Amer. J. Surg.* **49**: 510-512, 1940.

RETROGRADE JEJUNOGASTRIC INTUSSUSCEPTION

6. Foster, D. G.: Retrograde jejunogastric intussusception—a rare cause of hematemesis; review of the literature and report of two cases. *A.M.A. Arch. Surg.* **73**: 1009–1017, 1956.
7. Wisoff, C. P.: Jejunogastric intussusception. *Radiology* **61**: 363–367, 1953.
8. Aleman, S.: Jejuno-gastric intussusception, a rare complication of the operated stomach. *Acta Radiol.* **29**: 383–395, 1948.
9. Caudell, W. S., and Lee, C. M., Jr.: Acute and chronic jejunogastric intussusception. *New Eng. J. Med.* **253**: 635–640, 1955.
10. Lawson, E. H., and Whitener, D. L.: Retrograde jejunogastric intussusception; report of a case. *Arch. Surg.* **60**: 242–246, 1952.