

# Pharyngoesophageal diverticulum in each of three sisters

## REPORT OF CASES

LAURENCE K. GROVES, M.D.

*Department of Thoracic and Cardiovascular Surgery*

**P**HARYNGOESOPHAGEAL diverticulum (Zenker's diverticulum) is familiar to all surgeons interested in esophageal problems. It is ordinarily not seen in younger than middle-aged patients, and it is considerably commoner in males than in females. In Shallow and Clerf's<sup>1</sup> series of 186 patients, 78 percent were males and 22 percent were females. The series of Finney and Gaertner<sup>2</sup> comprised 36 males and 11 females. My personal series of patients comprises 35 males and 12 females (including two of the females of this report). It was a great surprise, therefore, when a 63-year-old woman recently told me that she was sure she had a cervical diverticulum and that she wanted surgical treatment because her sister had done so well after I resected her diverticulum. The woman did indeed have a pharyngoesophageal diverticulum, as had had her sister. When I told her that this in my experience was distinctly unusual, as I could not recall personally encountering the condition in more than one member of a family, nor could I remember other reports of familial incidence, she stated that in her family it must be familial, as a third sister had also had the same condition. A review of records confirmed that in 1949, Robert S. Dinsmore, M.D. (now deceased), of this institution, had operated on the third sister when she was 51 years old.

There were five sisters and two brothers in that family. In addition to the three sisters with proved diverticula, a deceased brother also may have had such a diverticulum. A letter from one of the sisters states:

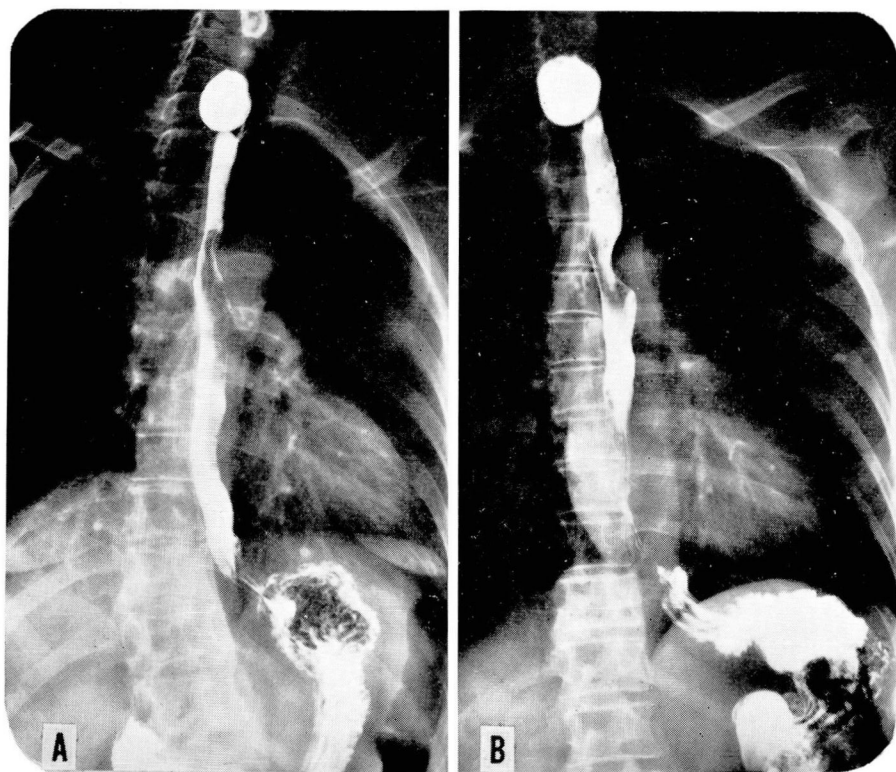
"My brother . . . passed away last June. When I visited him in the hospital a few days before his death he told me about his difficulty in swallowing. After describing his symptoms I felt quite sure he had the same thing I had."

Investigation of his hospital records reveals that no barium studies were ever performed; his physician is deceased; and unfortunately the suggested diagnosis cannot be substantiated. The same sister stated that her oldest sister recalls hearing their father say that his mother had "starved to death," presumably from difficulty in swallowing. No other swallowing problems in this family are known to their relatives.

## REPORT OF CASES

**Case 1.** A 51-year-old woman was examined at the Cleveland Clinic in June 1949, because three years previously she had noted the abrupt onset of difficulty in swallowing. She indicated that food stuck at the level of the sternal notch, the sensation of obstruction being to the left of the midline. The symptoms had been somewhat progressive, and portions of meat and lettuce caused the most difficulty. She had noted regurgitation of food eaten as long as three days previously. Roentgenograms, which showed a typical pharyngo-esophageal diverticulum, resulted in her referral to Dr. Robert S. Dinsmore. His operative report (in 1949) states that a typical diverticulum was found in the normal location.

**Case 2.** A 64-year-old woman (sister of the patient in case 1) was examined at the Cleveland Clinic in 1966. She had first had difficulty, swallowing pills, approximately five years previously. The amount of mucus in the throat had been gradually increasing, and she had been progressively avoiding solid foods. About six months before examination at the Cleveland Clinic, roentgenograms had demonstrated a diverticulum, and subsequent to that time the patient lived on a diet of baby food. Current roentgenograms showed a moderately sized diverticulum (*Fig. 1A*). In September 1966, she underwent surgical treatment. Exposure was via the left half of a thyroidectomy scar, and a typical diverticulum was exposed and resected. The patient has been asymptomatic since the operation.



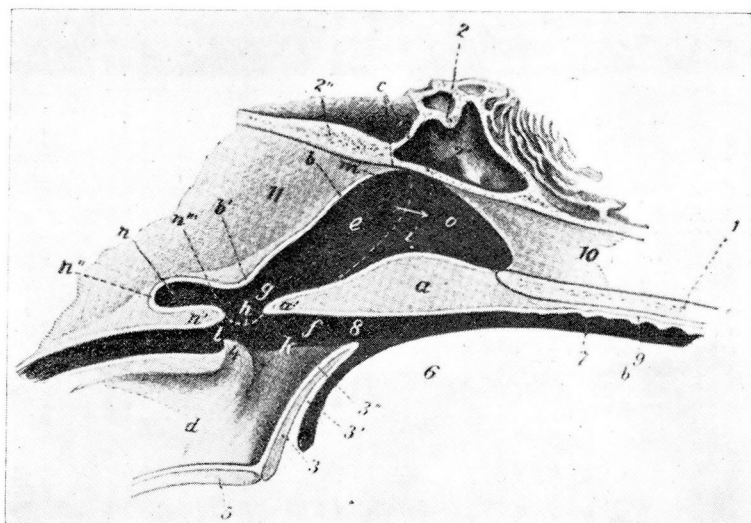
**Fig. 1.** A and B show barium esophagograms, A, of patient 2, and B, of patient 3. Typical pharyngo-esophageal diverticula are present in the usual location.

**Case 3.** A 63-year-old woman (sister of the patients in cases 1 and 2) was examined in 1967 because for several years she had noted increasing regurgitation of food, in association with the feeling of food getting stuck in her throat. Her diet subsequently consisted chiefly of ground-up and soft foods. Associated with the swallowing problems had been some recent increase in coughing, suggestive of recurrent aspiration. She also had epigastric distress after meals, and heartburn. Roentgenographic studies approximately nine months previously were said to have shown evidence of a diverticulum. Current roentgenograms confirmed the presence of a diverticulum (*Fig. 1B*) and also a small esophageal hiatus hernia. Resection of the diverticulum was performed. This patient is the one who first called my attention to her sisters, and, in view of the known family history, the operative field was inspected with extreme care, but no unusual features were detected. Results of the pathologic examination of the sac were not remarkable. It was a false diverticulum, consisting of mucosa without muscular coats. In accordance with Belsey's<sup>3</sup> concept of pharyngoesophageal diverticulum, a small myotomy was performed immediately distal to the site of the diverticulum in this patient, as has been done in all recent similar cases. The patient has been asymptomatic postoperatively.

### DISCUSSION

The history of each of these three women is typical for pharyngoesophageal diverticulum. In each patient the symptoms developed during middle age, and there is nothing to suggest that these were congenital diverticula. There are sporadic case reports<sup>4, 5</sup> of congenital cervical diverticula that have been diagnosed because of swallowing problems in the newborn, with symptoms analogous to those in infants with esophageal atresia and tracheoesophageal fistula. It is apparent that although the family of the three sisters must have a congenital "susceptibility" to pharyngoesophageal diverticulum, there is no evidence that any of these women were born with a diverticulum.

In the course of reviewing medical writings for further information on the familial occurrence of this problem, the following fascinating statement was found in Jackson and Jackson's<sup>6</sup> textbook. They proposed that the etiology of hypopharyngeal diverticulum, is related to an atavistic anatomic muscular weakness, and stated: "This weak point . . . corresponds roughly with the orifice of a pouch that is normal or is a common anomaly in wild and domesticated species of hog, the peccary, sloth, anteater, bat, and some other animals." Unfortunately, this statement is not documented. The authors<sup>6</sup> were probably referring to the paper by Raven<sup>7</sup> in 1933. However, Raven<sup>7</sup> stated: "There is no evidence that the structure is atavistic in origin. Some authorities have likened it to the pouch which occurs in the domestic pig, but the morphology of this structure is entirely different." He stated: "It is a large sac passing downward and backward from the lower end of the nasopharynx . . . It is clear that the morphology of this pouch is entirely different from the posterior pulsion pouch in man." Raven<sup>7</sup> reviewed his findings in various animals. The paper includes a drawing of a specimen in the museum of the Royal College of Surgeons, showing two diverticula arising from the posterior pharyngeal wall of a sloth bear. These diverticula are side by side and one is distinctly larger than the other. No mention is made of the fre-



**Fig. 2.** Partly schematic sagittal section of pharyngeal region of a domestic pig, showing the location of the diverticulum. The mouth is to the right and the mediastinum to the left; *e* indicates the nasopharynx, *a*, the soft palate; 3, the epiglottis; *d*, the larynx; *l*, the opening to the esophagus; and *n*, the diverticular sac. (Courtesy of W. B. Saunders Company, Sisson, S. (revised by Grossman, J. D.): *The Anatomy of the Domestic Animals*, 3d ed., 1938, p. 489.)

quency of this occurrence. In a single dissection of a giant anteater, Raven found a pharyngeal pouch; however, it was anterior and not posterior to the pharynx and is clearly not related to the subject at hand. As for the fruit bat, in describing the diverticulum, Raven stated: "This animal spends many hours hanging head downwards from trees, and since there is no sphincter at the lower end of the oesophagus, fluid runs up the tube, but is prevented from entering the pharynx by the strong sphincter at the junction of pharynx with oesophagus. Hence the pouch is a pressure pouch..." Clearly, then, this pouch is in no way analogous to a pharyngoesophageal diverticulum.

After surveying the literature I am not able to state just how common anomalies of this type are in other animal species, except that the diverticulum of the pig, whether or not it is analogous, is evidently a normal structure (*Fig. 2*). Veterinarians generally know of it, but it is apparently of little pathologic significance, and few are truly familiar with it. I have been unable to ascertain whether or not it is a structure that is invariably present. The personal dissection of four pigs revealed its presence (*Fig. 3*) in each animal.

Negus<sup>8</sup> offers the following explanation for the absence of pathologic significance of the diverticulum in the pig: "... it is a hernial sac similar to the pharyngeal pouch of man ... The sac is uncovered by muscle fibres, but is not of pathological interest, because it lies above the arcus-palato-pharyngeus."



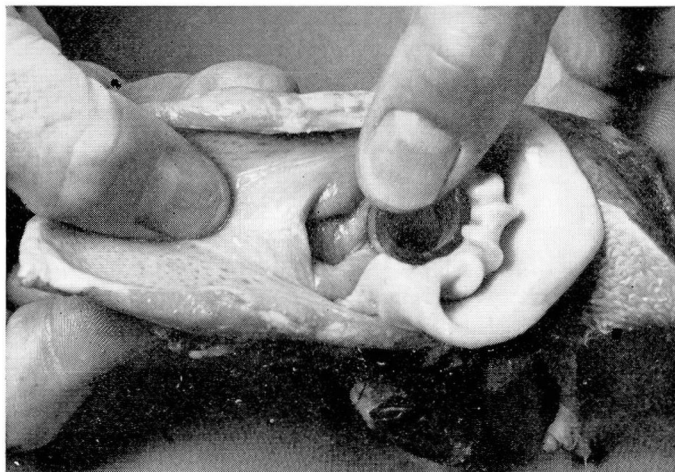


Fig. 3. Photograph of a pig's pharynx dissected by the author. The pharynx is being held open just above the level of the larynx, which is seen on the right. The segment of plastic tube is held in place in the orifice to the esophagus, and the opening of the diverticulum is quite apparent to the left of the esophageal opening.

ryngeus, and is therefore in the naso-pharynx." During swallowing, the nasopharynx becomes isolated from the oropharynx, and is not, thereby, subject to increased luminal pressure by the swallowing act. This being the case, there is no reason why the diverticulum of the pig should progressively enlarge, as does the one occurring in man.

Although the statement quoted above may be usually true, the following quotation from Jubb and Kennedy<sup>9</sup> would indicate that on occasion the diverticulum of the pig can behave much as does the diverticulum in man: "In young pigs, awns of barley and other foreign bodies of similar type occasionally lodge in the diverticulum and cause inflammation thereof." They go on to say that such animals can die of starvation or mediastinitis.

A pharyngeal recess is also present in equine species. Sisson and Grossman<sup>10</sup> describe it as follows: "Behind the Eustachian openings there is a median cul-de-sac, the **pharyngeal recess** (*Recessus pharyngeus*). The recess is somewhat variable, but is usually about an inch in depth and will admit the end of the finger. In the ass and mule it is much deeper." I have not had the opportunity to dissect an equine, but this recess lies in the nasopharynx and thus is not analogous to a pharyngoesophageal diverticulum.

Further review of the literature in anatomy, embryology, and comparative aspects has not yielded pertinent material. There is frequent mention of pouches related to development of the branchial arch system, but these are not midline structures and are not germane to posterior midline diverticula. It remains a moot point that the pharyngoesophageal diverticulum of man

can in any sense be considered atavistic. It can be stated that outpouchings in the midline of the posterior pharyngeal wall at various levels are seen in various mammalian species. This suggests that there may indeed be some common developmental basis for a weakness in this region.

In man, it is generally agreed that these are pulsion of diverticula. For pulsion to cause a diverticulum, two factors may play roles. The first factor is an overdeveloped constrictor muscle, or perhaps more accurately, an in-coordinated sphincter muscle, which will cause excessive pharyngeal pressure during swallowing, and lead to a "blowout." The other factor is that of an anatomic weakness in the posterior musculature at the pharyngoesophageal junction. Claggett<sup>11</sup> has emphasized this weakness: "... constant site of origin of these diverticula at the posterior-wall junction of the pharynx and cervical esophagus indicates that there must be a congenital weakness here in some persons."

The familial occurrence of pharyngoesophageal diverticulum reported here is not unique; at least four additional instances have been reported. Sparks<sup>12</sup> in 1933 reported a case of a large pharyngoesophageal diverticulum containing a carcinoma. He stated that the father of the patient died at the age of 75 years, with a pharyngeal pouch; a paternal uncle died at the age of 75 years, with a pharyngeal pouch; a paternal uncle died at the age of 76 years of a pharyngeal pouch; and a cousin was stated to be alive with the same condition. Dinsmore<sup>13</sup> in 1942 reported the occurrence of pharyngoesophageal diverticulum in two brothers aged 61 and 51 years. Dunhill<sup>14</sup> in 1950 reported having operated upon a patient who had a diverticulum containing carcinoma, and that the patient's brother had also been operated upon for a diverticulum. His report also stated that the father and grandfather of those two brothers both died from a similar condition, and that two other relatives each suffered from a pharyngeal diverticulum. In the fourth reference to familial occurrence, Björk<sup>15</sup> in 1952 reported the cases in a family (strikingly similar to the one reported here). In that family, three sisters with diverticula were examined: one 68 years old who had symptoms for one year, one 67 years old who had symptoms for one month, and one 60 years old who had symptoms for 14 years. In addition, the mother also is said to have had a diverticulum, according to the history related by her daughters.

### CONCLUSIONS

Including the family of the patients reported here, five different families with multiple occurrences of pharyngoesophageal diverticulum have been reported.<sup>12-15</sup> None of these patients gave a clinical history consistent with the presence of the diverticulum since birth. Claggett<sup>11</sup> stated: "... there must be a congenital weakness here in some persons." It would seem appropriate that this statement be modified to the effect that there must be a

congenital weakness in some families. Björk<sup>15</sup> nicely summarized the dynamics causing these diverticula, pointing out that the pressure in the pharynx must be too great for the strength of the pharyngeal wall: "... *whether this pressure is abnormally great because of increased obstruction at the mouth of the oesophagus, or whether this pressure keeps within normal limits, being nevertheless—for instance due to a congenital anatomic peculiarity—too strong for the weak wall.*"

In the families in question there must exist an inherited congenital anomaly. This anomaly either could be anatomic and related to the structure of the posterior hypopharyngeal wall, or it could be neuromuscular and related to the control and coordination of the superior esophageal constrictor mechanism.

#### ACKNOWLEDGMENTS

The author is grateful to Frank Coy, D.V.M., for his help in finding references in the veterinary writings, and to Howard Teague, D.V.M., for providing the pig material for dissection.

#### REFERENCES

1. Shallow, T. A., and Clerf, L. H.: One stage pharyngeal diverticulectomy; improved technique and analysis of 186 cases. *Surg. Gynec. Obstet.* **86**: 317–322, 1948.
2. Finney, G. G., Jr., and Gaertner, R. A.: Surgical treatment of pharyngo-esophageal diverticula. *South. Med. J.* **57**: 375–378, 1964.
3. Belsey, R.: Functional disease of the esophagus. *J. Thorac. Cardio. Surg.* **52**: 164–188, 1966.
4. Brintnall, E. S., and Kridelbaugh, W. W.: Congenital diverticulum of the posterior hypopharynx simulating atresia of the esophagus. *Ann. Surg.* **131**: 564–574, 1950.
5. Nelson, A. R.: Congenital true esophageal diverticulum; report of a case unassociated with other esophagotracheal abnormality. *Ann. Surg.* **145**: 258–264, 1957.
6. Jackson, C., and Jackson, C. L.: *Bronchoesophagology*. Philadelphia: W. B. Saunders Co., 1950, 366 p.; p. 285.
7. Raven, R. W.: Pouches of the pharynx and oesophagus with special reference to the embryological and morphological aspects. *Brit. J. Surg.* **21**: 235–256, 1933.
8. Negus, V. E.: Evolutionary factors in the production of pharyngeal diverticula. *J. Laryng.* **40**: 702–724, 1925.
9. Jubb, K. V. F., and Kennedy, P. C.: *Pathology of Domestic Animals*, vol. 1. New York: Academic Press, 1963, 477 p.; p. 124.
10. Sisson, S.: *The Anatomy of the Domestic Animals*, 4th ed. revised by Grossman, J. D. Philadelphia: W. B. Saunders Co., 1953, 972 p.; p. 409; also 3d ed., 1938, p. 489.
11. Claggett, O. T.: Pharyngo-esophageal diverticula. *Surg. Clin. N. Amer.* **43**: 1165–1169, 1963.
12. Sparks, J. V.: Case notes. Report of a case of pharyngeal diverticulum containing a neoplasm in its walls. *Brit. J. Radiol.* **6**: 233–236, 1933.

13. Dinsmore, R. S.: Diverticulum of the esophagus; report of two cases. *Cleveland Clin. Quart.* **9**: 187-192, 1942.
14. Dunhill, T.: Pharyngeal diverticulum. *Brit. J. Surg.* **37**: 404-415, 1950.
15. Björk, H.: Pathogenesis of hypopharyngeal diverticulum with special reference to heredity. *Acta Otolaryng.* **42**: 202-207, 1952.