

# Surgery of the foot in rheumatoid arthritis

ALAN H. WILDE, M.D.

Department of Orthopedic Surgery

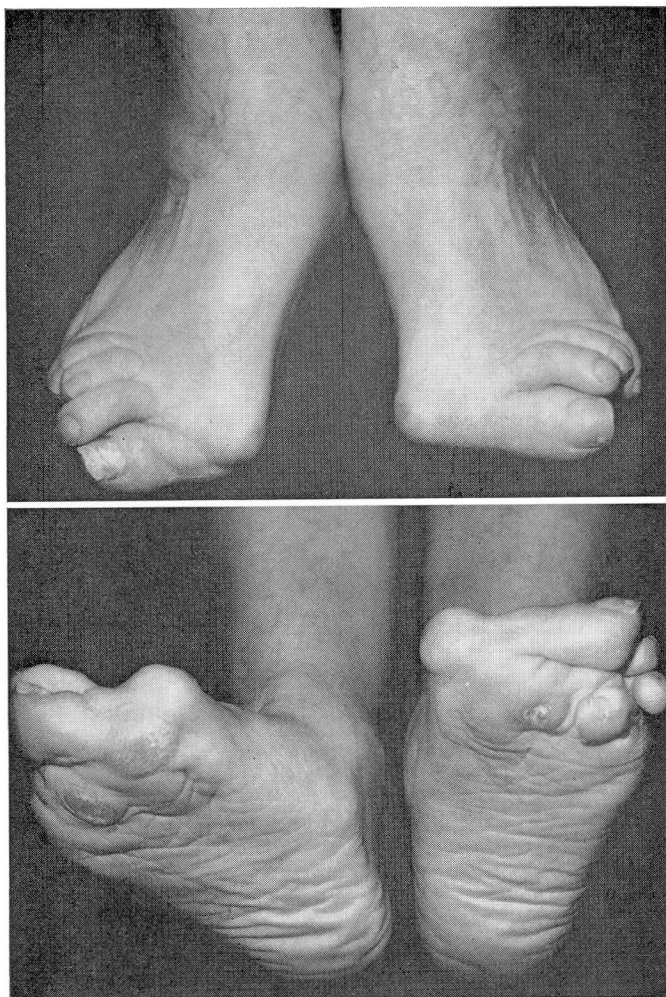
**T**HE foot has been a long-neglected area in medicine, yet foot disorders, especially in association with rheumatoid arthritis, are common. Rheumatoid arthritis usually begins in the forepart of the foot, and the metatarsophalangeal joint often is the earliest joint in the body to demonstrate the characteristic erosion of bone.

## Pathogenesis of deformity in the foot

There is early spreading of the forepart of the foot as the synovitis of the metatarsophalangeal joints distends the joint capsules and stretches the intermetatarsal ligaments. The intrinsic musculature may become affected, and has been shown by Duchenne<sup>1</sup> to flex the metatarsophalangeal joints and to extend the interphalangeal joints. When the long flexors of the toes contract on the straight toes, they sling the heads of the metatarsals and prevent the forepart of the foot from dropping. He demonstrated that in the absence of function of lumbricales, the long flexors pull the toes into flexion; the metatarsal heads are no longer supported; and the proximal phalanges become dorsiflexed at the metatarsophalangeal joint, and the interphalangeal joints become flexed. The same mechanism is thought to be operating in the rheumatoid foot. Synovitis of the metatarsophalangeal joints furthers the dislocation of those joints and of the flexor tendons into the region between the metatarsal heads. When this occurs the metatarsal heads protrude into the sole of the foot; the fat pad atrophies; and calluses develop beneath the metatarsal heads and on the dorsa of the interphalangeal joints (*Fig. 1*). The patient experiences much discomfort while walking and wearing shoes. As the deformities worsen, the fitting of shoes becomes more difficult and the patient obtains shoes that are longer and wider than his usual size in an effort to accommodate the deformed toes.

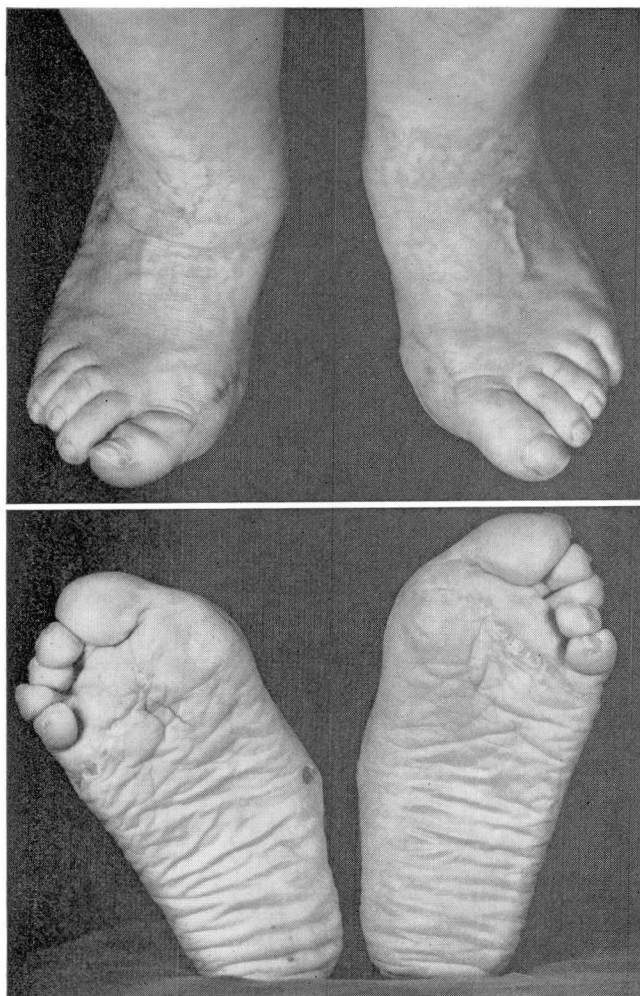
## Surgical treatment

In far-advanced cases of foot deformity, when conservative measures have failed to provide relief of pain, operation is indicated. As there usually is deformity at many joints, the entire forepart of the foot must be reconstructed. When three or more metatarsophalangeal joints have deformities, I have employed the Hoffmann operation.<sup>2, 3</sup> This technic consists of resecting all the metatarsal heads, from a plantar incision. A separate medial incision is used for removing the first metatarsal head. The fat



**Fig. 1.** Photos of the feet of a 61-year-old woman who had rheumatoid arthritis of 30 years' duration, with progressive deformity and pain in the foreparts of both feet making ambulation difficult.

pad is relocated proximally, by excision of an ellipse of skin which usually includes calluses and any scars from previously draining sinuses. The toes can then be straightened by manipulation. A severe flexion deformity at the proximal interphalangeal joint may require arthrodesis of that joint. A Kirschner wire is inserted across the metatarsophalangeal joint of the great toe and is allowed to remain in place for three weeks. Weight-bearing is usually allowed on the fifth postoperative day, with the patient walking on the heel of the affected foot. As the foot becomes more comfortable, progressive weight-bearing is allowed. The wound may



**Fig. 2.** Postoperative (8 months) photos of the feet shown in *Figure 1*. The patient has had relief of pain, is able to stand on her toes, and her shoes are much more comfortable.

be slow to heal and the sutures remain in place for three weeks. Postoperatively, there is usually good relief of pain and the patient can wear shoes his own usual size or smaller (*Fig. 1 and 2*). No patient has had pain in the foot as a result of placement of the incision.

Occasionally a patient's toes are so severely contracted and rigid that dislocations of the middle and distal joints of the toes occur, especially of the interphalangeal joint of the great toe. When it is apparent that these deformities cannot be corrected by resection of only the metatarsal head, and that more than one or two of the toes will need to be reconstructed also, amputation of all toes through the metatarsal heads is



recommended. This latter operation is preferable to leaving toes that still will be painful and callused, unless the patient has a strong desire for cosmetic reasons to retain the toes and is willing to endure some continuing minor problems with them.

In patients with only a symptomatic hallux valgus, a Keller arthroplasty with synovectomy of the metatarsophalangeal joint is appropriate therapy.<sup>4, 5</sup> This procedure consists of resection of the proximal half of the proximal phalanx and the exostosis on the medial aspect of the first metatarsal head. A single hammertoe may be corrected by interphalangeal joint arthrodesis. Dislocation of a single metatarsophalangeal joint is corrected by resection of the base of the proximal phalanx, and condylectomy of the metatarsal head.

Early in the course of rheumatoid arthritis a patient may have a Morton's neuroma.<sup>6</sup> This is most common in the rheumatoid foot, and should be considered when the patient has pain in the forepart of the foot. The neuroma is recognized by the symptom of burning pain in the forepart of the foot, usually in the region of the third and fourth metatarsal heads. Pain is commonly aggravated by standing or walking, and wearing shoes. The typical history is that the patient has a severe pain in the forepart of the foot when walking, and it feels as though walking on a marble, there were a stone in the shoe, or as though the sock or stocking were wrinkled. The patient usually stops walking, removes the shoe and rubs the foot, whereupon the pain subsides.

On physical examination with deep palpation there usually is exquisite tenderness in the sole of the foot usually between the third and fourth metatarsal heads, which reproduces the patient's symptoms. Compression of the metatarsal heads might also cause pain, and there may be a click as the neuroma slips between the metatarsal heads. Sensation of the adjacent borders of the third and fourth toes may be diminished. Morton's neuromas sometimes develop in other webbed spaces. The usually recommended treatment is an injection of hydrocortisone about the nerve. Should the symptoms persist after two injections of hydrocortisone, operative removal is indicated.

A more unusual nerve compression complex is the tarsal tunnel syndrome. This is characterized by numbness, a burning sensation, or paresthesias in the sole of the foot, symptoms that may progress to complete anesthesia. The symptoms at first may be intermittent, related to standing or walking and be relieved by rest, but may then become constant. There is sensory loss in the distribution of the posterior tibial nerve, i.e., in the sole of the foot including the plantar and dorsal aspects of the toes. Percussion over the posterior tibial nerve at the medial malleolus may produce paresthesias in the sole of the foot—Tinel's sign.<sup>7-9</sup> On a pathophysiologic basis, the patient with rheumatoid arthritis has an excellent chance that the tarsal tunnel syndrome will develop. Synovitis of the posterior tibial, flexor digitorum longus, and flexor hallucis longus

tendons may compress the posterior tibial nerve in the same way that the median nerve is compressed at the wrist by synovitis of the flexor tendons in the carpal tunnel syndrome. A determination of the conduction time of the posterior tibial nerve may be made to test the diagnosis. When the patient fails to respond satisfactorily to two or three injections of hydrocortisone beneath the flexor retinaculum, surgical release of the retinaculum and synovectomy of the affected tendons are indicated.

Rheumatoid arthritis may involve the subtalar joint and cause pain in the hind part of the foot when walking, especially when walking on uneven ground. A progressive valgus deformity may develop which results in flattening of the longitudinal arch. When rheumatoid arthritis has been of short duration, there may be synovitis of the subtalar joint, which usually appears in conjunction with synovitis of the peroneal tendons. Conservative measures are first tried, and when they do not provide symptomatic relief, synovectomy of the peroneal tendons and the subtalar joint may relieve the patient of pain in the hind part of the foot in the early phases when there is little radiographic evidence of destruction of the subtalar joint. When arthritis of long duration has caused damage to the subtalar joint in a symptomatic foot, a triple arthrodesis may be successfully performed.<sup>10</sup>

### Summary

Painful deformities of the foot are common in patients who have rheumatoid arthritis, and should be corrected surgically after conservative measures have failed to provide relief of pain. Patients generally rate the results of these operations as the most successful of all the surgery performed as the treatment of rheumatoid arthritis. The appropriate procedures and their indications have been outlined.

### References

1. Duchenne, G. B.: *Physiology of Motion*. (Translated by E. B. Kaplan.) Philadelphia: W. B. Saunders Co., 1959, 612 p.; p. 382-385.
2. Hoffman, P.: An operation for severe grades of contracted or clawed toes. *Amer. J. Orthop. Surg.* 9: 441-449, 1911-1912.
3. Clayton, M. L.: Surgery of the lower extremity in rheumatoid arthritis. *J. Bone Joint Surg.* 45-A: 1517-1536, 1963.
4. Keller, W. L.: The surgical treatment of bunions and hallux valgus. *New York Med. J.* 80: 741-742, 1904.
5. Marmor, L.: Surgery of the rheumatoid foot. *Surg. Gynec. Obstet.* 119: 1009-1012, 1964.
6. Morton, D. J.: *The Human Foot; Its Evolution, Physiology and Functional Disorders*. New York: Columbia University Press, 1935, 244 p.; p. 211.
7. Keck, C.: The tarsal-tunnel syndrome. *J. Bone Joint Surg.* 44-A: 180-182, 1962.
8. Kopell, H. P., and Thompson, W. A. L.: Peripheral entrapment neuropathies of the lower extremity. *New Eng. J. Med.* 262: 56-60, 1960.
9. Lam, S. J. S.: A tarsal-tunnel syndrome. *Lancet* 2: 1354-1355, 1962.
10. Marmor, L.: *Surgery of Rheumatoid Arthritis*. Philadelphia: Lea & Febiger, 1967, 261 p.; p. 221-224.