

Congenital hepatic fibrosis of Riedel's lobe causing portal hypertension

REPORT OF A CASE

RICHARD G. FARMER, M.D.

Department of Gastroenterology

ROBERT E. HERMANN, M.D.

Department of General Surgery

B. H. SULLIVAN, JR., M.D.

Department of Gastroenterology

CONGENITAL hepatic fibrosis is a rare but important cause of portal hypertension in children;¹⁻⁶ it is even more rare as a cause of portal hypertension in adults. Parker¹ reported two patients 33 years of age whom he studied, and the case of a patient 50 years old seen by Melnick;⁷ and McCarthy, Baggenstoss, and Logan³ reported five patients in whom portal hypertension, secondary to congenital hepatic fibrosis, became apparent in adult life. Because of the development of portal hypertension and the dangers of hemorrhage from gastroesophageal varices,⁸ the selection of patients for portal-systemic shunt procedures⁹ is of considerable importance. The excellent response to portal-systemic shunt for relief of the portal hypertension, and the fact that liver function usually remains good, signify that congenital hepatic fibrosis often has a favorable prognosis.

We recently treated an elderly man in whom bleeding developed from gastroesophageal varices secondary to portal hypertension and congenital hepatic fibrosis. An interesting and unique feature of the case was that the hepatic fibrosis involved only Riedel's lobe. While Riedel's lobe is the most common lobar deformity of the liver,¹⁰ its association with congenital hepatic fibrosis and portal hypertension has not, to our knowledge, been previously reported.

Report of a case

A 64-year-old man was admitted to the Cleveland Clinic Hospital on December 26, 1968, because of melena. He had been well until June 1968, when he began to note occasional tarry bowel movements. There had been no diarrhea, abdominal pain, or other symptoms; there was no history of jaundice. He said he did not drink alcoholic beverages and only rarely used aspirin. He did not take other medications and had had no previous surgical procedures. His only illness of any significance was said to be "typhoid fever" in 1928. In his family history, no comparable illness was known and there was no history of congenital abnormality.

On the evening of December 13, 1968, intermittent sharp epigastric pain without radiation developed, and the next morning he had a syncopal episode. He was admitted to the local hospital as an emergency patient, and his blood hemoglobin was found to be 7.7 g per 100 ml, with an erythrocyte volume of 26 percent. An empiric ulcer-treatment program was initiated, but the patient continued to have tarry stools for three days; at no time was there hematemesis. He received a transfusion of 4 units of blood. He subsequently was transferred to the Cleveland Clinic Hospital for further evaluation and treatment.

On December 26, 1968, at the time of admission to the Cleveland Clinic Hospital, the patient was in no acute distress. On physical examination there were no stigmata of chronic hepatic disease and no evidence of jaundice. The liver edge was palpable 3 or 4 cm below the right costal margin; the spleen was not enlarged; there was no evidence of ascites; and there were no abdominal bruits. Other than the enlarged liver, there were no abdominal masses. The results of a proctosigmoidoscopic examination and the remainder of the physical examination were normal.

The initial laboratory studies demonstrated the following values: blood hemoglobin, 10.8 g per 100 ml, with a cell volume of 35 percent; leukocyte count, 4500 per cubic millimeter; serum bilirubin, 0.8 mg per 100 ml; serum glutamic oxaloacetic transaminase (SGOT), 42 units; sulfobromophthalein retention, 9 percent at 45 min; serum alkaline phosphatase, 10 King-Armstrong units; serum albumin, 4.8 g per 100 ml; total protein, 7.7 g per 100 ml; serum cholesterol, 215 mg per 100 ml; blood urea nitrogen, 13 mg per 100 ml; prothrombin time, 14 sec (control, 13 sec). Serum electrolyte values were normal.

Roentgenograms of the upper gastrointestinal tract demonstrated esophageal and gastric varices (*Fig. 1*). This evidence was confirmed by esophagoscopy and gastroscopy, the report of which read: "Very large esophageal varices were present throughout the length of the esophagus. There were large tortuous elevations of the mucosa, the color was slightly blue. The mucous membrane overlying the varices seemed to be intact. Slight inflammatory change was present in the distal 1 cm. of the esophagus . . . gastric varices of a rather large size were identified; one on the lesser curvature of the stomach seemed to be the source of some bleeding at the present time. There was also an area of white mucosa near this which suggested some erosion of the varix." (*Fig. 2*)

A splenoportogram (*Fig. 3*) demonstrated obstruction of the portal veins with bridging collateral vessels and large gastric and esophageal varices; the splenic pulp pressure was 440 mm H₂O.

The portal hypertension, portal vein thrombosis, gastroesophageal varices, and bleeding, were indications for laparotomy, which was performed on January 7, 1969. At that time, an 8-cm rounded hepatic mass was found to arise from the caudal lobe of the liver. Both right and left lobes of the liver were normal. There was portal vein thrombosis (*Fig. 4*). A splenectomy and splenorenal shunt were performed, and the collateral vessels of the splenic

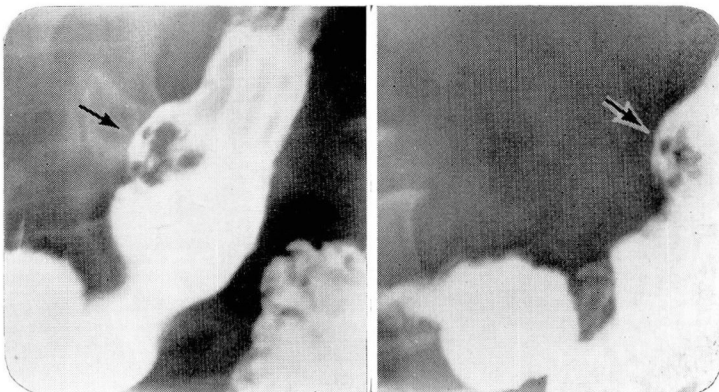


Fig. 1. Roentgenograms of the stomach after ingestion of barium, showing large gastric varices on the lesser curvature.

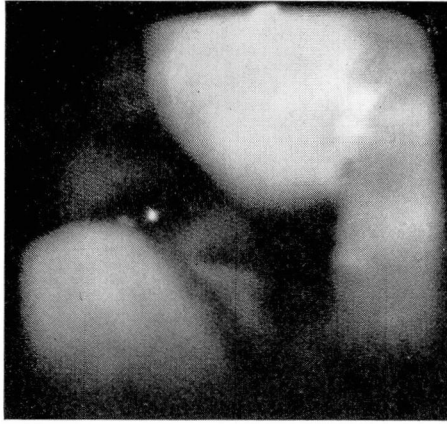


Fig. 2. Endoscopic photograph of two esophageal varices.

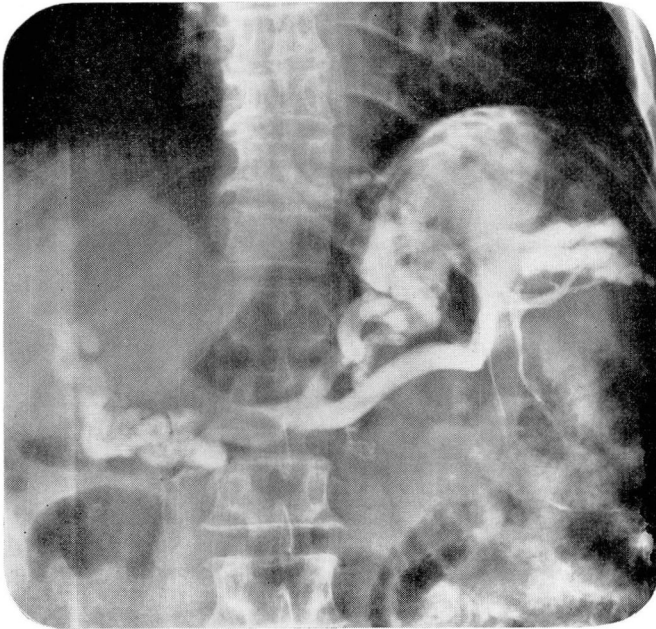


Fig. 3. Splenoportogram demonstrating enormously dilated collateral vessels and characteristic tapering and obstruction of the portal vein, indicative of severe portal hypertension and portal vein thrombosis.

vein were ligated. There was no ascites. Collateral exploration disclosed normal structures, and there was no evidence of polycystic kidneys (*Fig. 5*). The hepatic mass was biopsied, and demonstrated a bland, noninflammatory portal fibrosis with dilatation of the central veins, consistent with congenital hepatic fibrosis in Riedel's lobe (*Fig. 6*).

Postoperatively the patient did well and his blood hemoglobin ranged from 11 to 12 g per 100 ml. Postoperative (on January 9, 1969) determinations were: serum bilirubin, 1.8 mg per 100 ml; SGOT, 123 units; and serum alkaline phosphatase, 6.4 King-Armstrong

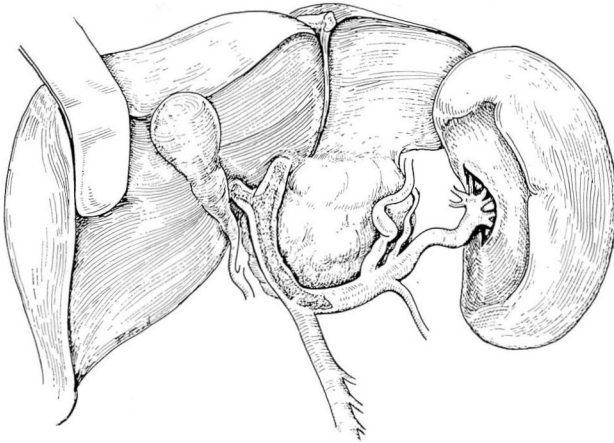


Fig. 4. Operative sketch before splenorenal shunt was constructed, showing portal vein thrombosis, dilated collateral veins, and strikingly fibrotic Riedel's lobe.

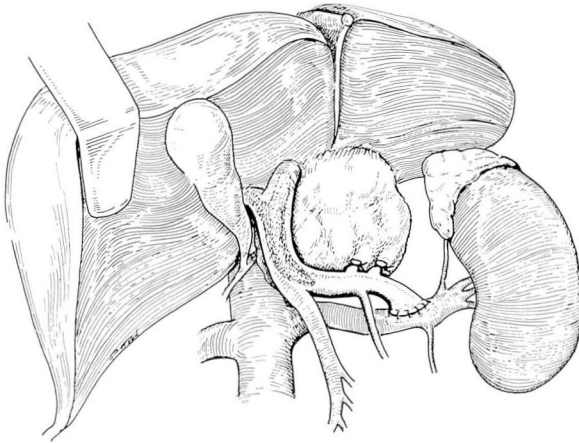


Fig. 5. Operative sketch after completion of splenorenal shunt, showing the shunt and the ligated collateral vessels of the splenic vein.

units. Blood ammonia values also were normal on three separate occasions. Prothrombin time was the same as the control time—13 sec—and serum electrolyte values were again normal. A cephalin-flocculation test was negative. On January 13, 1969, the SGOT value was 62 units.

The patient made a complete recovery and is now asymptomatic. He was discharged from the hospital on January 14, 1969. At the time of follow-up examination on February 7, 1969, he had no symptoms and his blood hemoglobin content was normal.

Discussion

This case illustrates many of the cardinal features of congenital hepatic fibrosis, with some significant exceptions. The clinical and pathologic char-

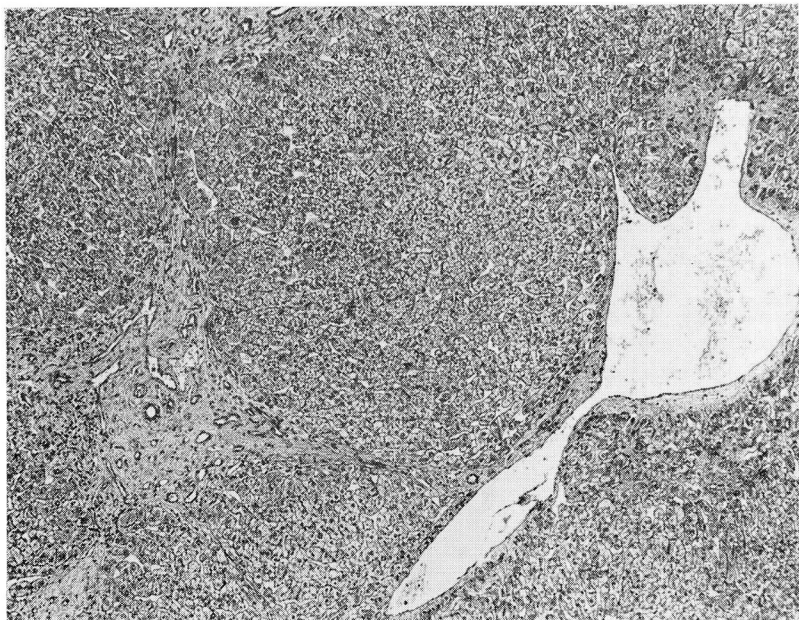


Fig. 6. Photomicrograph of biopsy specimen of Riedel's lobe. Note increased portal fibrosis and dilatation of central vein. Hematoxylin-eosin stain; magnification X60.

acteristics of congenital hepatic fibrosis are: (1) gastrointestinal hemorrhage secondary to portal hypertension as the initial clinical manifestation usually in a patient in the second decade of life; (2) relatively normal liver function tests; (3) absence of stigmata or clinical history suggesting chronic liver disease; and (4) a dense, bland fibrosis in the portal areas throughout the entire liver, in which are enmeshed the bile ducts and vascular channels. The unique features of the case we report are the clinical presentation of gastrointestinal bleeding in a patient at the age of 64 years, and the localization of the hepatic fibrosis exclusively to Riedel's lobe.

Thrombosis of the portal vein has not been reported in association with either congenital hepatic fibrosis¹⁻³ or Riedel's lobe of the liver.¹⁰ In the case we report, it appeared to be a significant factor in the development of portal hypertension and the subsequent gastroesophageal varices. We found no evidence of polycystic disease of the liver or of the kidneys, although it has been reported to be associated frequently with congenital hepatic fibrosis.¹⁻³

Because of the relatively normal liver function and the good prognosis for patients with congenital hepatic fibrosis, surgical procedures to relieve portal hypertension should be performed once there is bleeding from gastroesophageal varices. The long-term prognosis for such patients appears to be excellent, and recurrence of bleeding is rare.

Summary

A case is reported of congenital hepatic fibrosis involving Riedel's lobe only, in which the initial symptoms were massive gastrointestinal bleeding in a patient 64 years old. The histologic characteristics of congenital hepatic fibrosis were present in Riedel's lobe alone; the architecture of the rest of the liver was normal. In addition, portal vein thrombosis was present. The most unusual features of the case were the restriction of the hepatic fibrosis to Riedel's lobe, and the age of the patient at the time of onset of clinical symptoms. It is emphasized that the prognosis should be good for patients with portal hypertension, secondary to congenital hepatic fibrosis, when a surgical procedure to relieve the portal hypertension has been performed.

References

1. Parker, R. G. F.: Fibrosis of the liver as a congenital anomaly. *J. Path. Bact.* **71**: 359-368, 1956.
2. Kerr, D. N. S., and others: Congenital hepatic fibrosis. *Quart. J. Med.* **30**: 91-117, 1961.
3. McCarthy, L. J.; Baggenstoss, A. H., and Logan, G. B.: Congenital hepatic fibrosis. *Gastroenterology* **49**: 27-36, 1965.
4. Haas, L.: Congenital hepatic fibrosis with portal hypertension. *Proc. Roy. Soc. Med.* **53**: 327-328, 1960.
5. Boley, S. J.; Arlen, M., and Mogilner, L. J.: Congenital hepatic fibrosis causing portal hypertension in children. *Surgery* **54**: 356-360, 1963.
6. Hermann, R. E., and Hawk, W. A.: Congenital hepatic fibrosis as a cause of portal hypertension: report of two cases. *Surgery* **62**: 1095-1099, 1967.
7. Melnick, P. J.: Polycystic liver; analysis of 70 cases. *A.M.A. Arch. Path.* **59**: 162-172, 1955.
8. Tisdale, W. A.; Klatskin, G., and Glenn, W. W.: Portal hypertension and bleeding esophageal varices; their occurrence in the absence of both intrahepatic and extrahepatic obstruction of the portal vein. *New Eng. J. Med.* **261**: 209-218, 1959.
9. Hermann, R. E.; Rodríguez, A. E., and McCormack, L. J.: Selection of patients for portal-systemic shunts. *J.A.M.A.* **196**: 1039-1044, 1966.
10. James, P. M., Jr.; Howard, J. M., and Wolferth, C. C., Jr.: Riedel's lobe of the liver. *Amer. J. Surg.* **105**: 812-815, 1963.