

# Treatment of infected sternal wounds

Chalit Cheanvechai, M.D.  
Frank Travisano, M.D.\*  
Donald B. Effler, M.D.

*Department of Thoracic and  
Cardiovascular Surgery*

During the 10-year period between January 1962 and December 1971, 6,014 patients have undergone myocardial revascularization utilizing a median sternotomy incision. Postoperative wound dehiscence, when combined with infection of the sternum, is an uncommon, but serious complication.

The conventional method of treating infected wounds by widely opening and packing the wound cannot be applied to the sternum because the heart or both pleural cavities are exposed, and the sternum must be closed to prevent respiratory difficulty.

Our purpose is to report our experience in treatment of infection and dehiscence of the sternum by continuous irrigation with an antibiotic solution, with primary closure of the sternum, and delayed closure of the skin.

## **Clinical material**

Infection of the median sternotomy incision developed in three patients who had undergone myocardial revascularization. In all three patients a standard median sternotomy incision was made and the sternum was divided by an electric oscillating saw (Sarns). Bleeding from the periosteum and bone marrow was controlled by electrocautery and bone wax. The sternum was approximated by six or seven wire sutures (*Fig.*

\* *Fellow, Department of Thoracic and Cardiovascular Surgery.*

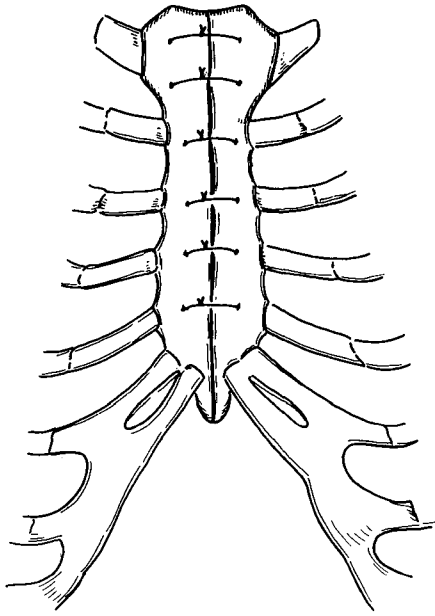


Fig. 1. Routine closure of sternum.

1). The subcutaneous tissue was closed with 2-0 catgut and the skin was closed with silk sutures. Antibiotics were given during the operation and continued for 7 days.

### Case reports

**Case 1.** A 60-year-old man had saphenous vein grafts to the circumflex and anterior descending arteries, and a left internal mammary artery implant on December 12, 1970. Severe bilateral diffuse pulmonary infiltration developed on the 1st postoperative day and a tracheostomy was performed the 2nd postoperative day. The patient was placed on a volume respirator. On the 11th postoperative day dehiscence of the sternum developed. On the 18th postoperative day the sternum was reclosed with wire sutures (Fig. 2). The culture of drainage fluid grew *Proteus mirabilis*.

The sternum did not heal and a second dehiscence developed. On the 30th postoperative day the sternum was closed using multiple wire sutures and continuous

mediastinal irrigation with 0.25% neomycin solution (Fig. 3). Twelve days later the skin was closed. The sternum was stable. The patient was released from the hospital and was last examined on September 8, 1971. The skin was completely closed, and the sternal bone was stable with no evidence of chronic osteomyelitis.

**Case 2.** A 56-year-old man had had total laryngectomy for carcinoma of the larynx in December 1958. He underwent a saphenous vein graft to the circumflex and anterior descending, and a left internal mammary artery implant on April 13, 1971. On the 5th postoperative day dehiscence of the sternum developed. The sternum was reclosed by wire sutures. The patient was not ventilating well and required continuous assisted ventilation. The culture of fluid from the sternum was *Staphylococcus aureus* coagulase positive.

On the 16th postoperative day, a second episode of sternal dehiscence developed and the sternum was reclosed by multiple

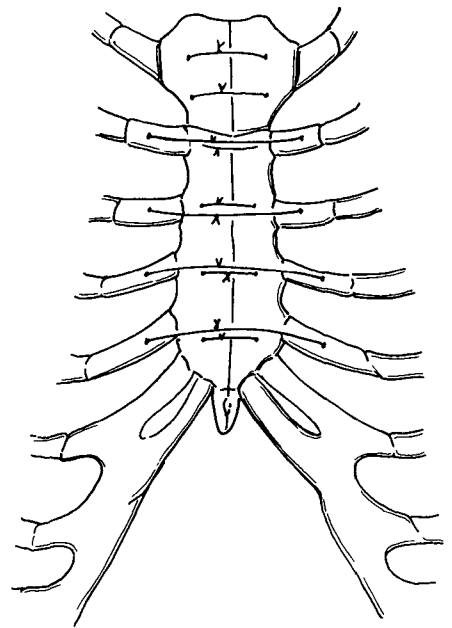


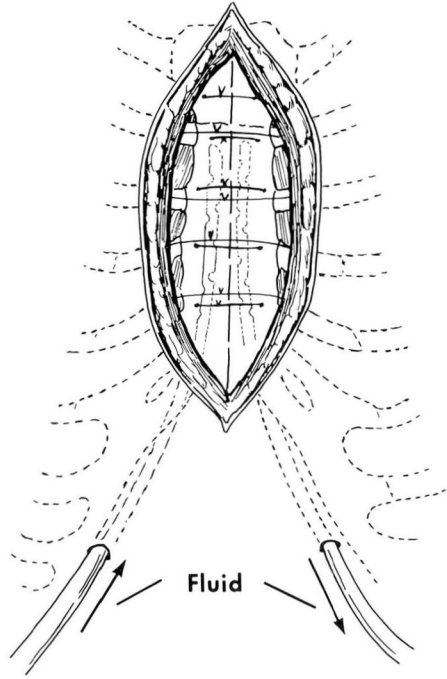
Fig. 2. Primary closure of sternum after dehiscence with extra wire sutures through costal cartilage.

wire sutures and waterseal drainage. The fluid from the sternum continued to culture *Staphylococcus aureus* coagulase positive. One week later the sternum again dehiscenced and the wound was treated by local irrigation with 1% neomycin and was reclosed with multiple wire sutures, and continuous mediastinal irrigation was begun. The patient did well and was discharged from the hospital with the skin left open. He was last examined on August 30, 1971. The skin was completely closed; there was no evidence of osteomyelitis, and the sternum was stable.

**Case 3.** A 50-year-old woman, obese and diabetic, underwent a bilateral internal mammary artery implant on July 9, 1971. On the 10th postoperative day dehiscence of the abdominal portion of the incision developed with no evidence of infection. One week later the discharge from the wound grew *Escherichia coli* and *Staphylococcus* coagulase negative. On the 20th postoperative day dehiscence of the sternum developed. The sternum was reclosed with multiple wire sutures and continuous mediastinal irrigation was instituted. The skin was closed by second intention and the patient was discharged from the hospital on September 13, 1971.

### Method of treatment

As a result of experience with these three patients the following method is recommended for sternal wound infection: (1) The entire sternotomy incision should be reopened as soon as the infection is recognized. (2) The mediastinum, sternum, and subcutaneous tissue should be carefully debrided and irrigated with antibiotic solution. (3) A culture of the discharge from the mediastinum should be taken to determine the organism and antibiotic sensitivities. (4) Two plastic tubes (No. 32) should be inserted under the sternum for irrigation and drainage. If the pleural space is open,



**Fig. 3.** Primary closure of sternum with mediastinal irrigation.

an additional chest tube should be inserted into the pleural cavity. (5) Sternal edges should be approximated by two sets of wire sutures and subcutaneous tissue should be left open and packed with gauze. (6) Continuous antibiotic solution irrigation (0.25% neomycin) is started on the day of surgery and continued for 7 to 14 days. (7) The appropriate systemic antibiotics should be used and continued for 2 to 3 months. (8) Skin closure should be delayed until the wound is free of infection. (Fig. 4-6).

### Discussion

Diagnosis of sternal wound infection is not difficult. Persistent, unexplained fever is the first sign, and drainage through the incision or dehiscence of the sternum is ominous. Treatment by

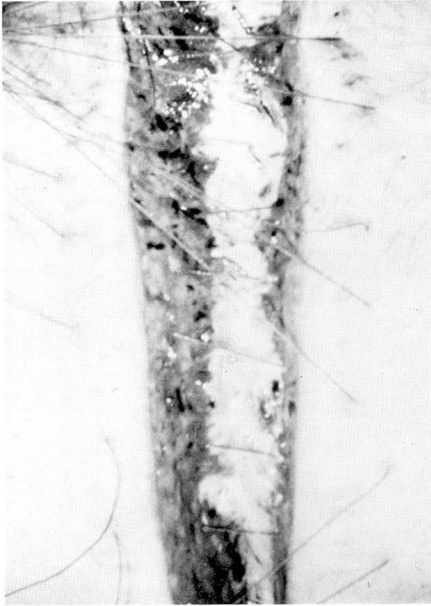

Fig. 4. Wound just prior to skin closure.

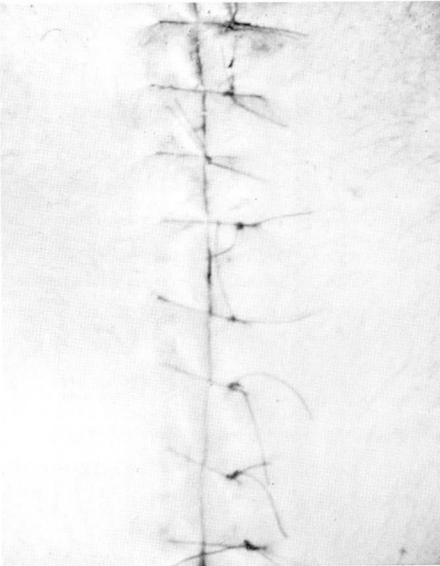


Fig. 5. Delayed skin closure with absence of infection.

primary closure of the sternum and skin usually fails, as demonstrated in Cases 1 and 2. Continuous antibiotic irrigation has been successfully utilized

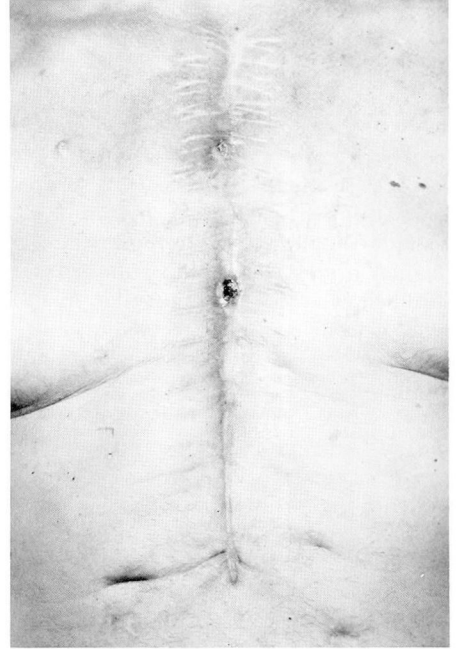


Fig. 6. Appearance of incision 1 year after surgery.

in the treatment of chronic osteomyelitis.<sup>1-4</sup> This technique has been used in the treatment of infections of median sternotomy incisions with successful results.<sup>5, 6</sup> We do not close the skin because the subcutaneous tissue is usually as infected as the sternum, and we believe delayed skin closure is the safer method in these cases. In this method, if the wire sutures become loose they can be tightened before closure of the skin.

Infection and dehiscence of the sternum is a major complication and may lead to fatal infection of the intracardiac prosthesis or graft. It should be intensively treated in order to promote healing of the sternum and prevent further spreading of infection or development of chronic osteomyelitis.

#### References

1. Dombrowski ET, Dunn AW: Treatment of osteomyelitis by debridement and closed

- wound irrigation-suction. *Clin Orthop* **43**: 215-231, 1965.
2. Taylor AR, Maudsley RH: Instillation-suction technique in chronic osteomyelitis. *J Bone Joint Surg* **52B**: 88-92, 1970.
  3. Anderson LD, Horn LG: Irrigation-suction technic in the treatment of acute hematogenous osteomyelitis, chronic osteomyelitis and acute and chronic joint infection. *South Med J* **63**: 745-754, 1970.
  4. Kelly PJ, Martin WJ, Coventry MB: Chronic osteomyelitis. II. Treatment with closed irrigation and suction. *JAMA* **213**: 1843-1848, 1970.
  5. Shumacker HB Jr, Mandelbaum I: Continuous antibiotic irrigation in the treatment of infection. *Arch Surg* **86**: 384-387, 1963.
  6. Bryant LR, Spencer FC, Trinkle JK: Treatment of median sternotomy infection by mediastinal irrigation with an antibiotic solution. *Ann Surg* **169**: 914-920, 1969.