

Carcinoid tumors

Analysis of 61 cases, including 11 cases of carcinoid syndrome

David G. Van Sickle, M.D.*

Department of Gastroenterology

Carcinoid tumors have long been anatomical and biochemical curiosities to investigators. There is disagreement as to the character of the tumors, and continued speculation on the exact mechanism by which symptoms are produced. However, it is known now that carcinoid tumors are potentially malignant—capable of local invasion and distant spread.

Grossly, carcinoid tumors appear as small, round to plaque-like, submucosal elevations which are deceptively mobile. The overlying mucosa is usually intact. When sectioned the tissue is yellow. Microscopically, there is no variation in the size and shape of individual cells, with polygonal to cuboidal cells looking much alike. Rarely carcinoid tumors may ulcerate, bleed, or obstruct. Mitosis and anaplasia are rare. For this reason, the usual criteria for judging the malignant potential of a carcinoid tumor are different from those in carcinoma. Gross and microscopic invasion determine the malignancy of a carcinoid tumor. MacDonald¹ has stated that a carcinoid tumor that has infiltrated the muscularis of the bowel wall is already in the first stage of malignancy. He has shown that carcinoids metastasize via the blood vessels to lymph nodes, liver, and other distant organs. Although he considered appendiceal carcinoids nonmetastasizing and, therefore, different from carcinoid tumors in other sites, there is evidence to the contrary.²

In 1906 Ciaccio³ suggested that carcinoid tu-

* Present address: 1216 S. W. Yamhill Street, Portland, Oregon 97205.

mors had a biochemical activity, i.e., production of epinephrine; but it was not until 1948 that Rapport et al⁴ crystallized a vasoconstrictor substance from serum extracts and called it serotonin. The following year, the same group⁵ identified the structure of serotonin as 5-hydroxytryptamine. In studies of the gastrointestinal mucosa of mammals and invertebrates, conducted over a period of several years, Erspamer and Asero⁶ identified extracts that stimulated smooth muscle and seemed related to argentaffine cells; in 1952 they observed that the substance they called "enteramine" was identical to serotonin.

The relation of serotonin to carcinoid tumors was not appreciated until 1953 when Lembeck⁷ reported the extraction of serotonin from a carcinoid tumor of the gastrointestinal tract. The same year, Isler and Heding⁸ described a carcinoid syndrome. Their three patients with carcinoid of the ileum, which had metastasized to the liver, also had chronic endocarditis of the right side of the heart, pulmonic stenosis, and/or tricuspid valvular insufficiency. In 1954, Thorson et al⁹ called attention to the release of serotonin from the carcinoid tumor in a patient with carcinoid syndrome.

The characteristics of the carcinoid syndrome are intermittent violaceous flush of the face, neck, and chest, watery diarrhea, abdominal distension and borborygmi, and symptoms of right-sided heart failure due to involvement of the tricuspid and pulmonary valves.

Approximately 95% of total body serotonin is in the gastrointestinal mucosa.¹⁰ Lesser amounts are in the platelets, brain, and spleen. The carcinoid syndrome is most often asso-

ciated with hepatic metastases. Serotonin is released directly into the general circulation; this avoids inactivation of the serotonin by the large amounts of monamine oxidase in the liver.

Fibrosis of the pulmonic and tricuspid valves usually occurs late in the disease. Although it is logical to ascribe fibrosis to the chemical irritation caused by the high levels of serotonin in the blood, administration of 5-hydroxytryptamine and 5-hydroxyindoleacetic acid to animals has not resulted in endocardial fibrosis.¹⁰ More often lesions are on the right side of the heart than on the left side. This is because serotonin in blood leaving the right side of the heart is inactivated by monamine oxidase in the lungs. The carcinoid flush is attributable to vasodilatation and the diarrhea is attributable to hypermotility of the intestine. Hypermotility may be pronounced to the extent that malabsorption exists. Symptoms of the carcinoid syndrome can be initiated by emotional disturbances, physical exertion, manipulation of the tumor, eating, drinking alcohol, or injection of histamine.

A diagram of the synthesis and metabolism of serotonin is shown in *Figure 1*. *Figure 2* shows the activation of tryptophane metabolism by the demands of a carcinoid tumor. Pellagra-like lesions may be caused by the induced deficiency of nicotinic acid.

Page et al,¹¹ in 1955, reported finding 5-hydroxyindoleacetic acid in the urine, and provided a convenient method for the diagnosis of the carcinoid syndrome. A normal value for urinary excretion of the acid is less than 16 mg/24 hours. The values are increased in patients with nontropical sprue,¹² and also after eating bananas

which contain significant amounts of serotonin.¹³ Transient elevations of excreted acid may occur after administration of reserpine or ingestion of mephensin carbamate,¹⁴ or phenothiazine.¹⁵

The role of serotonin as the sole mediator of the carcinoid flush was questioned in 1964 when Oates et al¹⁶ reported that the blood serotonin level was normal in one of their patients despite 4 days of continuous severe flushing. They duplicated the carcinoid flush by rapid infusion of synthetic bradykinin. Two years later, Dollinger and Gardner¹⁷ suggested a theoretical mechanism for the cause of the carcinoid flush. Figure 3 represents a simplified scheme of action, modified from their hypothesis.

Cleveland Clinic series

This report presents an analysis of the cases of carcinoid tumor diagnosed at the Cleveland Clinic and a review of the pertinent published studies.

From 1946 to 1970, 61 cases of carcinoid tumor were recorded at the Cleveland Clinic. Five of the nine cases reported by House and Hermann¹⁸ in 1965 are included; also a case of small bowel carcinoid has been reported by Barber and Michener.¹⁹

Of the 61 patients, 37 were males and 24 were females (1.5:1.0). Their ages at the time of diagnosis ranged from 11 to 76 years.

Although the components of the carcinoid syndrome are well known, criteria for its diagnosis are not as certain. For purposes of this study, a patient was judged to have carcinoid syndrome when one of the components was present and, in addition the patient had a positive urinary 5-hydroxyindoleacetic acid (5-HIAA) deter-

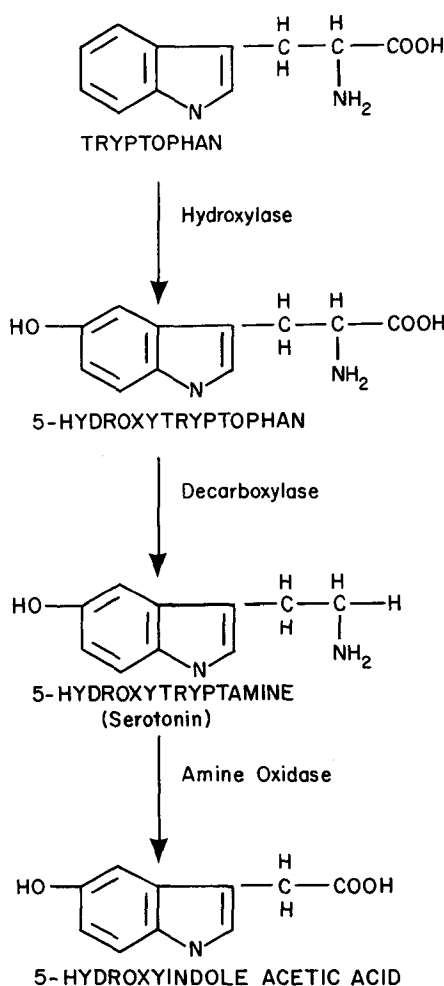


Fig. 1. Diagram showing synthesis and metabolism of serotonin from Resnick and Gray.¹⁰

mination as well as a positive tissue diagnosis. On this basis, there were 11 patients who had carcinoid syndrome.

All patients in the series, including those with carcinoid syndrome, had a history of diarrhea, but none was diagnosed as having malabsorption. Three had right-sided valvular murmurs and symptoms of right-sided heart failure. Flushing was present in 9 of the 11 patients with carcinoid syndrome. Twenty-four-hour urine determina-

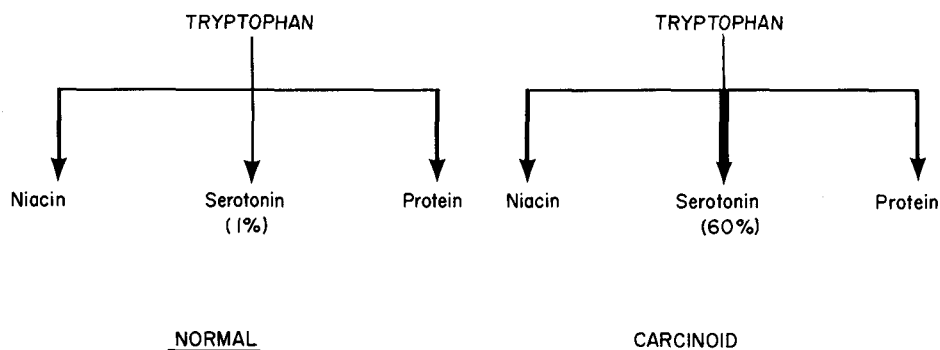


Fig. 2. Diagram showing differential metabolism of tryptophan.

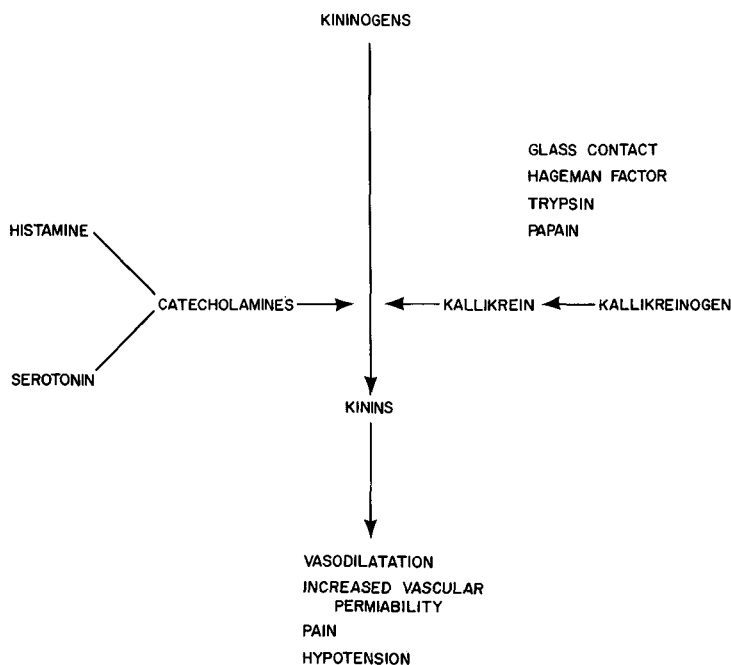


Fig. 3. Diagram modified from Dollinger and Gardner.¹⁷

tions of 5-HIAA were obtained in 10 patients, and values were consistently more than 16 mg output in 24 hours. One patient had only a spot urine determination for 5-HIAA. He was a 56-year-old man in whom the carcinoid tumor, in an unspecified portion of the intestine, had been detected at operation at another institution. On examination at the Cleveland Clinic,

he stated that for 5 years he had had flushing of the face and watery diarrhea. He also had the murmurs of insufficiency of the tricuspid valve and pulmonic stenosis.

Definite diagnosis in all cases was made from microscopic evaluation of material obtained at biopsy, surgical excision, or autopsy (5 cases). In 16 cases initial pathologic diagnosis had

been made elsewhere, but additional diagnostic procedures were done at the Cleveland Clinic.

In regard to the site of the primary tumor, three lesions could be localized to the small bowel, but more specific location was not possible. Two lesions could be localized only as far as "the intestine." Of the 11 patients with carcinoid syndrome, 10 had primary tumors in the intestinal tract: 8 in the ileum, and 2 in unspecified sites of the intestine. The primary tumor in the 11th patient was in the bronchus.

Table 1 shows the primary sites of the carcinoids. The 21 patients with rectal carcinoids (34.4%) are the largest single group in the series. The average age of these 21 patients was 49 years.

Chemotherapy was given to three patients postoperatively. One died 3 months after receiving cyclophosphamide (Cytosan). Autopsy disclosed a carcinoid in an unspecified part of the small bowel. The second patient, who had carcinoid syndrome and to whom melphalan (Alkeran) was adminis-

tered, died 14 months postoperatively. She was a 64-year-old woman with carcinoid of the ileum which had metastasized to the liver and celiac plexus. The third patient, who has been treated with cyclophosphamide for 2 years, is alive. She is a 62-year-old woman who for 12 years has had liver metastasis from a carcinoid in an unspecified site in the intestine and also has symptoms of right-sided heart failure. For 4 years she has had flushing and for 12 years she has had a maximum of eight watery bowel movements per day.

Carcinoids of the ileum had the highest incidence of metastasis. The liver was the most common metastatic site. All 11 patients with carcinoid syndrome had liver metastases. Liver metastases were also noted in two patients who did not have the carcinoid syndrome. One of the two was known to have a primary retroperitoneal tumor. The primary tumor site of the other patient was not known.

Seven patients had coexisting lesions, of which five were malignant

Table 1.—Site of carcinoid tumors in reported studies

Primary site	Cleveland Clinic		Wilson et al ²¹		Postlethwait ²²	
	Number	Percent	Number	Percent	Number	Percent
Stomach	0	0	1	1.0	83	2.8
Duodenum	4	6.5	0	0	43	1.5
Jejunum	0	0	6	6.7	49	1.7
Ileum	15	24.5	18	23.2	813	27.9
Meckel's diverticulum	0	0	0	0	33	1.1
Appendix	12	19.6	36	46.0	1,340	45.9
Colon	0	0	4	5.2	61	2.1
Rectum	21	34.4	11	13.9	486	16.7
Gallbladder	0	0	0	0	8	0.3
Intestine (not localized)	5	8.1	0	0	0	0
Other	4*	6.4	2	3.0	0	0
Total	61	99.5	78	99.0	2,916	100.0

* One each, retroperitoneum, bronchus, ovary, unknown primary site.

and two benign. One of these patients was operated on for carcinoma of the cecum when the metastatic carcinoid of the ileum was noted. Carcinoid of the ileum was an incidental finding at autopsy on a 57-year-old man who died of carcinoma of the right upper lobe of the lungs. Neither of these patients had had symptoms of the carcinoid syndrome. Carcinoma of the prostate in one patient, and villous adenoma of the splenic flexure of the colon in another were incidental findings in two patients who demonstrated the carcinoid syndrome. Appendiceal carcinoid was an incidental finding in a patient operated on for grade II adenocarcinoma of the colon and in another patient operated on for villous adenoma of the cecum. Hypernephroma was the primary tumor in a 58-year-old man in whom a rectal carcinoid was discovered on routine rectal examination.

Sixteen patients could not be traced at the time of follow-up in June 1970, but follow-ups had been made at intervals of 3 to 7 years after diagnosis.

Five of the 13 patients with carcinoids of the ileum who had been operated on were accessible for follow-up. All five are known to have residual tumor. Three patients died at 4 days, 7 days, and 14 days, respectively, after operation. The last is the 64-year-old woman whose carcinoid had metastasized to the liver and celiac plexus and who had been given melphalan.

The longest survival is 13 years. The patient is a physician who, at operation in 1956 when he was 53 years old, had an ulcerative carcinoid in the distal ileum as well as metastasis to the right lobe of the liver and mesenteric nodes. A 5-HIAA screening test per-

formed in 1968 was positive. Appendectomy had been performed on all 12 patients with appendiceal carcinoids. There are no known deaths among them, although recent follow-up was available in only five. Too few patients with rectal carcinoids were available for continued follow-up. The tumor had been completely excised in 8 of the 10 patients lost to follow-up.

Discussion

The most comprehensive study of longevity of patients with carcinoid tumors was published by Moertel et al²⁰ in 1961. They collected 209 cases of carcinoid of the small bowel detected from 1930 to 1957. The 5-year survival rate in patients with incompletely removable carcinoid tumors in their series was 27%. In the present series of 61 patients, the 5-year survival rate of patients with comparable tumors of the ileum and small intestine combined is 45%.

Wilson et al,²¹ in 1963, reported 78 cases of carcinoids collected over a 20-year period. In their study, appendiceal carcinoids occurred in 46% of the patients. In the present study, rectal carcinoids were predominant. A study reported by Postlethwait,²² in 1966, consists of 2,916 carcinoid tumors of the intestine, collected from a number of reports, including that of Wilson et al.²¹ The incidence of rectal and ileal tumors in the Cleveland Clinic study exceeds that in Postlethwait's study, whereas the experience with appendiceal carcinoids in the Cleveland Clinic is smaller (*Table 1*).

Most of the patients seen in the Cleveland Clinic are referred from elsewhere. Therefore, relatively few appendectomies are performed in the Cleveland Clinic and the experience

with appendiceal carcinoids is limited. Interestingly, of the 12 patients with appendiceal carcinoids in the present series, only one underwent operation in the Cleveland Clinic. Two patients operated on elsewhere for acute appendicitis were subsequently referred to the Cleveland Clinic. The appendectomies of the other patients were incidental procedures.

Similarly, the greater experience with rectal carcinoids in the Cleveland Clinic may reflect the fact that it is a referral institution. It may also indicate a high incidence of routine rectal and proctoscopic examinations that disclosed rectal carcinoids in 10 patients. The characteristic slow growth of the carcinoid makes success of treatment difficult to evaluate. One patient in this series has been treated with cyclophosphamide for 2 years with apparently good success. Serotonin antagonists—such as methysergide maleate (Sansert), phenyl acetic acid, and methyldopa (Aldomet)—have provided little symptomatic relief. Cyproheptadine hydrochloride (Periactin), also a serotonin antagonist, and chlorpromazine (Thorazine) seem to offer more symptomatic relief.¹⁵ Recently, para-chlorophenylalanine has been employed with success as an inhibitor of 5-HIAA in the carcinoid syndrome.^{23, 24}

The number of cases in the present study is not sufficient to compare adequately with larger published studies. Statistics are based on experience only at the Cleveland Clinic. An inventory of the medical records disclosed only one tumor diagnosed prior to 1951; a carcinoid of the duodenum found at operation in 1946.

Some studies²⁰ report a lower average age for patients with appendiceal

carcinoids than for those with carcinoids of the small bowel. This was true in the Cleveland Clinic series. The ages of patients with ileal, duodenal, or small bowel carcinoids ranged from 11 to 77 years.

Conclusions

1. The postoperative survival rate for patients with nonresectable small bowel carcinoids in this small series is higher than that reported in larger studies.

2. The incidence of appendiceal versus small bowel carcinoids is lower than in published reports. The difference probably reflects the fact that more cases of the latter are referred to the Cleveland Clinic.

3. A similar conclusion can be made for the increased incidence of rectal carcinoids at the Cleveland Clinic.

Summary

Sixty-one cases of carcinoid tumor, including 11 cases of carcinoid syndrome from the records of the Cleveland Clinic, are discussed in terms of site of occurrence, metastasis, morbidity, and therapy. Compared with other studies the Cleveland Clinic series shows a higher postoperative survival rate for patients with nonresectable small bowel carcinoids. The decreased incidence of appendiceal carcinoids and the increased incidence of rectal carcinoids in the Cleveland Clinic series of patients probably reflect the fact that most patients in this study were referred from elsewhere. A review of the literature on carcinoid tumors and the carcinoid syndrome is included.

Acknowledgment

The advice and encouragement of Benjamin H. Sullivan, Jr., M.D., De-

partment of Gastroenterology, The Cleveland Clinic Foundation, is gratefully acknowledged.

References

- MacDonald RA: A study of 356 carcinoids of the gastrointestinal tract. Report of four new cases of the carcinoid syndrome. *Am J Med* 21: 867-878, 1956.
- Turner M, Gallagher HS: Occult appendiceal carcinoid. Report of a case with fatal metastases. *Arch Pathol* 88: 188-190, 1969.
- Ciaccio C: Sur une nouvelle espèce cellulaire dans les glandes de Lieberkühn. *Compt rend Soc de biol* 60: 76, 1906.
- Rapport MM, Green AA, Page IH: Crystalline serotonin. *Science* 108: 329-330, 1948.
- Rapport MM: Serum vasoconstrictor (serotonin). Presence of creatinine in the complex. A proposed structure of the vasoconstrictor principle. *J Biol Chem* 180: 961-969, 1949.
- Erspamer V, Asero B: Identification of enteramine, the specific hormone of the enterochromaffin cell system, as 5-hydroxytryptamine. *Nature* 169: 800-801, 1952.
- Lembeck F: 5-hydroxytryptamine in a carcinoid tumour. *Nature* 172: 910-911, 1953.
- Isler P, Hedinger C: Metastasierendes Dünndarmcarcinoid mit schweren, vorwiegend das rechte Herz betreffenden Klappenfehlern und Pulmonalstenose—ein eigenartiger Symptomenkomplex? *Schweiz Med Wochenschr* 83: 4-7, 1953.
- Thorson A, Björck G, Björkman G, et al: Malignant carcinoid of the small intestine with metastases to the liver, valvular disease of the right side of the heart (pulmonary stenosis and tricuspid regurgitation without septal defects), peripheral vasomotor symptoms, bronchoconstriction, and an unusual type of cyanosis. A clinical and pathologic syndrome. *Am Heart J* 47: 795-817, 1954.
- Resnick RH, Gray SJ: Serotonin metabolism and the carcinoid syndrome: a review. *Med Clin North Am* 44: 1323-1339, 1960.
- Page IH, Corcoran AC, Udenfriend S, et al: Argentaffinoma as endocrine tumour. *Lancet* 1: 198-199, 1955.
- Kowlessar OD, Williams RC, Law DH, et al: Urinary excretion of 5-hydroxyindoleacetic acid in diarrheal states, with special reference to nontropical sprue. *N Engl J Med* 259: 340-341, 1958.
- Anderson JA Jr, Ziegler MR, Doeden D: Banana feeding and urinary excretion of 5-hydroxyindoleacetic acid. *Science* 127: 236-238, 1958.
- Honet JC, Casey TV, Runyan JW Jr: False-positive urinary test for 5 hydroxyindoleacetic acid due to methocarbamol and mephensin carbamate. *N Engl J Med* 261: 188-190, 1959.
- Ross G, Weinstein IB, Kabakow B: Influence of phenothiazine and some of its derivatives on the determination of 5-hydroxyindoleacetic acid in urine. *Clin Chem* 4: 66-76, 1958.
- Oates JA, Melmon K, Sjoerdsma A, et al: Release of a kinin peptide in the carcinoid syndrome. *Lancet* 1: 514-517, 1964.
- Dollinger MR, Gardner B: Newer aspects of the carcinoid spectrum. *Surg Gynecol Obstet* 122: 1335-1347, 1966.
- House HC, Hermann RE: Functioning malignant carcinoid: a review of nine cases. *Cleve Clin Q* 32: 217-222, 1965.
- Barber DH, Michener WM: Malignant argentaffinoma. Report of a case of an eleven-year-old boy. *Cleve Clin Q* 32: 143-147, 1965.
- Moertel CG, Sauer WG, Dockerty MB, et al: Life history of the carcinoid tumor of the small intestine. *Cancer* 14: 901-912, 1961.
- Wilson H, Storer EH, Star FJ: Carcinoid tumors. A study of seventy-eight cases. *Am J Surg* 105: 35-39, 1963.
- Postlethwait RW: Gastrointestinal carcinoid tumors. A review. *Postgrad Med* 40: 445-454, 1966.
- Satterlee WG, Serpick A, Bianchine JR: The carcinoid syndrome: chronic treatment with para-chlorophenylalanine. *Ann Intern Med* 72: 919-921, 1970.
- Sjoerdsma A, Lovenberg W, Engelman K, et al: Serotonin now: clinical implications of inhibiting its synthesis with para-chlorophenylalanine. *Ann Intern Med* 73: 607-629, 1970.