

# Granuloma annulare and vitamin D resistant rickets

Bernard Robinowitz, M.D.\*

Henry H. Roenigk, Jr., M.D.

*Department of Dermatology*

O. Peter Schumacher, M.D.,  
Ph. D.

*Department of Endocrinology*

The etiology of granuloma annulare is not known. An association between granuloma annulare and diabetes mellitus has often been suggested. Rhodes et al,<sup>1</sup> using a prednisone stress test detected abnormal glucose tolerance in 3 of 30 patients with granuloma annulare. Wells and Smith<sup>2</sup> reported that of 115 patients with granuloma annulare only 3% were diabetic. We report the first case in the literature of granuloma annulare in a patient with vitamin D resistant rickets.

## Case report

A 43-year-old white woman was seen at the Cleveland Clinic in December 1971. She had a 1-year history of low back and anterior trunk pain, and she was found to have hypophosphatemia and glycosuria.

Laboratory studies disclosed the following values: serum phosphorus 1.3 mg/100 ml (normal 2.5-4.5); serum calcium 9.3 mg/100 ml (normal 8.5-10.5); serum alkaline phosphatase 20 King-Armstrong units/100 ml (normal 4-17). Results of a 5-hour glucose tolerance test were normal with glycosuria at 1, 2, and 3 hours. A 24-hour urine specimen had a normal calcium, phosphorus, and amino acid chromatogram. The creatinine clearance was 110 ml/min. The antinuclear factor (ANF), latex fixation test, VDRL test for syphilis, LE test, serum protein electrophoresis, chest and spine roentgenograms and determinations of urine lead, urine 17-ketosteroids, and urine 17-hydroxycorticoids were normal.

\* Fellow, Department of Dermatology.

The diagnosis of vitamin D resistant rickets was made and the patient was discharged January 1972 on a regimen of 50,000 units of vitamin D and 2 g phosphoda orally daily.

Two months after hospital discharge (March 1972) the patient's back pain was slightly improved. The serum alkaline phosphatase value was still elevated at 19 King-Armstrong units and serum calcium and phosphorus values were normal. The dosage of vitamin D was increased to

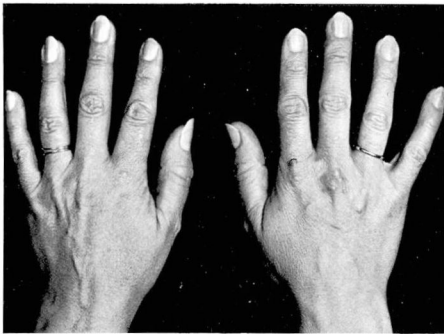


Fig. 1. Hands showing the nodular lesions of granuloma annulare over the knuckle.

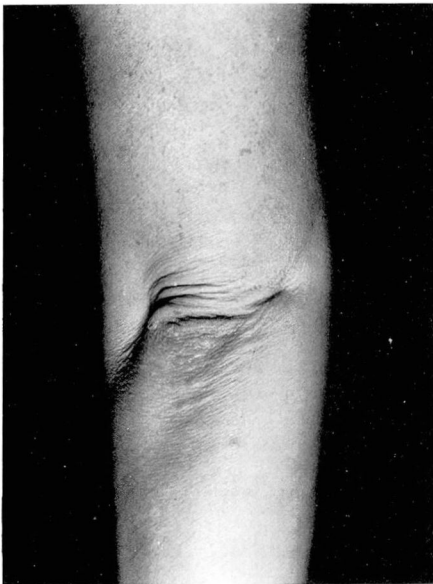

Fig. 2. Nodular lesions of granuloma annulare over the elbow.

100,000 units per day. By May 1972 alkaline phosphatase was 15 King-Armstrong units and serum calcium and phosphorus values remained normal.

In June 1972 the patient noted the onset of painless red macules which were followed by pink nodules on both forearms, both elbows, and the dorsa of both hands. When she was seen at the Cleveland Clinic in July 1972 the lesions appeared as pink annular nodules with slightly depressed centers grouped in circinate fashion (Figs. 1 and 2).

The skin biopsy (Fig. 3) at that time revealed flattening of epidermal papilla, and in the dermis, diffuse necrobiosis of collagen with a mild histiocytic reaction. Oil red O and Van Kossa stains were negative for fat and calcium. The clinical and histologic diagnosis was granuloma annulare. No therapy was prescribed.

### Discussion

This is the first case report of granuloma annulare in a patient with vitamin D resistant rickets. This patient was being treated with vitamin D at the time granuloma annulare developed.

Patients with vitamin D resistant rickets have a defect in the intestinal and renal transport of phosphate.<sup>3</sup> Also, these patients have abnormal vitamin D metabolism<sup>4</sup> and decreased absorption of calcium from the gastrointestinal tract. At this time we cannot relate these biochemical defects to granuloma formation.

Biochemically, vitamin D has been found to stimulate the transcription of messenger RNA which directs synthesis of protein components of a transport system for calcium in the intestine,<sup>5</sup> kidney,<sup>6</sup> and bone.<sup>7</sup> The effect of vitamin D on protein synthesis and calcium metabolism in the skin is not well defined. We believe that further investigation in this area is indicated.

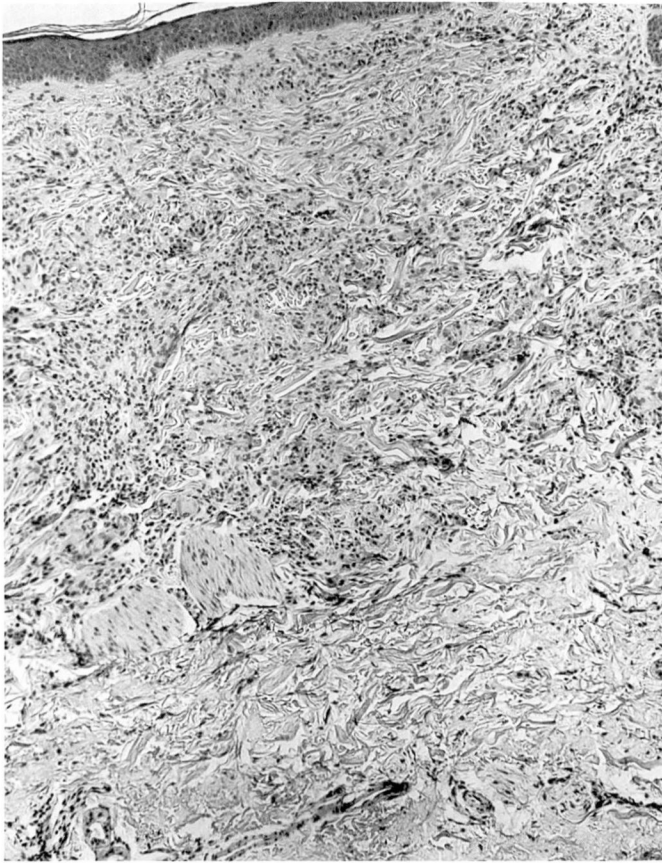


Fig. 3. Granuloma annulare showing diffuse necrobiosis in the lower dermis and a palisading histiocytic inflammatory reaction (hematoxylin and eosin, original magnification  $\times 64$ ).

## References

1. Rhodes EL, Hill DM, Ames AC, et al: Granuloma annulare: prednisone glycosuria tests in a non-diabetic group. *Br J Dermatol* **78**: 532-535, 1966.
2. Wells RS, Smith MA: The natural history of granuloma annulare. *Br J Dermatol* **75**: 199-205, 1963.
3. Short EM, Binder HJ, Rosenberg LE, et al: Familial hypophosphatemic rickets: defective transport of inorganic phosphate by intestinal mucosa. *Science* **179**: 700-702, 1973.
4. Alvioli LV, Williams TF, Lund J, et al: Metabolism of vitamin  $D_3$ - $^3H$  in vitamin D-resistant rickets and familial hypophosphatemia. *J Clin Invest* **46**: 1907-1915, 1967.
5. Wasserman RH, Corradino RA, Taylor AN: Vitamin D-dependent calcium-binding protein; purification and some properties. *J Biol Chem* **243**: 3978-3986, 1968.
6. Taylor AN, Wasserman RH: Vitamin D-induced calcium-binding protein: comparative aspects in kidney and intestine. *Am J Physiol* **223**: 110-113, 1972.
7. Potts FT Jr, Deftos LS: Parathyroid hormone, thyrocalcitonin, vitamin D bone and bone mineral metabolism, p 969, in *Diseases of Metabolism*, 6th edition, Edited by GG Duncan, PK Bondy, LE Rosenberg, Philadelphia, WB Saunders Co., 1969.