

# Endoscopic retrograde cholangiopancreatography (ERCP)

Michael V. Sivak, Jr., M.D.\*

B. H. Sullivan, Jr., M.D.

*Department of Gastroenterology*

Doubilet and Mulholland<sup>1</sup> were the first to demonstrate the use of operative pancreatography in 1951. This was followed by other reports,<sup>2-4</sup> and not all of them recommended the procedure as safe or useful.<sup>5</sup> In 1965 Rabinov and Simon<sup>6</sup> succeeded in nonendoscopic, nonoperative cannulation of the ampulla of Vater under fluoroscopic guidance. This method did not receive much further attention because of the report of McCune et al<sup>7</sup> in 1968. They have the distinction of having performed the first endoscopic ampullary cannulation and pancreatography. Large series were subsequently reported from Japan,<sup>8, 9</sup> most notably by Oi.<sup>10, 11</sup>

Roentgenographically, the normal and abnormal features of the biliary system are relatively familiar. However, criteria for the differential diagnosis of pancreatic disease by roentgenography are now emerging as a result of endoscopic retrograde pancreatography.<sup>12-15</sup> The severity of histologic changes in chronic pancreatitis has been shown to correlate well with the extent of changes demonstrated in the pancreatic ductal system.<sup>16, 17</sup> Other studies have highlighted the singular value of retrograde cholangiography when jaundice prevents visualization of the biliary ducts via the intravenous method.<sup>18, 19</sup> The complication rate for the endoscopic method will prove to be less than the 5% quoted for

\* Fellow, Department of Gastroenterology.

transhepatic cholangiography,<sup>20, 21</sup> and the success rate of diagnosis will undoubtedly prove to be greater than the 74% given for the transhepatic method.<sup>21</sup> While some investigators<sup>22, 23</sup> have urged caution in the further development of these procedures because of time requirements and expense, there can be little doubt that endoscopic retrograde cholangiopancreatography (ERCP) will become a standard diagnostic procedure. The purpose of this paper is to relate our experience with ERCP with reference to technique, indications and contraindications, results and complications, and also to illustrate its unique value in clinical medicine.

### Technique

After a 6-hour fast the patient is positioned on his left side on a standard x-ray table equipped with image intensification. Proper sedation is imperative so that he is somnolent and cooperative, but responsive enough to assist with changes in position. Diazepam (Valium) is given intravenously, slowly in increments of 2.5 mg. Between 7.5 and 30 mg are required. Viscous lidocaine (Xylocaine) is administered orally for pharyngeal anesthesia, and atropine, 0.6 mg, is given intramuscularly 15 minutes prior to beginning the procedure to induce a gastrointestinal ileus. Glucagon, 1 mg intravenously, is given to obtain complete duodenal ileus just prior to actual cannulation. The Olympus JFB model side-viewing duodenoscope, with a 10-mm diameter and working length of 1,370 mm, is employed. A 97-cm long, 2-mm diameter catheter is threaded through the biopsy channel of the instrument for cannulation of the ampulla.

The duodenoscope is inserted through the oropharynx and esophagus and advanced into the duodenum. When the superior flexure of the duodenum is reached, the patient is turned to a prone position, thereby producing an ideal long view of the descending duodenum, and a search for the papilla of Vater is begun. It is usually found on the posteromedial wall of the mid-descending duodenum, although variations in location are common. It may be located in the first or third part of the duodenum. Often a slight submucosal elevation proximal to the papilla is observed. It represents the lowermost portion of the common bile duct lying parallel with the duodenum. An especially prominent submucosal elevation may indicate dilatation or obstruction of the bile duct. A longitudinal fold of mucosa is often noted running downward from the papilla perpendicular to the normal circular duodenal folds. On two occasions the papilla was found to be associated with a diverticulum in the medial wall of the duodenum, and because of this cannulation was unsuccessful. The papilla exhibits various shapes ranging from nearly flat to tall and erect, but these have no clinical significance.<sup>24, 25</sup>

Retrograde studies were accomplished in three of four patients with Billroth II operations (*Fig. 1*). The technique is quite different, and involves passing the instrument retrograde through the efferent limb of the gastroenteric anastomosis. In two of these cases a forward-viewing gastroscope (Olympus GIF-D2) was used for this purpose, and cannulation was successful in both cases.

After locating the papilla, the instrument is positioned for an enface

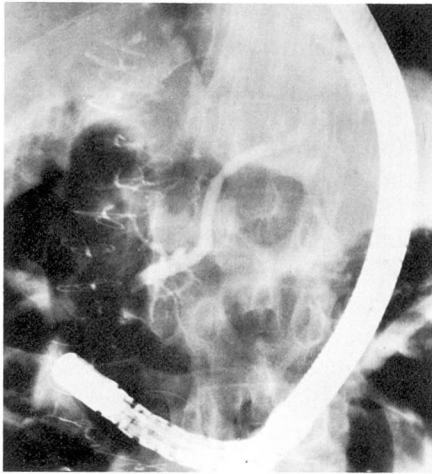


Fig. 1. Obstructed common bile duct, Billroth II operation. Carcinoma of tail of pancreas at operation.

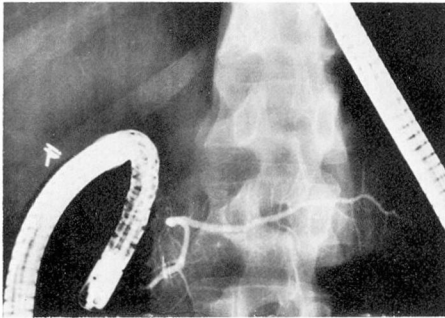


Fig. 2. Normal retrograde pancreatogram.

view of its apex. To accomplish this may require considerable maneuvering and sometimes repositioning of the patient. The location of the papillary opening is usually indicated by subtle color changes in the form of a lacy bluish or reddish reticular pattern at the apex. It is unusual to note an actual orifice, although bile can sometimes be seen flowing from the papilla. The catheter is inserted the shortest distance necessary to maintain it within the papilla. By doing so, one takes advantage of the usually present common channel which is formed by

the junction of the bile and pancreatic ducts. This occurs in about 80% of cases.<sup>24</sup> Injection of contrast medium into the common channel will simultaneously visualize the pancreatic and biliary systems.

A retrograde injection of 60% diatrizoate meglumine (Renografin-60) is made through the catheter. Gentle hand injection is used with constant fluoroscopic monitoring. From 2 to 5 cc of contrast medium will adequately visualize the pancreatic duct (Fig. 2), while the biliary system will accommodate 30 to 40 cc if the gallbladder is present. Some authors<sup>18, 26</sup> recommend the use of a more dilute solution when an intraductal abnormality is suspected, especially in the case of common duct stones,<sup>19</sup> because concentrated agents can obscure small defects. In the case of the biliary system, we have found this not to be necessary. The contrast remains in the bile ducts for periods of up to 30 minutes, during which time it is gradually diluted with biliary fluid. Serial observations will disclose small defects. On occasion we have observed a stone to shift position up and down in the duct in response to changes in a patient's position. The pancreatic duct empties quite promptly, usually in 1 to 2 minutes. Delayed emptying may be indicative of pancreatic disease.<sup>12</sup>

The pancreatic duct is easier to cannulate because of its perpendicular relation to the duodenum, and it is usually visualized with the initial injection. When a single duct system filled is not the clinically relevant one, the catheter must be realigned so that the other will opacify, or the papilla must be reprobated for a second opening should this first maneuver fail. For selective cannulation of the common

**Table 1.** Endoscopic retrograde cholangiopancreatography (ERCP); indications

---



---

Differential diagnosis of obstructive biliary disease
Suspected biliary tract disease
Hepatobiliary disease of undetermined etiology
Suspected pancreatic disease
Chronic pancreatitis
Pseudocyst
Carcinoma
Recurrent acute pancreatitis
Postoperative evaluation of biliary or pancreatic surgical procedures
Abdominal pain of unknown etiology

---



---

bile duct, the catheter is directed in an oblique upward direction. The procedure requires from 20 to 60 minutes, with an average time of 35 minutes. Fluoroscopy time is minimized. Irradiation will also eventually cause yellowing of the glass fiber bundles of the duodenoscope.

The papilla of Vater has occasionally appeared edematous, indurated, and inflamed. This appearance of the papilla is associated with spasm of the sphincter of Oddi, and frequently makes cannulation difficult. Kasugai et al<sup>13</sup> have described a close correlation between the severity of papillary abnormalities, and the degree of underlying pancreatic disease, usually chronic pancreatitis.

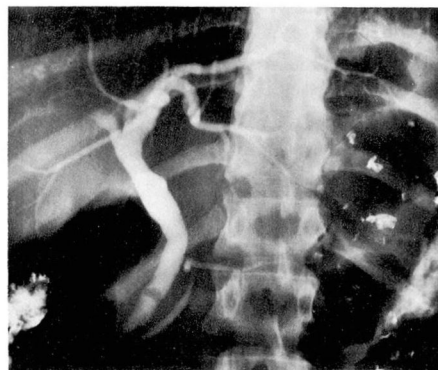
On occasion, retrograde filling of a ductal system will not be obtained despite what appears to be an optimal angle of entry for the catheter. This has been found in some cases to be due to retropapillary disease in the form of tumor or impacted stone.<sup>27</sup> Dickinson et al<sup>28</sup> recommend surgical exploration in these circumstances. However, these findings can also be

due to misalignment of the catheter, and recommendation of operation depends to a certain extent on the skill and experience of the operator. A stone impacted in the ampulla was the cause of this in one patient in this series, but in others it resulted from technical errors.

When difficulty in cannulation of the main papilla is encountered, it is sometimes rewarding to attempt cannulation of the accessory papilla. This is found in about 20% of cases,<sup>24, 25</sup> and is located about 2 cm proximal and anterior to the main papilla. There may be as many as three accessory papillae.<sup>24</sup> Injection of contrast medium may demonstrate a duct ending blindly,<sup>28</sup> but often the accessory duct communicates with the main pancreatic duct, or may in fact be the major channel for pancreatic secretion. In this case, injection will demonstrate the ductal system.<sup>25</sup> This was accomplished in one case in our series.

### Indications

The indications for ERCP are given in *Table 1*. The investigation of biliary tract disease (*Fig. 3*) and chronic pancreatitis (*Figs. 4-7*) have proved to be the most rewarding in terms of



**Fig. 3.** Common bile duct stone.



positive contributions to the care of the patient. The lowest percentage of positive diagnoses was found with procedures done because of abdominal pain of unknown etiology. However, it has been found to be useful in this situation when an effort is undertaken

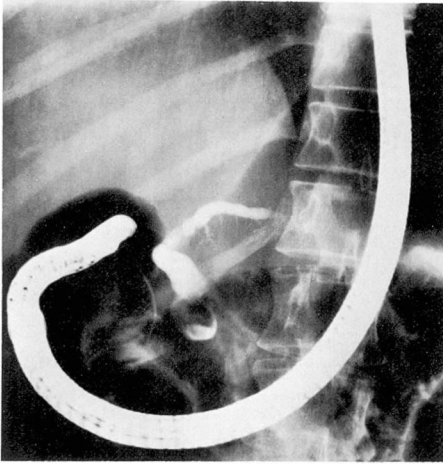


Fig. 4. Chronic pancreatitis with obstructed duct. Subsequent distal pancreatectomy.

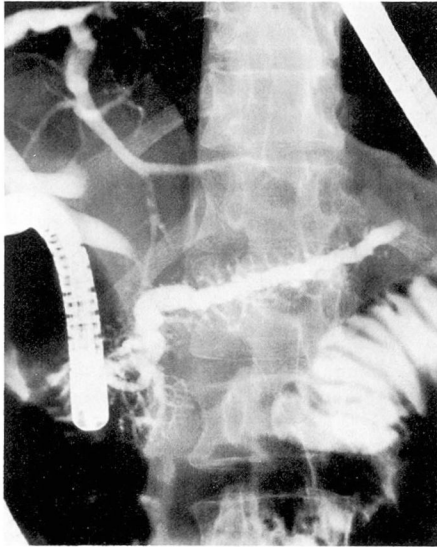


Fig. 5. Chronic pancreatitis; shortened, dilated, irregular pancreatic duct, and dilated irregular main pancreatic duct branches.

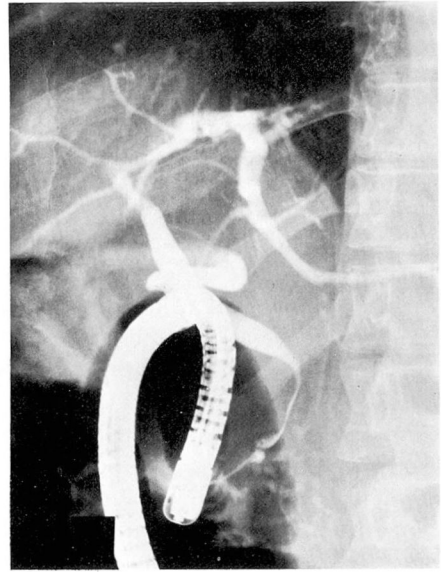


Fig. 6. Same case as in Figure 5. Tapering common bile duct.

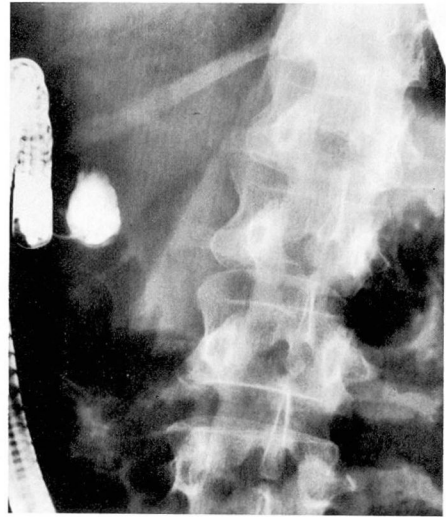


Fig. 7. Pseudocyst in head of pancreas.

to exclude pancreatic disease as the cause of a patient's discomfort.<sup>29</sup> Nebel and Fornes<sup>30</sup> found ERCP to be most helpful in the investigation of obstructive jaundice, recurrent pancreatitis, and chronic pancreatitis. Some authors

have stressed the value of the procedure when done preoperatively<sup>31</sup> both for diagnosis and as an aid to the surgeon in selecting the proper type of operation. We have utilized it to evaluate pancreatic and biliary surgical procedures, and in nine such instances it proved to be significantly useful in the management of the patient. One can also evaluate the results of sphincterotomy, pancreaticojejunostomy, and the status of biliary-enteric anastomoses.

**Contraindications**

ERCP is contraindicated in any patient who has had a clinical episode of pancreatitis, or who has had a significant elevation of the serum or urinary amylase level, within 2 weeks prior to the procedure. Silvis et al<sup>15</sup> recommend stricter criteria, and do not perform the procedure within 4 weeks of the occurrence of an amylase elevation. Ogoshi et al<sup>32</sup> state that they have performed the procedure during episodes of acute pancreatitis for purposes of diagnosis and have encountered no complications. Episodes of severe pancreatitis have occurred when ERCP was performed in close proximity to an episode of pancreatitis. Cotton<sup>24</sup> regards a positive hepatitis-associated antigen, especially in a jaundiced patient, as a contraindication. Since the procedure is not sterile, there is a theoretical potential for transmission of hepatitis virus from patient to patient, and retrograde ductal to systemic pathways have been demonstrated in the pancreas.<sup>33, 34</sup> However, most authors do not regard a positive antigen as a contraindication. The procedure should not be carried out in a moribund patient, or one unable to tolerate endoscopy for other medical reasons.

**Results**

One hundred nineteen procedures were attempted in 109 patients over a period of 1 year. Overall success rate for cannulation with retrograde filling was 66%. In several cases, failure was due to equipment breakdown or because other abnormalities were encountered such as carcinoma of the duodenum or peptic ulcer disease. If these cases of failure are eliminated from consideration, the overall success rate is 72%. Sixty-two pancreatograms and 43 cholangiograms were obtained. The procedure was judged to have provided useful information in 63% of the total number of patients. The diagnoses are listed in *Table 2*. In two cases ERCP provided falsely positive information.

**Complications**

Serial serum amylase determinations were made in 60 patients. Significant elevations occurred in 43%, in some cases in excess of 1,000 Somogyi units (normal less than 200 units). Hyperamylasemia occurred most often with filling of the pancreatic duct, although

**Table 2.** Endoscopic retrograde cholangiopancreatography (ERCP); diagnoses

Common bile duct stone	5
Common bile duct stricture	5
Common bile duct obstruction	1
Carcinoma of common bile duct	1
Dilated common bile duct	3
Sclerosing cholangitis	1
Pericholangitis	1
Hepatic duct stone	1
Chronic pancreatitis	8
Carcinoma of pancreas	2
Pancreatic duct obstruction	2
Pseudocyst of pancreas	2

significant elevations were recorded in 3 of 12 patients in which only the common bile duct was filled. Transient abdominal pain or back pain at the time of injection, which has also been noted by other authors,<sup>26, 27, 29, 30, 35, 36</sup> occurred in 13 patients. This had no relationship to the occurrence or level of hyperamylasemia or to the occurrence of post-ERCP pancreatitis. Amylase elevations generally were recorded at about 6 hours after the procedure, and in most cases returned toward normal at about 18 hours post-ERCP. Hyperamylasemia did not occur in any patient in whom a diagnosis of chronic pancreatitis was made. Howard and Short<sup>3</sup> found that with operative pancreatography serum amylase values changed very little if the pancreas was markedly fibrotic. Cotton<sup>24</sup> found the highest elevations in patients with radiographically normal pancreatic ducts. Classen et al<sup>37</sup> and Kasugai et al<sup>38</sup> found more frequent and higher elevations in patients in whom filling with contrast of the pancreatic acini was produced.

Hyperamylasemia also occurred in patients in whom the papilla was probed, but retrograde injection was not accomplished. Blackwood et al<sup>39</sup> found an equal occurrence of elevated values with opacification of either the common bile duct alone or pancreatic duct alone. In their study the overall incidence of amylase elevation in ERCP was 41.9%. Elevations also occurred in 6.6% of patients who underwent routine upper gastrointestinal endoscopy without attempted cannulation, although this did not occur if only the esophagus was examined. Blackwood et al<sup>39</sup> and others<sup>26</sup> have suggested that manipulation of the papilla of Vater is the common factor

in hyperamylasemia. Kasugai et al<sup>17</sup> have shown that with injection pressures less than 870 mm of water, no significant amylase elevation occurs.

Acute pancreatitis developed in one patient. This 27-year-old woman had a normal pancreatogram, but developed post-ERCP abdominal pain, hyperamylasemia, leukocytosis, and fever which persisted for 6 days. One death due to fatal pancreatic necrosis is included in the literature,<sup>40</sup> and episodes of post-ERCP pancreatitis have been reported by many authors.<sup>15, 40-43</sup> Cotton<sup>24</sup> estimated the rate of occurrence of pancreatitis as 1% to 2% of cases during 1972. Galvan and Koltz<sup>41</sup> reported a severe case of post-ERCP pancreatitis, and reviewed the possible causes for this. They included an abnormally sensitive ductal epithelium in patients with previous pancreatitis, toxic irritative and hyperosmotic effects of the contrast medium, excessive injection pressure, direct trauma to the papilla of Vater, and activation of proteolytic enzymes.

Aprotinin (Trasyolol), a trypsin inhibitor, has been employed by some Japanese endoscopists,<sup>35, 44</sup> and they have reported that it reduces the incidence of post-ERCP pancreatitis and hyperamylasemia. Cotton<sup>24</sup> found it to be of no benefit in 40 patients, and animal studies<sup>45</sup> have shown it to have no preventive action against induced pancreatitis.

Sepsis is the second major complication. This occurred in one patient in whom a partial biliary obstruction was demonstrated. Sepsis has been reported in two situations. The first occurred when contrast medium was injected past a point of marked biliary obstruction.<sup>19, 26, 46</sup> It can also occur with opacification of a pseudocyst,<sup>15</sup>

and it is advisable to use only the smallest amount of contrast required to demonstrate such cysts. One death was reported<sup>15</sup> with opacification of a pseudocyst. In these situations in which sepsis is a possibility, early surgical intervention and the use of broad spectrum antibiotics have been recommended,<sup>15, 19, 24, 26</sup> and we adhere to this. Prophylactic antibiotic administration has been advocated by Japanese endoscopists,<sup>35, 38</sup> but in this country it is used mainly when the likelihood of sepsis is increased.

### Summary

Endoscopic retrograde cholangiopancreatography (ERCP) was shown to be useful in 63% of patients who underwent the procedure. ERCP has assumed a prominent role in the investigation of pancreatic and biliary disease. The procedure is contraindicated in patients with recent amylase elevations or episodes of pancreatitis. Hyperamylasemia alone should not be considered a true complication. Post-ERCP pancreatitis and sepsis are the major complications of the procedure, and these complications occurred in one of 109 patients who underwent the procedure.

### References

1. Doubilet H, Mulholland JH: Intubation of the pancreatic duct in the human. *Proc Soc Exp Biol Med* 76: 113-114, 1951.
2. Doubilet H, Poppel MH, Mulholland JH: Pancreatography; technics, principles and observations. *Radiology* 64: 325-339, 1955.
3. Howard JM, Short WF: An evaluation of pancreatography in suspected pancreatic disease. *Surg Gynecol Obstet* 129: 319-324, 1969.
4. Leger L: Surgical contrast visualization of the pancreatic ducts with a study of pancreatic external secretion. *Am J Dig Dis* 20: 8-12, 1953.
5. Pollock AV: Pancreatography in the diagnosis of chronic relapsing pancreatitis. *Surg Gynecol Obstet* 107: 765-770, 1958.
6. Rabinov KR, Simon M: Peroral cannulation of the ampulla of Vater for direct cholangiography and pancreatography. *Radiology* 85: 693-697, 1965.
7. McCune WS, Shorb PE, Moscovitz H: Endoscopic cannulation of the ampulla of Vater. *Ann Surg* 167: 752-756, 1968.
8. Kasugai T, Kuno N, Aoki I, et al: Fiberoendoscopy; analysis of 353 examinations. *Gastrointest Endosc* 18: 9-16, 1971.
9. Takagi K, Ikeda S, Nakagawa Y: Retrograde pancreatography and cholangiography by fiber duodenoscope. *Gastroenterology* 59: 445-452, 1970.
10. Oi I, Kobayashi S, Kondo T: Endoscopic pancreatocholangiography. *Endoscopy* 2: 103-106, 1970.
11. Oi I: Fiberoendoscopy and endoscopic pancreatocholangiography. *Gastrointest Endosc* 17: 59-62, 1970.
12. Belsito AA, Cramer GG, Dickinson PB: Delayed ductal drainage; an endoscopic pancreatographic sign of carcinoma of the head of the pancreas. *Am J Roentgenol Radium Ther Nucl Med* 119: 109-114, 1973.
13. Kasugai T, Kuno N, Kizu M, et al: Endoscopic pancreatocholangiography II. The pathological endoscopic pancreatocholangiogram. *Gastroenterology* 63: 227-234, 1972.
14. Norton RA, Ogoshi K, Hara Y, et al: Pancreatographic abnormalities due to pancreatic cancer. *Gastrointest Endosc* 20: 3-14, 1973.
15. Silvis SE, Rohrmann CA, Vennes JA: Diagnostic criteria for the evaluation of the endoscopic pancreatogram. *Gastrointest Endosc* 20: 51-55, 1973.
16. Howard JM, Nedwich A: Correlation of histologic observations and operative findings in patients with chronic pancreatitis. *Surg Gynecol Obstet* 132: 387-395, 1971.
17. Kasugai T, Kuno N, Kizu M: Endoscopic pancreatocholangiography with special reference to manometric method. *Med J Aust* 2: 717-725, 1973.
18. Blumgart LH, Cotton PB, Burwood R, et al: Endoscopy and retrograde choledochopancreatography in the diagnosis of the jaundiced patient. *Lancet* 2: 1269-1272, 1972.



19. Vennes JA, Jacobson JR, Silvis SE: Endoscopic cholangiography for biliary system diagnosis. *Ann Intern Med* 80: 61-64, 1974.
20. Göthlin J, Tranberg K: Complications of percutaneous transhepatic cholangiography. *Am J Roentgenol Radium Ther Nucl Med* 117: 426-431, 1973.
21. Hines C Jr, Ferrante WA, Davis WD Jr, et al: Percutaneous transhepatic cholangiography: experience with 102 procedures. *Am J Dig Dis* 17: 868-873, 1972.
22. Morrissey JF: To cannulate or not to cannulate (Editorial). *Gastroenterology* 63: 351-352, 1972.
23. Ingelfinger FJ: Endoscopic pancreatocholangiography; progress and problem. *N Engl J Med* 287: 879-880, 1972.
24. Cotton PB, Progress report. Cannulation of the papilla of Vater by endoscopy and retrograde cholangiopancreatography (ERCP). *Gut* 13: 1014-1025, 1972.
25. Vennes JA, Silvis SE: Endoscopic visualization of bile and pancreatic ducts. *Gastrointest Endosc* 18: 149-152, 1972.
26. Dickinson PB, Belsito AA, Cramer GC: Diagnostic value of endoscopic cholangiopancreatography. *JAMA* 225: 944-948, 1973.
27. Gregg JA: Cannulation of the ampulla of Vater. *Am J Gastroenterol* 60: 142-156, 1973.
28. Gregg JA: Retrograde cannulation of the ampulla of Vater. A preliminary report. *Med Clin North Am* 56: 781-788, 1972.
29. Nagy GS: Endoscopic pancreatocholangiography. *Med J Aust* 2: 725-729, 1973.
30. Nebel OT, Fornes MF: Endoscopic pancreatocholangiography. *Am J Dig Dis* 18: 1042-1050, 1973.
31. Kozower M, Norton RA, Paul RE, et al: Preoperative endoscopic cannulation of pancreatic and biliary ducts. *Ann Surg* 178: 197-199, 1973.
32. Ogoshi K, Niwa M, Hara Y, et al: Endoscopic pancreatocholangiography in the evaluation of pancreatic and biliary disease. *Gastroenterology* 64: 210-216, 1973.
33. Bockman DE, Schiller WR, Anderson MC: Route of retrograde flow in the exocrine pancreas during ductal hypertension. *Arch Surg* 103: 321-329, 1971.
34. Waldron RL, Luse SA, Wollowick HE, et al: Demonstration of a retrograde pancreatic pathway; correlation of roentgenographic and electron microscopic studies. *Am J Roentgenol Radium Ther Nucl Med* 111: 695-699, 1971.
35. Okuda K, Someya N, Goto A, et al: Endoscopic pancreatocholangiography. A preliminary report on technique and diagnostic significance. *Am J Roentgenol Radium Ther Nucl Med* 117: 437-445, 1973.
36. Safrany L, Tari J, Barna L, et al: Endoscopic retrograde cholangiography: experience of 168 examinations. *Gastrointest Endosc* 19: 163-168, 1973.
37. Classen M, Koch H, Ruskin H, et al: Pancreatitis after endoscopic retrograde pancreatography (ERP). (Abstr) *Gut* 14: 431, 1973.
38. Kasugai T, Kuno N, Kobayashi S, et al: Endoscopic pancreatocholangiography. I. The normal endoscopic pancreatocholangiogram. *Gastroenterology* 63: 217-226, 1972.
39. Blackwood WD, Vennes JA, Silvis SE: Post-endoscopy pancreatitis and hyperamylasuria. *Gastrointest Endosc* 20: 56-58, 1973.
40. Ammann RW, Deyhle P, Butikofer E: Fatal necrotizing pancreatitis after peroral cholangiopancreatography. *Gastroenterology* 64: 320-323, 1973.
41. Galvan A, Koltz AP: Is transduodenal pancreatography ever contraindicated? A case report of provoked pancreatitis and pseudocyst. *Gastrointest Endosc* 20: 28-30, 1973.
42. Liguory C, Goerou H, Monnier JP, et al: Endoscopic catheterization of the pancreatic ducts. *Sem Hop Paris* 49: 529-535, 1973.
43. Stadelmann VO, Sobbe A, Löffler A, et al: Die Bedeutung der retrograden Pankreatocholangiographie für die klinische Diagnostik. *Fortschr Röntgenstr* 118: 377-390, 1973.
44. Takagi K, Ikeda S, Nakagawa Y, et al: Endoscopic cannulation of the ampulla of Vater. *Endoscopy* 2: 107-115, 1970.
45. Wollowick HE, Waldron RL II, Woo SA: The protective effect of Trasylol versus contrast-media-induced pancreatitis. *J Assoc Canad Radiol* 22: 40-43, 1971.
46. Robbins AH, Paul RE Jr, Norton RA, et al: Detection of malignant disease by peroral retrograde pancreato-biliary ductography. *Am J Roentgenol Radium Ther Nucl Med* 117: 432-436, 1973.