

Carcinoma of the posterior pharyngeal wall

Surgical management with preservation of the larynx

Harvey M. Tucker, M. D.

*Department of Otolaryngology and
Communicative Disorders*

By far the majority of malignancies involving the posterior pharyngeal wall do so by extension from, or in conjunction with, primary lesions of nearby structures, such as the tonsil, base of tongue, or larynx. On occasion, however, there will be encountered isolated malignancies of the pharyngeal wall without direct involvement of adjacent structures. In all but the smallest of such lesions, adequate exposure for surgical excision has been difficult to obtain and it has generally been considered necessary to sacrifice the larynx, even in those cases in which it was not directly involved.¹ Experience with surgical management of these lesions has suggested that both excellent exposure and preservation of the larynx can be achieved by employing one of three surgical approaches.

Background and surgical considerations

Until recently, most reports on carcinoma of the pharynx have not separated lesions of the pyriform sinus, vault of the nasopharynx and of tonsillar origin from those involving the pharyngeal wall proper.¹⁻³ Wilkins,⁴ in 1971, reported an overall survival rate of 36.4% for isolated pharyngeal wall lesions, regardless of treatment modality. However, the survival rate

for those managed by definitive surgical excision was 62.5%. Ballantyne¹, in a similar series, obtained a 50% survival rate for primary surgical patients. Although both these series are small, they indicate that primary surgical management, with or without planned preoperative radiotherapy, may offer better hope for cure than primary radiotherapy, with surgery reserved for still operable failures.

The majority of malignancies of the posterior pharyngeal wall are epidermoid carcinoma, but lymphomas, minor salivary gland tumors, and other adenocarcinomas are also encountered. Because the mucosa of this area is an endodermal derivative, carcinomas of a less well-differentiated type are encountered here than are found in the mouth, for example, but somewhat better differentiated than those of the tonsil. These lesions are often multicentric and show a definite propensity to spread vertically in the submucosal plane, only to present as apparently separate lesions at some distance from the "parent" lesion. For this reason, diagnostic evaluation should include multiple biopsies at different sites, after supravital staining with toluidine blue to identify skip areas.⁵ First station nodal metastases are usually to the retropharyngeal nodes which, fortunately, should be encompassed by adequate surgical excision of the primary lesion. Another significant factor in determining operability of these lesions is the relative resistance of the anterior spinal ligament to direct invasion.

Adequate exposure of the posterior pharyngeal wall may be obtained in several ways. For very small lesions, transoral, transhyoid, or lateral

pharyngotomy may be suitable.⁴ Larger lesions have generally been treated by laryngectomy with partial or total pharyngectomy and suitable reconstruction of the pharyngoesophagus. Older discussions recommend laryngectomy even when this structure is not directly involved on the grounds that (1) this maneuver yields excellent exposure for excision and reconstruction, and (2) that the patient will be unable to swallow satisfactorily after extensive removal of the pharyngeal wall, due, presumably, to loss of pharyngeal mobility and aspiration.⁴

It is beyond the scope of this discussion to consider the indications for and against elective neck dissection in these cases. Where clinically palpable nodes exist, concomitant ipsilateral or staged contralateral radical neck dissection or both is mandatory. However, in the absence of palpable adenopathy, the surgeon must either adopt an expectant approach or do *bilateral* neck dissections, inasmuch as there is no real propensity for metastasis to one side of the neck or the other in lesions of this type.

It is the purpose of this paper to present three approaches that have permitted primary excision of carcinomas of the posterior pharyngeal wall, affording good exposure, yet allowing preservation of the uninvolved larynx and reconstruction of the swallowing mechanism.

Midline labiomandibuloglossotomy

The midline lip, jaw, and tongue splitting approach to the pharyngeal wall was popularized by Martin et al.⁶ Their technique was based on previous descriptions by Syme⁷ in 1865 and by Trotter⁸ in 1928. This ap-

proach takes advantage of the relative avascularity of the midline and results in excellent exposure from above the soft palate down to at least the level of the arytenoid cartilages. Harrold⁹ has suggested a larynx splitting addition to this procedure to improve exposure even below this level, but we have found that this is unnecessary. Furthermore, a lesion requiring such an inferior extent of resection would probably be better handled by a more extensive resection. The cosmetic results of the labiomandibuloglossotomy approach are excellent and speech is not affected. After wide resection of the primary lesion down to the anterior spinal ligament, we have found the use of a dermal graft an excellent means of

closure, although some authors⁴ have simply left the wound open. We also recommend cricopharyngeal myotomy and have had no problems with deglutition by using this approach.

Case reports

Case 1. A 63-year-old man had a superficial multicentric squamous cell carcinoma of the posterior pharyngeal wall involving the midline from the level of the uvula to just superior to the tips of the arytenoid cartilages (*Fig. 1*). There was no palpable adenopathy in either side of the neck. Except for mild chronic emphysema, he was in good health. A radiotherapy consultant was of the opinion that adequate treatment for cure carried significant risk of injury to the spinal cord. After tracheotomy, the lesion was ap-

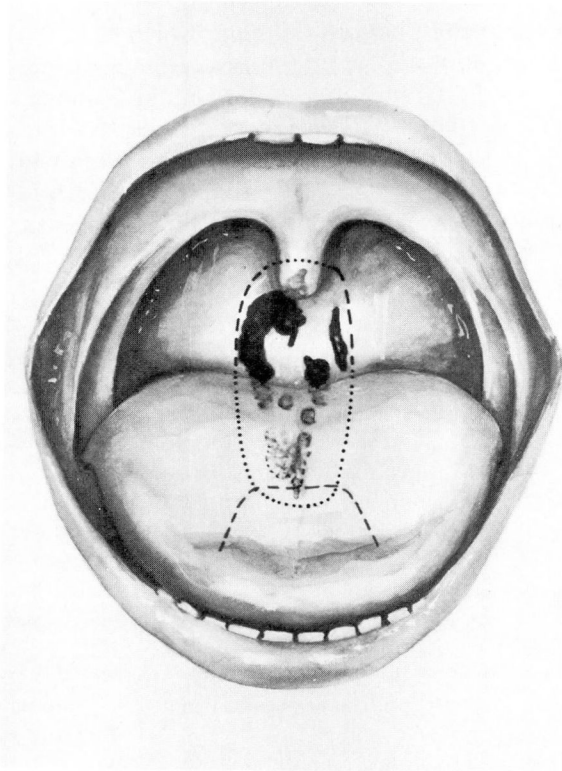


Fig. 1. Multicentric squamous cell carcinoma of posterior pharyngeal wall.

proached via a midline labiomandibuloglossotomy with wide en bloc excision down to the anterior spinal ligament (*Fig. 2*). A cricopharyngeal myotomy was performed and a dermal graft was used for repair. The patient's postoperative course was uneventful, with prompt return of normal speech and deglutition. Five years after surgery there is no evidence of recurrence.

Lateral jaw, pharynx, radical neck (composite) resection

An approach similar to that employed for resection of tonsillar malignancies may be used, particularly when the lesion involves primarily one half of the posterior or lateral pharyngeal wall or both. Although primary closure of such a defect might be achieved, this would result in significant loss of tongue mobility, as well as narrowing of the pharynx. Therefore, we have routinely employed a medially based deltopectoral chest flap.¹⁰ Such a repair has the additional advantage of providing a temporary, controlled fistula, which is a definite help in these patients, most of whom will have received high-dose preoperative irradiation.¹¹

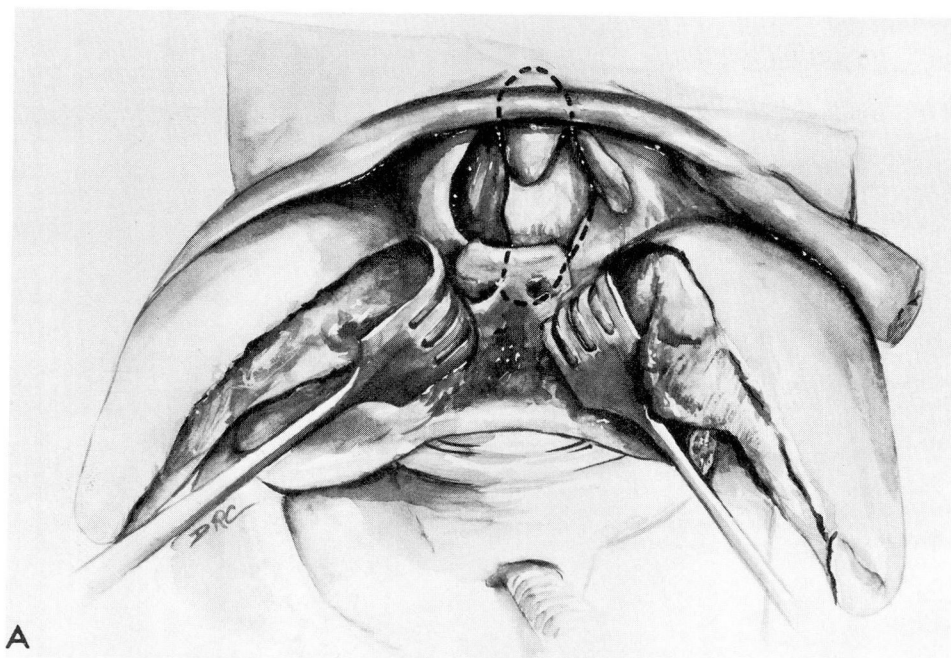
Case 2. A 40-year-old woman had an exophytic squamous cell carcinoma of the left posterior pharyngeal wall extending from 1 cm below the torus tubarius down to 1 cm above the level of the arytenoid. Lateral involvement was from just to the left of the midline to the junction of the posterior and lateral pharyngeal walls (*Fig. 3*). There was a 1 x 1-cm moveable node palpable in the left midjugular chain; 5500 r preoperative radiotherapy was delivered over a 5-week period to the primary lesion and both sides of the neck. Five weeks thereafter, a left pharynx, jaw, radical neck dissection was undertaken after preliminary tracheotomy (*Fig. 4*). A cricopharyngeal myotomy was performed, following which, a left medially

based deltopectoral flap was used for repair (*Fig. 5*). Five weeks thereafter, the flap was released and returned to the chest wall. The patient healed promptly and was able to swallow with only minor difficulty 2 weeks later. She is alive and well with no recurrence 3 years after surgery.

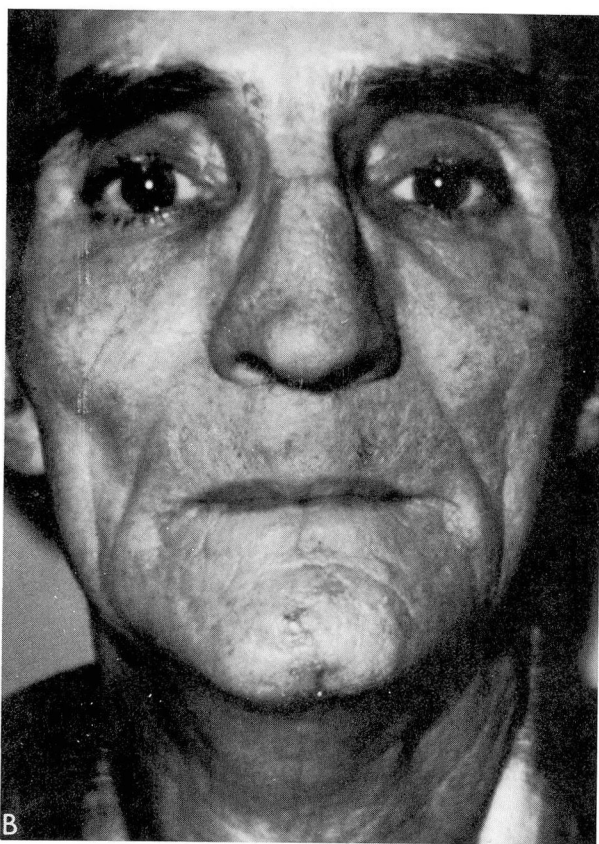
Combined approach

With large midline lesions, especially when there is palpable cervical disease, it would be difficult to achieve adequate visualization for resection and repair via the lateral approach alone, especially if the larynx is to be preserved. In such cases, we have found that the lateral approach (without sacrifice of the jaw) may be combined with midline labiomandibuloglossotomy to achieve excellent visualization. The neck dissection is left attached only to the lateral and posterior pharyngeal walls. At this point, the midline approach is used to allow en bloc excision of the lesion, which can then be delivered through the neck incision. After cricopharyngeal myotomy, repair is again by means of a medially based deltopectoral flap.

Case 3. A 59-year-old man was seen with a large, exophytic lesion of the midline of the posterior pharyngeal wall, extending from the level of the soft palate above to the level of the tips of the arytenoids below. Its lateral extension was essentially from the junction of the lateral and posterior pharyngeal wall on the right to the same point on the left (*Fig. 6*). There was a 2 x 2-cm mass palpable in the right midjugular chain. The larynx itself was uninvolved; 5500 r preoperative radiotherapy was delivered to the primary lesion and both sides of the neck over a 5-week period. Five weeks thereafter, following preliminary tracheotomy, the primary lesion and contents of the right neck were resected via a combined lateral



A



B

Fig. 2. A, Midline labiomandibuloglossotomy approach to posterior pharyngeal wall. B, Postoperative appearance.

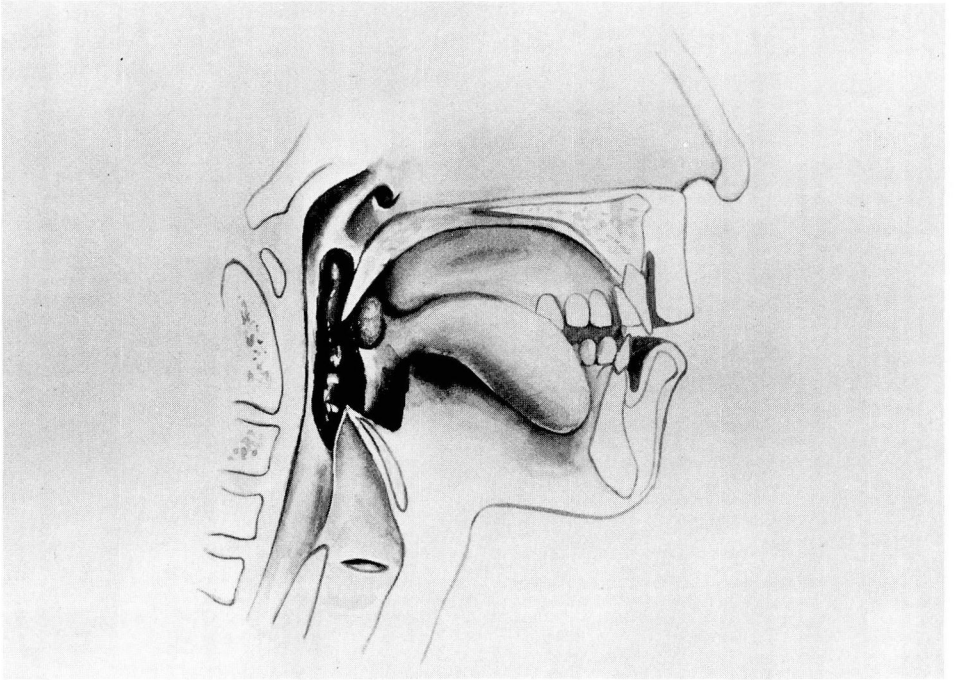


Fig. 3. Squamous cell carcinoma of lateral pharyngeal wall.

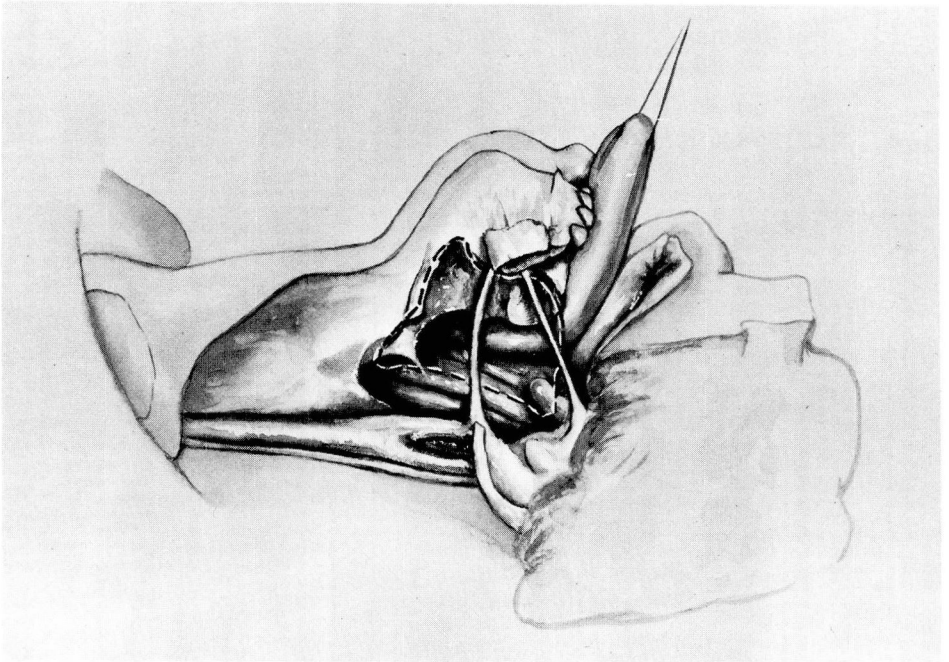


Fig. 4. Surgical defect. Note intact lingual nerve and XIIth cranial nerve crossing defect.

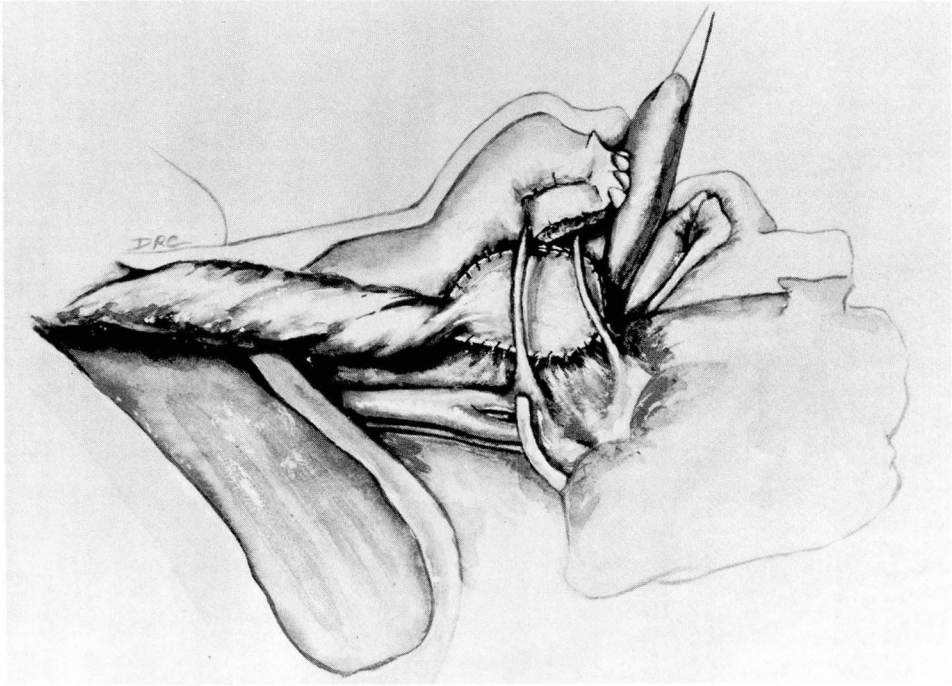


Fig. 5. Medially based deltopectoral flap in place.

and midline labiomandibuloglossotomy approach (*Fig. 7*). This resulted in a defect comprising essentially the entire posterior and lateral pharyngeal walls from just below the torus tubarius to the hypopharynx. A right medially based deltopectoral flap was used for repair. Five weeks later the chest flap was released and returned to the chest. Within 3 weeks of this second procedure, the patient was able to maintain nutrition by mouth, although he was restricted to virtually a soft diet. Aspiration was at most an occasional problem. It was originally planned to perform an elective contralateral neck dissection when he was fully recovered from these procedures. However, 1 month following his discharge after the second procedure, he was noted to have a new primary carcinoma of the base of the tongue. Because of the patient's wishes and his general physical condition, this was treated with radioactive gold seed implant with an initially

good response. Three months thereafter there was obvious widespread local recurrence of the lesion with pulmonary metastasis. This resulted in his death 1 year after completion of the primary reconstruction of his first lesion. He was able to maintain nutrition orally until the time of recurrence of the second lesion.

Discussion

Proper surgical management of carcinoma of the head and neck requires, among other things, that adequate exposure be obtained to permit accurate, en bloc excision of the primary lesion and its metastatic field, as well as suitable reconstruction. Because of the difficult location of the lesions of the posterior pharyngeal wall, coupled with expected problems with deglutition, it has been generally held that the larynx should be sacrificed even when not directly

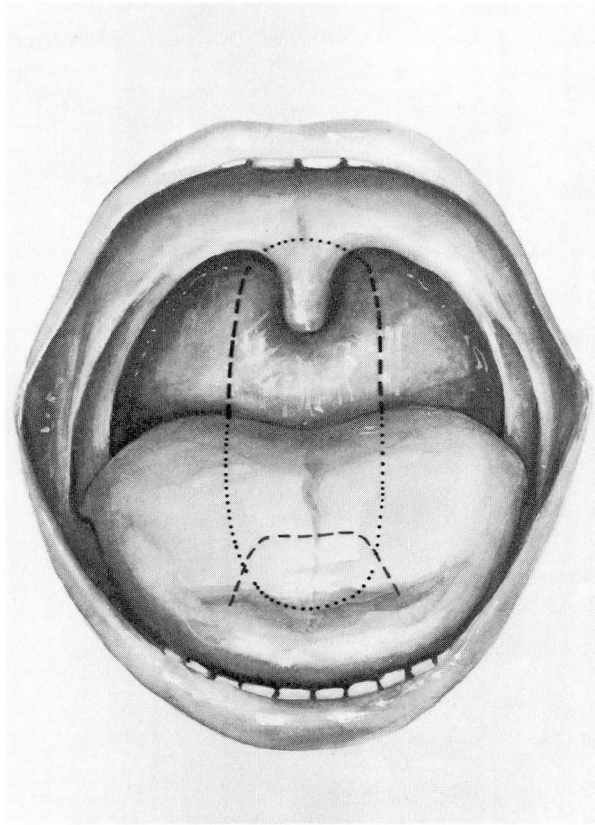


Fig. 6. Extensive carcinoma of posterior pharyngeal wall.

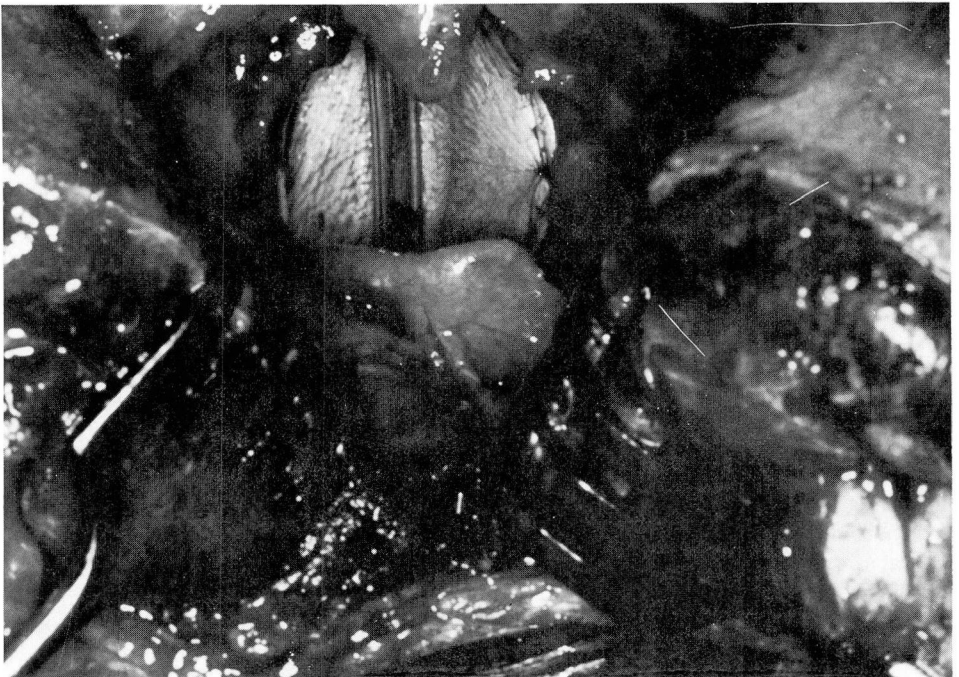

Fig. 7. Medially based deltopectoral flap in place. Note skin in defect of posterior pharyngeal wall.

involved. To be sure, such an operation offers good exposure, permits wide margins of resection, and generally avoids swallowing problems. On the other hand, our experience with surgical approaches that attempt to "conserve" the uninvolved larynx suggests that careful selection of patients and planning of reconstructive procedures can be successful.

Preservation of the uninvolved larynx essentially adds two risks to those already inherent in total laryngopharyngectomy. They are (1) compromise of adequate resection leading to possible recurrence, and (2) problems with deglutition. It is possible, with careful planning, to obtain good margins by one of the three surgical approaches outlined. Problems with swallowing can be avoided for the most part by performing an adequate cricopharyngeal myotomy in all cases and by preserving the superior laryngeal nerves, thus maintaining an intact laryngeal closure reflex during deglutition. It is important to note that, as with other "conservation" procedures, this approach carries with it greater risk of complications than more conservative methods. This must be weighed against the potential benefits in each case and, above all, the patient must be aware of the additional risks involved.

Conclusion

Reported experience with surgical management of carcinoma of the posterior pharyngeal wall suggests that cure rates can be superior to those reported for radiotherapy. It has been generally held, however,

that even the uninvolved larynx must be sacrificed in most of these cases, in order to gain adequate exposure and to avoid postoperative problems with deglutition. Our experience suggests that, in selected cases, the larynx can be successfully preserved by utilizing one of the three approaches reported herein.

References

1. Ballantyne AJ: Methods of repair after surgery for cancer of the pharyngeal wall, postcricoid area, and cervical esophagus. *Am J Surg* **122**: 482-486, 1971.
2. Berg JW, Schottenfeld D, Hutter RVP, et al: Histology, epidemiology and end results. The Memorial Hospital Cancer Registry. Memorial Hospital for Cancer and Allied Diseases, New York, 1969, p 18.
3. Clinical staging system for carcinoma of the pharynx. American Joint Committee for Cancer Staging and End Results Reporting. Chicago, May 1965.
4. Wilkins SA Jr: Carcinoma of the posterior pharyngeal wall. *Am J Surg* **122**: 477-481, 1971.
5. Strong MS, Vaughan CW, Incze JS: Toluidine blue in the management of carcinoma of the oral cavity. *Arch Otol* **87**: 527-531, 1968.
6. Martin H, Tollefsen HR, Gerold FP: Median labiomandibular glossotomy. *Am J Surg* **102**: 753-759, 1964.
7. Syme J: Excision of the tongue. *Lancet* **1**: 115, 1865.
8. Trotter W: Operations for malignant disease of the pharynx. *Br J Surg* **16**: 485-495, 1928.
9. Harrold CC Jr: Excision of cancer of the posterior pharyngeal wall with preservation of the normal larynx; a new surgical approach. *Surgery* **61**: 498-502, 1967.
10. Bakamjian VY: Total reconstruction of pharynx with medially based deltopectoral skin flap. *New York J Med* **68**: 2771-2778, 1968.
11. Tucker HM, Rabuzzi DD, Sagerman RH, et al.: Prevention of complications of composite resection after high dose preoperative radiotherapy. *Laryngoscope* **84**: 933-939, 1974.