

# Use of the internal mammary artery for myocardial revascularization

Manuel J. Irarrazaval, M.D.

*Department of Thoracic and  
Cardiovascular Surgery*

Selecting the optimal graft for direct myocardial revascularization has been the aim of cardiac surgeons since the technique was established in 1967.

The saphenous vein graft that was used originally proved to be a reliable material. However, despite increasing technical sophistication, the patency rate has remained between 70% and 82% in men and 10% to 15% lower in women.<sup>1-4</sup>

In 1950, Vineberg implanted the internal mammary artery (IMA) in the myocardium and observed significant clinical improvement, but it was not until 1959 that Sones<sup>5</sup> demonstrated by coronary angiography the development of communication between the IMA and the coronary system in some patients. In 1964, Kolessov<sup>6</sup> first performed a direct anastomosis between the IMA and the coronary artery for treatment of angina pectoris. Initially, coronary angiography was not available to evaluate his results. In 1968, Green<sup>7</sup> successfully performed IMA anastomosis and reported his results with 165 clinical cases in 1971. That same year, Loop et al<sup>8</sup> modified the technique for constructing IMA anastomosis without high power optical assistance.

In the past 5 years the IMA has become a popular alternative for myocardial revasculari-

zation, even though the technique is more difficult than that for saphenous vein grafting. This relative disadvantage has been outweighed by the higher patency rate, the necessity of only one anastomosis, and the excellent clinical results. The reason for the higher patency rate is probably related to less discrepancy between the size of the IMA and the size of the coronary arteries, or the smaller diameter of the IMA with its attendant higher velocity of blood flow.

### Technique

The IMA is dissected from the chest wall with the help of the Favalaro sternal retractor applied after the median sternotomy is completed. The dissection is completed in 10 to 15 minutes and it is carried out by electrocautery and silver clips to ligate the branches of the artery. When mobilization is complete, the artery is sprayed with a papaverine solution and wrapped in a sponge soaked in the same vasodilator. Great care is taken not to injure the artery by obtaining a wide pedicle with vein and surrounding tissues.

Immediately before using the artery, the distal end is sectioned and blood flow through the pedicle is estimated. With experience, one can easily determine whether the flow is satisfactory; flow may be measured by allowing free flow into a container (60 ml/min is considered the minimum of acceptable flow). Rigid adherence to standards for flow and anatomic integrity of this pedicle are the reasons for good results with the graft.

### Indications

At the Cleveland Clinic, the IMA is the graft of choice for revascularization of the left anterior descending

artery, except when contraindicated for the following reasons: (1) Patients who must undergo operation on an emergency basis are usually excluded because of the additional time required for dissection. (2) Patients with left main trunk obstruction do not receive IMA revascularization for the same reason, and also their perfusion deficit may be too large for the IMA graft. (3) Hypertrophic ventricles frequently require high blood flow; e.g., patients with valve dysfunction or hypertension. The IMA is seldom able to carry more than 150 ml/min when initially connected. (4) When there is question about the patency of the left subclavian artery or the IMA. This is suggested by the presence of subclavian bruits, evidence of extensive brachiocephalic disease, previous surgery in the region, radiation therapy of the chest wall, or diffuse atherosclerosis associated with old age.

### Results and discussion

Between 1972 and 1974, 2,008 patients had revascularizations with IMA grafts alone or in combination with saphenous vein grafts. The hospital mortality was 1% and the perioperative myocardial infarction was 4.3%. The patency rate in 491 of these patients studied 1 year after surgery was 96.3% (*Table 1*).

Although the IMA provides superior patency, some investigators question its ability to provide adequate flow. In November 1975, Siegel et al<sup>9</sup> reported on their experience with a group of postoperative patients who had been revascularized with a single graft, the IMA or saphenous vein. Patency was proved by postoperative angiogram. This group of patients submitted to exer-

cise testing, preoperatively and postoperatively, and there was no significant difference in maximum heart rate, angina, or S-T changes (Table 2). The question of long-term benefit from this type of revascularization has been discussed by Loop et al,<sup>10</sup> who analyzed results from the first 400 patients revascularized with the IMA. The composite actuarial survival was 98.3% at 1 year, 97.6% at 2

years, 97.0% at 3 years, and 96.8% at 3½ years (Figure). Concerning symptomatic improvement, 273 patients (71%) were in functional class I, 86 (22%) were functional class II, 23 (6%) were functional class III, and 4 (1%) were functional class IV. It also should be mentioned that 61% of these patients are working full time and another 29% are active but not working due to retirement or unem-

**Table 1.** IMA graft operations\*

|  | 1971<br>No. (HD) | 1972<br>No. (HD) | 1973<br>No. (HD) | 1974<br>No. (HD) | Total<br>No. (HD)   | Postoperative angiographic results |                   |             |
|--|------------------|------------------|------------------|------------------|---------------------|------------------------------------|-------------------|-------------|
|  |                  |                  |                  |                  |                     | No. IMA<br>grafts<br>studied       | No. oc-<br>cluded | %<br>patent |
| IMA graft alone                                  | 56 (1)           | 109 (0)          | 181 (0)          | 235 (1)          | 581 (2)             |                                    |                   |             |
| IMA graft with<br>one or more<br>SVGs            |                  | 255 (4)          | 461 (4)          | 585 (3)          | 1301 (11)           | 491                                | 18                | 96.3        |
| IMA graft with<br>other associated<br>procedures |                  | 5 (0)            | 23 (1)           | 21 (2)           | 49 (3)              |                                    |                   |             |
| IMA aortocoron-<br>ary grafts                    |                  | 39 (0)           | 23 (0)           | 15 (0)           | 77 (0)              | 23*                                | 2                 | 91.3        |
| Total  | 56 (1)           | 408 (4)          | 688 (5)          | 856 (6)          | 2008 (16)<br>(1.0%) |                                    |                   |             |

\* Through 1973.

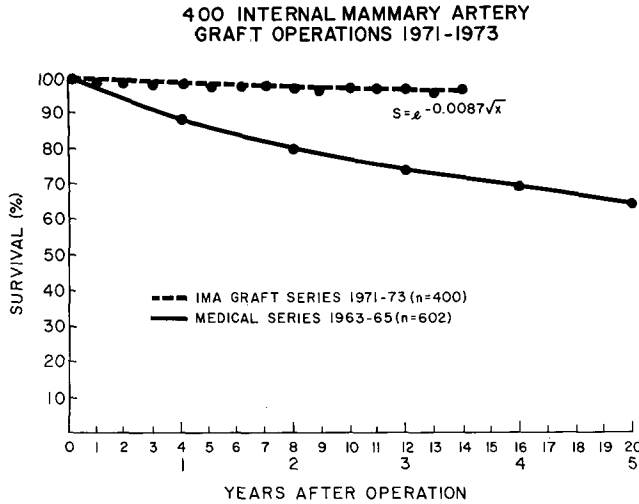
No. = number of patients; (HD) = hospital deaths.

(Reproduced by permission of Sheldon WC, et al: Surgical treatment of coronary artery disease: pure graft operations, with a study of 741 patients followed 3-7 yr. *Prog Cardiovasc Dis* 18: 237-253, 1975.)

**Table 2.** Exercise testing preoperatively and postoperatively

|                               |        | Internal mammary ar-<br>tery, n = 37 | Venous autograft, n = 26 |
|-------------------------------|--------|--------------------------------------|--------------------------|
| Maximal work capacity         | Preop  | 701 ± 40                             | 658 ± 39                 |
|                               | Postop | 914 ± 40                             | 908 ± 40                 |
| Δ/p value                     |        | +213/<.001                           | +250/<.001               |
| Maximal heart rate            | Preop  | 140 ± 4                              | 137 ± 4                  |
|                               | Postop | 157 ± 3                              | 156 ± 3                  |
| Δ/p value                     |        | +17/<.001                            | +19/<.001                |
| Maximal rate pressure product | Preop  | 206 ± 7                              | 214 ± 7                  |
|                               | Postop | 257 ± 9                              | 265 ± 9                  |
| Δ/p value                     |        | +51/<.001                            | +51/<.001                |
| Angina (%)                    | Preop  | 25 (68%)                             | 18 (69%)                 |
|                               | Postop | 4 (11%)                              | 3 (12%)                  |
| S-T (%)                       | Preop  | 32 (87%)                             | 20 (80%)                 |
|                               | Postop | 13 (35%)                             | 8 (31%)                  |
| S4 provoked                   | Preop  | 31                                   | 10                       |
|                               | Postop | 16                                   | 12                       |

(Reproduced by permission of Siegel W, et al: Comparison of interval mammary artery and saphenous vein graft for myocardial revascularization by exercise testing. American Heart Association, Anaheim, California, 1975.)



**Figure.** IMA graft operations, 1971-1973; survival.

ployment; only 1% are completely disabled. This is after a follow-up of 3 years.

We believe that the IMA in situ represents a significant step closer to the optimal graft for myocardial revascularization, since it provides excellent symptomatic results, superior patency, and prolongs survival.

### References

1. Sheldon WC, Rincon GF, Effler DB, et al: Vein graft surgery for coronary disease; survival and angiographic results in 1,000 patients. *Circulation* **48**: Suppl 3: 184-189, 1973.
2. Sheldon WC, Rincon G, Pichard AD: Results of graft surgery for coronary artery disease; a progress report. *Cardiovasc Clin* **7**: 93-107, 1975.
3. Flemma RJ, Johnson WD, Lepley D Jr, et al: Late results of saphenous vein bypass grafting for myocardial revascularization. *Ann Thorac Surg* **14**: 232-242, 1972.
4. Sheldon WC, Rincon G, Pichard AD, et al: Surgical treatment of coronary artery disease; pure graft operations, with a study of 741 patients followed 3-7 yr. *Prog Cardiovasc Dis* **18**: 237-253, 1975.
5. Sones FM, Shirey EJ: Cine coronary arteriography. *Mod Concepts Cardiovasc Dis* **31**: 735-738, 1962.
6. Kolessov VI: Mammmary artery-coronary artery anastomosis as a method of treatment for angina pectoris. *J Thorac Cardiovasc Surg* **54**: 535-544, 1967.
7. Green GE: Internal mammary artery-to-coronary artery anastomosis; three-year experience with 165 patients. *Ann Thorac Surg* **14**: 260-271, 1972.
8. Loop FD, Effler DB, Spampinato N, et al: Myocardial revascularization by internal mammary artery grafts. *J Thorac Cardiovasc Surg* **63**: 674-680, 1972.
9. Siegel W, Loop FD, Proudfit WL, et al: Comparison of internal mammary artery and saphenous vein graft for myocardial revascularization by exercise testing. American Heart Association, Anaheim, California, 1975.
10. Loop FD, Irarrazaval M, Bredee JJ, et al: The internal mammary artery graft for ischemic heart disease; effect of revascularization on survival. (Abstr) *Am J Cardiol* **37**: 152, 1975.