

Electrocardiographic findings in 125 patients with idiopathic prolapse of the mitral valve studied by angiography

Hector Lardani, M.D.
Abel Moreyra, M.D.
Sergio Manubens, M.D.
Jorge Belardi, M.D.
Miguel Fava, M.D.*
William C. Sheldon, M.D.

Department of Cardiology

A variety of pathologic conditions has been described as potentially capable of altering the complex structure of the mitral apparatus and causing prolapse of the mitral leaflets. Among them, ischemic heart disease with papillary muscle dysfunction, cardiomyopathies, rheumatic endocarditis, and myxomatous degeneration of the mitral leaflets have been postulated.¹⁻³ One should expect the electrocardiograms of such a heterogenous group of patients to reflect changes due to myocarditis, hypertrophy, ischemia, and other conditions (*Fig. 1*) depending on the underlying disease. Eventually electrocardiographic changes would have occurred whether or not the mitral apparatus was involved. On the other hand, mid-systolic click or late systolic murmurs or both have been described associated with various pathologic conditions.^{1, 4-6} Furthermore, the electrocardiographic findings reported in the literature may vary according to the criteria employed for the selection of patients. Barlow et al⁴ included 90 patients with either a late systolic murmur, a nonejection click or both regardless of the underlying pathology; patients with rheumatic and ischemic heart disease and obstructive cardiomyopathy were also included. In only 28 of the

* 9 de Julio, 2018 San Francisco
Cordoba, Argentina

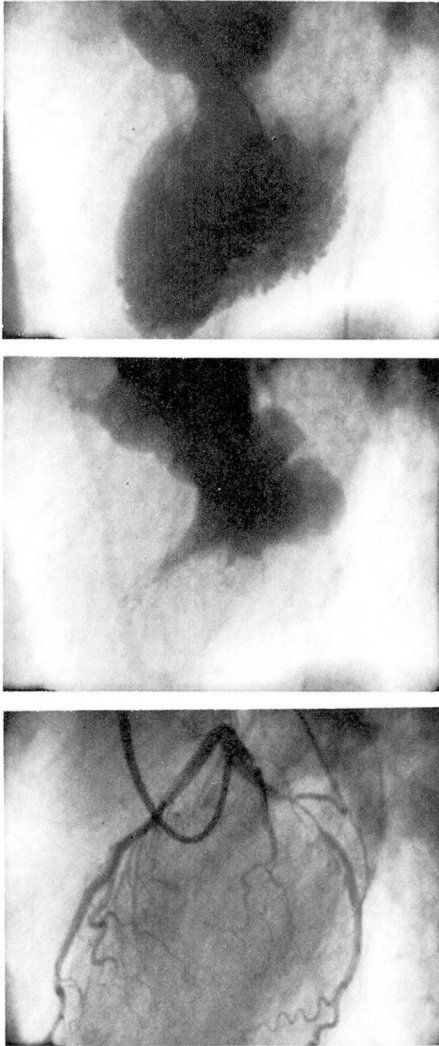


Fig. 1. A, B, Left ventriculogram end diastole and end systole in left anterior oblique view. C, Left coronary artery in left anterior oblique view. Prolapse of the leaflets of the mitral valve associated with severe obstruction of the circumflex artery. These patients were excluded from this study.

90 patients was prolapse of the mitral valve (PMV) proved by angiography, and in only two patients was the coronary circulation studied by selective angiography. Jeresaty's series⁷ included 100 patients, 77 had a nonejection click or, in the absence of

click, a PMV was proved by left ventriculography in 23 patients. Selective coronary arteriography was performed in 27 patients. Using different criteria than Barlow, Jeresaty⁷ excluded patients with isolated late systolic murmurs because of "non-specificity of this murmur." Sloman et al⁸ included 50 patients with apical late systolic murmur, a nonejection click or both. Catheterization was performed in 19 patients and selective coronary arteriography in eight. Gulotta et al⁹ included 26 patients with nonejection clicks or late systolic murmurs or both who were studied by right and left catheterization and coronary arteriograms.

A review of nine reports in which electrocardiographic aspects were outlined,^{2, 4, 7-13} a total of 380 cases were reported. In approximately 42%, PMV was proved by angiography, and in 21% the coronary circulation was studied by selective coronary arteriography.

An attempt to determine whether PMV as a primary or principal alteration has a characteristic electrocardiogram that could be useful in clinical recognition of the disease should objectively demonstrate the prolapse and exclude associated pathology.

Material and methods

From the records of the Cardiac Laboratory of The Cleveland Clinic Foundation, 125 consecutive patients with idiopathic PMV demonstrated by left ventriculography were selected for this study.

Most of the patients were referred because of chest pain, arrhythmias, abnormal electrocardiograms, or abnormal auscultatory findings. All the patients had a complete physical examination, chest x-ray, electrocardi-

ogram, routine laboratory studies, retrograde left heart catheterization, left ventriculography at 30 or 60 frames per second in 30° right anterior oblique projection, and selective coronary arteriography by Sones technique.¹⁴ In addition, 78 patients (61%) had catheterization of the right heart.

Patients with associated significant coronary artery disease (more than 40% stenosis of any of the three major coronary arteries) or with clinical, hemodynamic, or angiographic evidence of rheumatic heart disease were excluded. Patients with other pathologic conditions known to involve potentially the mitral apparatus such as idiopathic hypertrophic subaortic stenosis or ostium primum septal defect were also excluded. Three patients with ostium secundum septal defect, one patient with patent ductus arteriosus, and two with Marfan's syndrome were included. The mean age of the group was 43 years, standard deviation (SD) 12.7. There were 68 men and 57 women.

PMV was defined as excessive systolic excursion of the mitral leaflets toward the left atrium beyond the plane of the mitral annulus in right anterior oblique projection. Arbitrarily, this abnormality was classified as mild, moderate, or severe (*Fig. 2*).

The presence of mitral regurgitation was detected by visualization of contrast material entering the left atrium during left ventriculography. Mitral regurgitation was subjectively classified as mild, moderate, or severe.

Left ventriculograms were analyzed subjectively in right anterior oblique projection in all patients to estimate the left ventricular performance. A normal pattern of left ventricular contraction was considered to

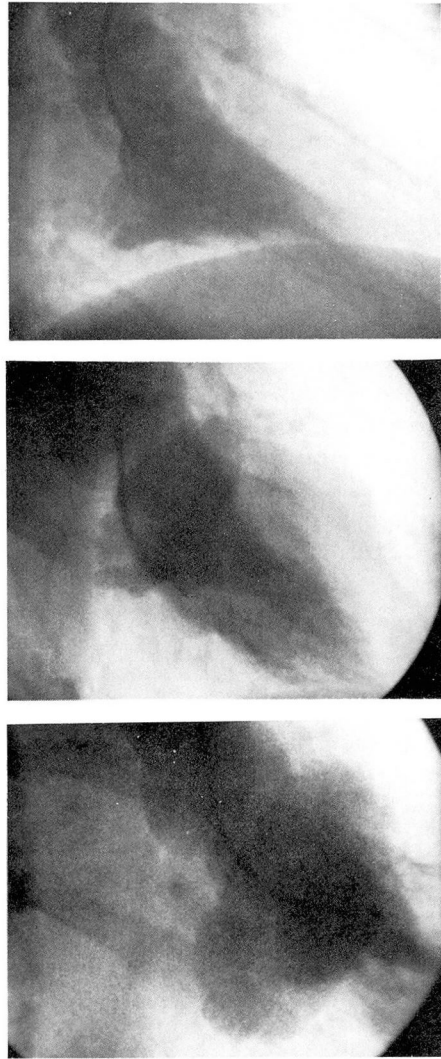


Fig. 2. A, B, C, Left ventriculograms in right anterior oblique projection. Typical examples of mild, moderate, and severe prolapse.

be present when vigorous symmetric inward motion in all visible segments of the left ventricular contour was observed. Different degrees of alteration from the normal pattern were described as mild, moderate, or severe left ventricular dysfunction. Localized areas of severe hypokinesia or akinesia were found in three patients; this abnormality was present

in all three at the apex of the left ventricle.

In 86 consecutive patients ejection fraction (EF) was calculated in nonextra or postextra systolic beats using the single plane method of Greene et al.¹⁵ In the same patients, mean velocity of circumference fiber shortening (VCS) and mean normalized ejection rate (MNER) were also calculated.¹⁶

Resting electrocardiograms obtained the day before catheterization were studied. The criteria for conduction disturbances and pattern of chamber enlargement and ventricular hypertrophy are those of the New York Heart Association.¹⁷ S-T segment depression was defined as a shift of this segment below the baseline by 1 ml or more for most of its length. The duration of QT interval was corrected for heart rate.¹⁸ A Q wave was considered abnormal when its duration was 3/100 sec or more and the voltage reached 25% of the R wave.

The data obtained from the patients' charts were processed with the assistance of a computer (PDP15 Digital Equipment Corporation). The chi-square method was used to determine the statistical significance of the correlations performed. $P < 0.05$ was considered significant. Mean values of other parameters are accompanied by the standard error of the mean.

Results

A. Catheterization and angiographic findings

Degree of prolapse. Forty-three patients (34%) had mild, 63 (50%) moderate, and 19 (16%) severe PMV.

Mitral regurgitation. Sixty-nine patients had competent mitral valves (55%); 31 (25%) had mild, 18 (14%)

moderate, and 7 (6%) severe mitral regurgitation.

Left ventricular function. By subjective estimation, 94 patients (75%) were found to have normal left ventricular function. Mild ventricular dysfunction was present in 26 patients (21%), and moderate in five patients (4%).

In the 86 consecutive patients in whom EF, VCS, and MNER were calculated, the results were $81\% \pm 1.12$; 1.95 ± 0.07 ; and 3.03 ± 0.09 respectively; comparable with the values reported in patients with normal myocardial function.¹⁶

Coronary circulation. One hundred-nine patients (87%) had normal coronary arteries. Eleven patients (9%) had mild lumen irregularities without detectable obstructive lesions. Five patients (4%) had 30% or 40% stenosis of one coronary artery. The average systolic and diastolic blood pressure of the group was 129 mm Hg, SD 17.9 and 78 mm Hg, SD 9.9, respectively.

B. Electrocardiographic findings (Table)

Twenty-two patients (17%) were taking digitalis and 13 (10%) were taking quinidine at the time the electrocardiogram was obtained. The heart rate obtained from the tracings ranged between 60 and 89 beats per minute in 71% of the patients. Three percent had less than 50, and 5% more than 100 beats per minute.

I. Normal electrocardiogram

For the purpose of this study, we did not include under this heading patients with premature atrial or ventricular contractions and otherwise normal tracings. The electrocardiogram was normal in 29 patients

Table. Electrocardiographic findings; idiopathic prolapse of the mitral valve; 125 patients

Findings	No. of patients*	%
I. Normal electrocardiogram	29	23.2
II. Abnormalities		
1. Rhythm		
Sinus	118	94.4
Atrial fibrillation	6	4.8
Atrioventricular block	1	0.8
Premature ventricular contraction	22	17.6
Premature atrial contraction	2	1.6
2. S-T-T abnormalities		
T inversion in 2-3-AVF	45	36.0
T inversion in 1-AVF-V5-V6	19	15.2
ST 1-AVL-V5-V6	18	14.4
ST 2-3-AVF	5	4.0
3. QTC abnormalities		
Prolonged QTC	16	12.8
Short QTC	1	0.8
4. Conduction disturbances		
First degree atrioventricular block	4	3.2
Third degree atrioventricular block	1	0.8
Incomplete right bundle branch block	10	8.0
Complete left bundle branch block	1	0.8
Left anterior hemiblock	2	1.6
5. Atrial and ventricular hypertrophy		
Left atrial enlargement	15	12.0
Left ventricular hypertrophy	9	7.2
Right atrial enlargement	3	2.4
Right ventricular hypertrophy	1	0.8
6. Abnormal Q waves and poor progression of R wave in right precordial leads		
Q 2-3-AVF	8	6.4
Q 1-AVL-V5-V6	3	2.4
PPR waves	9	7.2

* Due to the coexistence of two or more abnormalities in some cases, the number of patients in this table exceeds 125.

(23%). Thirteen patients had mild, 14 had moderate, and 2 had severe degrees of PMV. This incidence was not significantly different from the rest of the patients having abnormal electrocardiograms. Twenty-six of the 29 patients had either competent mitral valves or mild mitral regurgitation. Only three patients had moderate, and one had severe mitral regurgitation (*Fig. 3*). Twenty-six of the 29 patients had normal coronary arteries and three had mild coronary artery disease, proportions similar to

the patients with abnormal electrocardiograms.

II. Abnormalities

1. Rhythm. One hundred eighteen patients were in sinus rhythm. Six had atrial fibrillation and one had complete atrioventricular block.

Premature beats. Premature ventricular contractions were present in 22 patients (17%). Four patients had premature atrial contractions. Age, sex, intake of digitalis, degree of PMV, or presence of or degree of

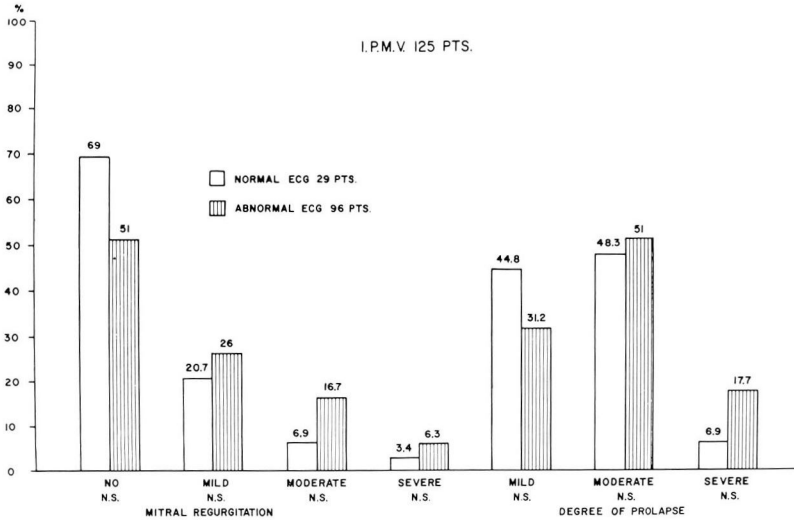


Fig. 3. Twenty-six of 29 patients with normal electrocardiograms had competent mitral valves or mild mitral regurgitation (89.7%). No significant correlation with the degree of prolapse was found.

mitral regurgitation were not statistically different in patients with premature ventricular contractions as compared to the entire group.

Atrial fibrillation occurred in six patients (4%). Five had moderate or severe mitral regurgitation, one had a competent mitral valve. This incidence of mitral regurgitation was significantly higher as compared to the rest of the group ($p < 0.05$) (Fig. 4). The degree of PMV was mild in three patients and moderate in three. The incidence was not statistically different as compared to the rest of the patients without atrial fibrillation.

2. S-T-T abnormalities. Abnormal T waves in leads 2-3 and AVF occurred in 45 patients (36%). In 19 patients, this pattern was associated with T wave inversion in left precordial leads (15% of total group). Other coexistent abnormalities were left atrial enlargement (7 patients), poor progression of the R wave in right precordial leads (2 patients), S-T depression V5-V6 (1 patient), prolonged QTC (2 patients), and left

ventricular hypertrophy (1 patient). There was no correlation between abnormal T wave in 2-3 and AVF and the degree of PMV (Fig. 5) or the presence or degree of mitral regurgitation.

S-T depression in I-AVL-V5-V6 (1 mm or more) was present in 18 patients (14%). Two thirds of the patients with this abnormality were taking digitalis, a proportion significantly higher than the group of patients without this alteration ($p < 0.01$). Four fifths of the patients with S-T depression had coexistent S-T or T abnormalities in 2-3-AVF, prolonged QT segment, poor progression of R wave precordial leads, incomplete right bundle branch block, and first degree AV block. In two patients the S-T alteration coexisted with left ventricular hypertrophy. Of the six patients not taking digitalis, one had mild PMV, four had moderate PMV, and one had severe PMV. Two had competent mitral valves, two mild, one moderate, and one severe mitral regurgitation. No patient

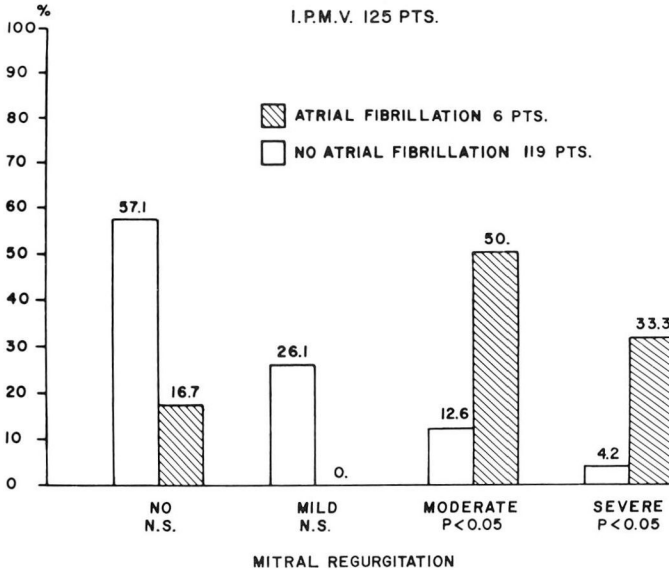


Fig. 4. Five of six patients with atrial fibrillation had moderate or severe mitral regurgitation (83.3%) incidence significantly higher as compared to the rest of the patients.

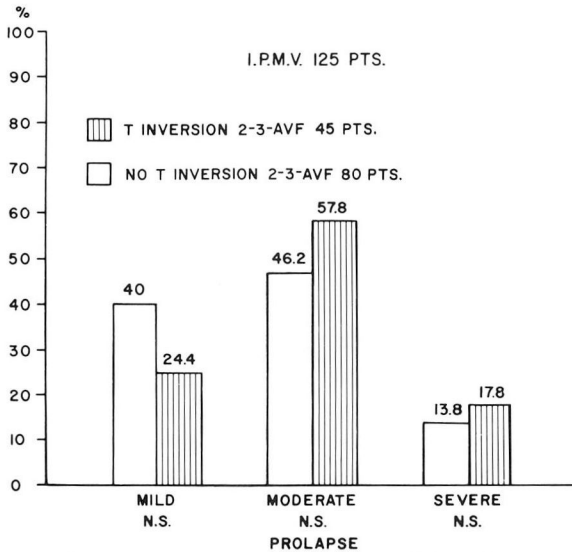


Fig. 5. The lack of correlation between T inversion in 2-3-AVF and degree of prolapse is evident.

had a coexistent pattern of left ventricular hypertrophy. S-T depression in 2-3-AVF occurred in five patients; four were receiving digitalis therapy.

3. QTC abnormalities. QTC was prolonged in 16 patients (12%). Six patients were taking quinidine. One patient had short QTC and was not

taking digitalis. There was no correlation between prolonged QTC and presence or degree of mitral regurgitation or degree of prolapse in either group with or without quinidine.

4. Conduction disturbances. First degree atrioventricular block occurred in four patients (3%). Two of

these patients were taking digitalis (one also had gross calcification of the mitral leaflets). The other two had a moderate degree of mitral regurgitation and diffuse hypokinesia of the left ventricle (one mild and one moderate). One of these patients had Marfan's syndrome and heavy calcification of the mitral ring.

Third degree atrioventricular block was present in only one patient in whom Stokes-Adams syndrome secondary to complete atrioventricular block developed at age 58. A pacemaker was inserted 3 years later. Cardiac catheterization disclosed the presence of severe PMV, mild mitral regurgitation, mild coronary artery disease, and localized hypokinesia at the apex of the left ventricle. No calcification of the mitral leaflets or ring was detected.

Incomplete right bundle branch block was present in 10 patients (8%). Three patients had associated atrial septal defects. In five of the seven patients without atrial septal defects the pulmonary artery pressure was measured and it was slightly elevated in one patient (32/15) and normal in the other four. There was no correlation between this pattern and the degree of PMV and presence or degree of mitral regurgitation.

Complete left bundle branch block occurred in only one patient. The pressure in the left ventricle was elevated (175/100); he had no mitral regurgitation. The left ventriculogram showed mild diffuse hypokinesia.

Left anterior hemiblock was present in two patients; in one systolic hypertension was present (180/90 mm Hg). This patient has normal coronary arteries, mild mitral regurgitation, mild PMV, and normal left ventriculogram. The second patient had normal aortic pressure, 40% narrow-

ing of the left anterior descending artery, mild mitral regurgitation, moderate PMV, and normal left ventriculogram.

5. Atrial and ventricular hypertrophy. Left atrial enlargement occurred in 15 patients (12%). Eleven had mitral regurgitation (mild in three, moderate in six, severe in two). This was significantly higher as compared to the patients without a pattern of left atrial enlargement ($p < 0.05$) (Fig. 6). No significant hemodynamic alterations were encountered to explain the presence of left atrial enlargement in the remaining four patients. The mean left atrial pressure in these patients was 6, 13, 10, and 4 mm Hg (average 8.3 ± 3.5). Only 13 was slightly above the normal values.¹⁹ There was no correlation between the presence of left atrial enlargement and the degree of PMV.

Left ventricular hypertrophy was present in nine patients (7%). Eight had moderate or severe mitral regurgitation, an incidence significantly higher than patients without left ventricular hypertrophy ($p < 0.05$) (Fig. 7). One patient had mild mitral regurgitation and mild labile hypertension. No correlation with the degree of prolapse was obtained.

Right atrial enlargement was found in three patients (2%). In two patients an atrial septal defect with pulmonary hypertension was present (PAP 87/42 and 100/40). One had a competent mitral valve and the other had moderate mitral regurgitation. The third patient with right atrial enlargement had no atrial septal defect, mild mitral regurgitation, and normal PAP. Right ventricular hypertrophy occurred in one patient with associated atrial septal defect and pulmonary hypertension (100/40).

6. Abnormal Q waves and poor

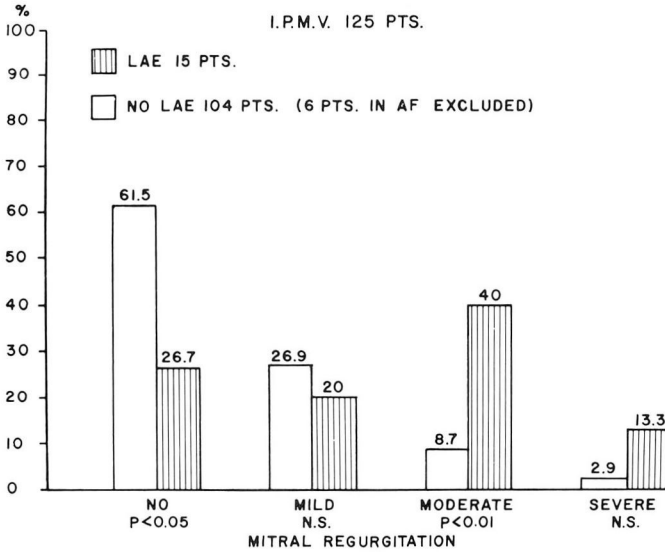


Fig. 6. Patients with left atrial enlargement had higher incidence of moderate and severe mitral regurgitation as compared to the rest of the patients.

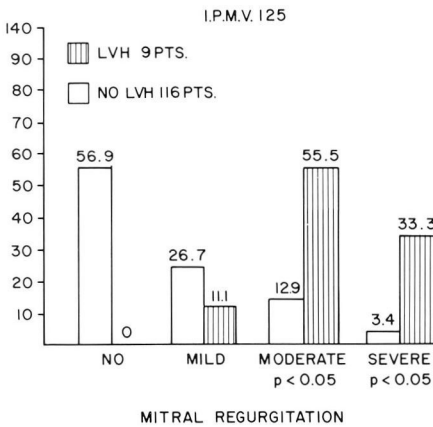


Fig. 7. Patients with left ventricular hypertrophy had higher incidence of moderate and severe mitral regurgitation as compared to the rest of the patients.

progression of R wave in right precordial leads. Abnormal Q waves in 2-3-AVF was present in eight patients. Seven patients had normal coronaries and one had mild irregularities without significant obstructions. Examination of the ventriculograms showed no areas of akinesia in the diaphragmatic wall or apex. No

patient had an associated pattern of left ventricular hypertrophy. Three patients had mild mitral regurgitation and five had competent mitral valves. Two had mild, five had moderate, and one had severe PMV. None of these associations were statistically different when compared with the rest of the group.

Abnormal Q wave in 1-AVL-V5-V6 was present in three patients (2%). There was no akinesia of the anterior wall or apex in the ventriculogram. No patients had left ventricular hypertrophy.

Poor progression of the R wave in right precordial leads (PPR) occurred in nine patients (7%); seven were women and two were men. The presence of PPR was not related to left ventricular hypertrophy, left anterior hemiblock, mitral regurgitation, or akinesia of the anterior wall.

Discussion

I. Normal electrocardiograms were reported previously and according to the authors in the literature

reviewed, the incidence varied between 10% (17) and 60% (11). Analyzing the possible relationship between the degree of prolapse and the presence of normal or abnormal electrocardiograms, we noted that 16 patients with normal electrocardiograms had moderate or severe prolapse. This is strongly suggestive of no relationship between the electrocardiogram and degree of PMV, which is in disagreement with previous reports describing more pronounced prolapse in patients with electrocardiographic changes.^{4, 20} Significant mitral regurgitation was less frequent in these patients than in those with abnormal electrocardiograms. Nonpublished data from our laboratory suggest a predictive value toward uncomplicated long-term evolution in patients with PMV when a normal electrocardiogram is present.²¹

II. Abnormalities

1. Rhythm. The large majority of patients, 118, were in sinus rhythm.

Premature ventricular contractions. In previous reports the incidence varies approximately between 20% and 40%.^{2, 7-10, 13} There was no correlation with the presence of mitral regurgitation or the degree of prolapse.

Atrial fibrillation was previously reported in the literature.^{4, 7, 9} The presence of moderate or severe mitral regurgitation in five of these patients suggests that the leak is on the basis of its development in the majority of patients. No correlation exists between atrial fibrillation and degree of prolapse.

The etiology of the arrhythmias in PMV remains obscure. The possibility of a cardiomyopathy on the basis

of PMV was raised by several authors.^{9, 22, 23} At least in our series of patients studied in the resting state, myocardial dysfunction was a relatively rare occurrence either by subjective or objective evaluation of the ventriculograms. The benign course of the large majority of the patients with PMV in the absence of significant mitral regurgitation is another strong argument against coexistent cardiomyopathy.²¹ Furthermore, in a study by Pomerance²² of 36 cases with PMV found among 3,083 autopsies in an adult general hospital with patients an average age of 73.6 years and none younger than age 50, our view that cardiomyopathy is unlikely to be the underlying pathology in PMV is supported.

Experiments performed in dogs suggest that the mitral valve could be the source of ectopic impulses which may eventually trigger premature contractions at the atrial or ventricular level.²⁴ This is an attractive hypothesis that remains to be demonstrated in humans.

2. S-T-T abnormalities. T wave inversion is one of the most frequent abnormalities described in previous reports. Its incidence varies from 18% to 42%.^{2, 13}

In our patients the degree of PMV or the presence or degree of mitral regurgitation showed no correlation with this alteration. The absence of patients with significant coronary artery disease in our series and the normal appearance and distribution of the coronary arteries by selective coronary arteriography is strong evidence against an ischemic basis for these electrocardiographic changes. Furthermore, we were unable to detect any systodiastolic variation in the lumen of branches of the circumflex

to give support to the theory of compression of the vessel by the PMV.²⁵ The absence of significant left ventricular dysfunction in our series suggests that it is very unlikely that a cardiomyopathy would be implicated. The etiology of this frequent finding remains obscure.

S-T depression in 1-AVL-V5-V6 was frequently described as associated with PMV.^{4, 7-9, 11, 13} In 12 of our 18 patients, it was related to intake of digitalis preparations. S-T depression in 1-AVL-V5-V6 in the absence of digitalis and without associated pattern of left ventricular hypertrophy seems to be related to the presence of moderate or severe prolapse, but the number of patients is too small to make a definite conclusion. No correlation with mitral regurgitation was observed. S-T depression 2-3-AVF in our group was most probably due to digitalis effect.

3. QTC abnormalities. Prolonged QTC was reported before.^{12, 26, 27} In six of our patients this could be attributed to quinidine effect. In the 10 patients not on a regimen of quinidine, no correlation was found between this abnormality and the degree of PMV or mitral regurgitation.

In the familial prolonged QT syndrome high incidence of sudden death probably due to arrhythmias has been reported.²⁸ The only two patients that died suddenly in a series of 137 patients with PMV from this laboratory²¹ had normal QTC. Thus, there is no apparent relationship between the two entities.

4. Conduction disturbances. First degree atrioventricular block. In two of our four patients the disturbance could be attributed to digitalis effect. In one of these patients and in another patient not taking digitalis,

heavy calcification of the mitral ring was noted. We may speculate that extension of the calcification over the conductive system could be the cause for the atrioventricular block. One of these patients had typical features of Marfan's syndrome. James et al²⁹ reported on two young patients with Marfan's syndrome who died as a consequence of conduction disturbances and arrhythmias in which pathologic changes in the nodal arteries were encountered at the autopsy. Bowers³⁰ described two patients with first degree atrioventricular block in 13 patients with Marfan's syndrome and "primary" abnormality of the mitral valve without associated aortic valve disease.

Complete atrioventricular block occurred in only one patient. Age, history, clinical, and angiographic findings are in favor of a coincidental pathology.

Incomplete right bundle branch block. In three of our patients incomplete right bundle branch block could be attributed to the presence of atrial septal defect. In the remaining seven patients, no hemodynamic alteration was present to account for the electrocardiographic pattern and no correlation with the degree of PMV was found. Jeresaty⁷ noted the same abnormality in 6% of his patients in the absence of atrial septal defect. Barker and Valencia³¹ found no definite cardiac pathology in 39 of 96 subjects with incomplete right bundle branch block. Tapia and Proudfit³² postulated that the right lower chest leads seem to be of clinical value in clarifying the significance of this pattern. These special leads were not used in this report due to the retrospective character.

Left anterior hemiblock. In one of

our two patients, the presence of hypertension could be the cause of the conduction defect. In the other patient, there was a 40% narrowing in the left anterior descending artery apparently not severe enough to cause ischemia. The presence of a normal left ventriculogram excludes cardiomyopathy and anterior myocardial infarction with subsequent partial recanalization of the left anterior descending artery as possible etiologic factors.

5. Atrial and ventricular hypertrophy. Left atrial enlargement. In 11 of 15 patients, left atrial enlargement may have been a consequence of the hemodynamic alteration resulting from mitral regurgitation. One of the remaining four patients had a mean atrial pressure of 13 mm Hg and a left ventricular pressure of 160/12 mm Hg. There was no clear-cut history of hypertension, but the high systolic and borderline high diastolic pressure of the left ventricle could be due to mild labile hypertension and secondary mild left ventricular hypertrophy. No explanation is available for the three patients with the pattern of left atrial enlargement with normal left atrial pressures.

Left ventricular hypertrophy has been a frequent finding in the literature reviewed, varying greatly among different authors and including up to 35% of the cases in some series.^{8-13, 22} In eight of our nine patients, left ventricular hypertrophy seems to be related to the presence of significant mitral regurgitation. The remaining patient had mild mitral regurgitation and mild labile hypertension.

Right atrial enlargement and right ventricular hypertrophy. Pulmonary hypertension was the underlying factor in the two patients with right

atrial enlargement. A pattern of right ventricular hypertrophy was also present in one of these patients.

6. Abnormal Q wave and poor progression of R wave in right precordial leads. Abnormal Q waves in 2-3-AVF and 1-AVL-V5-V6 have been previously reported.⁸⁻¹⁰ Pomerance²² reported on two patients with an electrocardiographic pattern compatible with myocardial infarction of 35 autopsies of patients with PMV. In one patient with a pattern of anterior necrosis, myocardial infarction was present. No infarction was found in the other patient with a pattern of inferior myocardial infarction. The absence of significant coronary artery disease in our series and the lack of correlation with the findings in the left ventriculogram make this electrocardiographic pattern very difficult to understand. We have not seen any evidence of distortion, occlusion, systodiastolic changes or absence of the circumflex artery or its atrioventricular branch in the coronary arteriograms of 125 patients as had been postulated in the literature.^{22, 33}

Poor progression of R wave in R precordial leads. The presence of seven women in the group seems to make this abnormality less reliable as a pattern of anterior wall infarction.³⁴ The absence of a correlation with akinesia in the left ventriculogram supports this view.

Summary and conclusions

In a series of 125 patients with angiographically proven PMV in which associated ischemic or rheumatic heart disease was specifically excluded clinically and angiographically, no characteristic electrocardiogram was identified.

Twenty-nine patients (23.2%) had

normal electrocardiograms regardless of the degree of prolapse present. Patients with normal electrocardiograms seem to have a benign prognosis. A variety of abnormalities were observed which failed to predict the degree of prolapse.

Most frequent electrocardiographic findings were T wave inversions in 2-3 and AVF occurring in 45 patients (36%), 19 of whom also had associated T wave inversion in I-AVL-V5-V6.

The presence of atrial fibrillation, left atrial enlargement, or left ventricular hypertrophy in patients with idiopathic prolapse of the mitral valve suggest association of significant mitral regurgitation and are nonspecific of this entity.

References

1. Shell WE, Walton JA, Clifford ME, et al: The familial occurrence of the syndrome of mid-late systolic click and late systolic murmur. *Circulation* **39**: 327-337, 1969.
2. Selzer A, Katayama F: Mitral regurgitation; clinical patterns, pathophysiology and natural history. *Medicine* **51**: 337-366, 1972.
3. Barlow JB, Pocock WA: The problem of nonejection systolic clicks and associated mitral systolic murmurs; emphasis on the billowing mitral leaflet syndrome. *Am Heart J* **90**: 636-655, 1975.
4. Barlow JB, Bosman CK, Pocock WA, et al: Late systolic and nonejection ("mid-late") systolic clicks. *Br Heart J* **30**: 203-218, 1968.
5. Leachman RD, DeFrancheschi A, Zamalloa O: Late systolic murmurs and clicks associated with abnormal mitral valve ring. *Am J Cardiol* **23**: 679-683, 1969.
6. Dock W: Production mode of systolic clicks due to mitral cusp prolapse. *Arch Intern Med* **132**: 118-125, 1973.
7. Jeresaty RM: Mitral valve prolapse-click syndrome. *Prog Cardiovasc Dis* **15**: 623-652, 1973.
8. Sloman G, Stannard M, Hare WSC, et al: Prolapse of the posterior leaflet of the mitral valve. *Israel J Med Sci* **5**: 727-731, 1969.
9. Gulotta SJ, Gulco L, Padmanabhan V, et al: The syndrome of systolic click, murmur, and mitral valve prolapse—a cardiomyopathy? *Circulation* **49**: 717-728, 1974.
10. Sloman G, Wong M, Walker J: Arrhythmias on exercise in patients with abnormalities of the posterior leaflet of the mitral valve. *Am Heart J* **83**: 312-317, 1972.
11. Stannard M, Sloman JG, Hare WSC, et al: Prolapse of the posterior leaflet of the mitral valve; a clinical, familial, and cineangiographic study. *Br Med J* **3**: 71-74, 1967.
12. Gooch AS, Vicencio F, Maranhao V, et al: Arrhythmias and left ventricular asynergy in the prolapsing mitral leaflet syndrome. *Am J Cardiol* **29**: 611-620, 1972.
13. Fontana ME, Pence HL, Leighton RF, et al: The varying clinical spectrum of the systolic click-late systolic murmur syndrome; a postural auscultatory phenomenon. *Circulation* **41**: 807-816, 1970.
14. Sones, FM Jr, Shirey EK: Cine coronary arteriography. *Mod Concepts Cardiovasc Dis* **31**: 735, 1962.
15. Greene DG, Carlisle R, Grant C, et al: Estimation of left ventricular volume by one-plane cineangiography. *Circulation* **35**: 61-69, 1967.
16. Peterson KL, Skloven D, Ludbrook P, et al: Comparison of isovolumic and ejection phase indices of myocardial performance in man. *Circulation* **49**: 1088-1101, 1974.
17. New York Heart Association: Nomenclature and Criteria for Diagnosis of the Heart and Great Vessels, ed 7, Boston, Little, Brown and Company, 1973.
18. Hurst JW: *The Heart*, ed 3, New York, McGraw-Hill Book Co, 1974.
19. Zimmerman HA: *Intravascular Catheterization*, ed 2, Springfield, Illinois, Charles C Thomas, 1972.
20. Ronan JA Jr: The systolic click-late systolic murmur syndrome. *Med Ann DC* **43**: 13-15, 1974.
21. Belardi J, Lardani H, Manubens S, et al: Idiopathic prolapse of the mitral valve; a follow up study in 137 patients studied by angiography. (Abstr) *Am J Cardiol* **37**: 120, 1976.
22. Pomerance A: Ballooning deformity (mucoid degeneration) of atrioventricular valves. *Br Heart J* **31**: 343-351, 1969.
23. Scampardonis G, Yang SS, Maranhão V, et al: Left ventricular abnormalities in prolapsed mitral leaflet syndrome; review of eighty-seven cases. *Circulation* **48**: 287-297, 1973.

24. Wit AL, Fenoglio JJ Jr, Wagner BM, et al: Electrophysiological properties of cardiac muscle in the anterior mitral valve leaflet and the adjacent atrium in the dog; possible implications for the genesis of atrial dysrhythmias. *Circ Res* **32**: 731-745, 1973.
25. Barlow JB, Bosman CK: Aneurysmal protrusion of the posterior leaflet of the mitral valve; an auscultatory-electrocardiographic syndrome. *Am Heart J* **71**: 166-178, 1966.
26. Hancock EW, Cohn K: The syndrome associated with midsystolic click and late systolic murmur. *Am J Med* **41**: 183-196, 1966.
27. Shappell SD, Marshall CE, Brown RE, et al: Sudden death and the familial occurrence of mid-systolic click, late systolic murmur syndrome. *Circulation* **48**: 1128-1134, 1973.
28. Singer PA, Crampton RS, Bass NH: Familial Q-T prolongation syndrome; convulsive seizures and paroxysmal ventricular fibrillation. *Arch Neurol* **31**: 64-66, 1974.
29. James TN, Frame B, Schatz IJ: Pathology of cardiac conduction system in Marfan's syndrome. *Arch Intern Med* **114**: 339-343, 1964.
30. Bowers D: Primary abnormalities of the mitral valve in Marfan's syndrome; electrocardiographic findings. *Br Heart J* **31**: 676-678, 1969.
31. Barker JM, Valencia F: The precordial electrocardiogram in incomplete right bundle branch block. *Am Heart J* **38**: 376-406, 1949.
32. Tapia FA, Proudfit WL: Secondary R waves in right precordial leads in normal persons and in patients with cardiac disease. *Circulation* **21**: 28-37, 1960.
33. Gentzler RD, Gault JH, Liedtke AJ, et al: Congenital absence of the left circumflex coronary artery in the systolic click syndrome. *Circulation* **52**: 490-496, 1975.
34. Proudfit WL, Grinfeld L: Unreliability of pattern of poor progression of R wave in right precordial leads in females. Unpublished observations.