Case report

Epidermolysis bullosa acquisita

Diagnosis by electron microscopy

Anthony V. Benedetto, D.O.
Wilma F. Bergfeld, M.D.
James S. Taylor, M.D.

Department of Dermatology

D. Gary Osborne

Department of Pathology

A current textbook in dermatology defines epidermolysis bullosa as a heterogeneous group of chronic, hereditary, blistering disorders which range from a mild inconvenience to a disabling illness with significant mortality.[1] Classification of this group of mechanobullous dermatoses is difficult because of the clinical overlap of the various clinical types of epidermolysis bullosa, and the lack of adequate clinical or laboratory criteria for their differentiation. The findings by light microscopy are variable; consequently, the various types of this disease are not easily discernible.

With the aid of the electron microscope, more accurate diagnoses have resulted. Since Pearson's[2, 3] detailed classification of these mechanobullous dermatoses by electron microscopy, there have been relatively few reports which have confirmed the ultrastructural findings of epidermolysis bullosa. Because electron microscopy has not yet become readily available to everyone, published classifications based on these findings differ significantly and remain controversial.

We recently had the opportunity to treat and extensively study a patient who had presenting symptoms of the acquired type of epidermolysis

Downloaded from www.ccjm.org on April 26, 2024. For personal use only. All other uses require permission.

bullosa. Of all the clinical types of epidermolysis bullosa, only epidermolysis bullosa acquisita (EBA) is nonhereditary. Roenigk et al[4] established that the criteria for the diagnosis of EBA are as follows: the disease occurs primarily in adults who have had no history of a blistering disorder nor a family history of a blistering disorder. The skin manifestations of the disease are characteristic and all other types of blistering diseases must be excluded. As is also found by many others, EBA may be found concomitantly with other systemic disorders, e.g., enterocolitis, amyloidosis, multiple myeloma, diabetes mellitus, and lymphoma.

This paper presents our clinical and laboratory findings and compares them with the most recent accounts of EBA. Along with light microscopy, direct immunofluorescence, and the clinical findings, electron microscopy enables the clinician to make an accurate diagnosis of this disease.

Case report

A 56-year-old black woman with a generalized bullous disorder, uncontrolled by topical and systemic corticosteroids was examined at the Cleveland Clinic in May 1976. In December 1974 the patient had first noted paranasal blisters which subsequently disseminated to the mucous membranes, trunk, and extremities. The blisters healed with atrophic scarring and milia formation. The bullae were induced by minor trauma, especially in the acral areas. The patient had a recent onset of dysphagia with hematemesis, peptic ulcer disease, and chemical diabetes precipitated by high-dose corticosteroids. Other medical illnesses included a 20-year history of hypertension recently controlled with methyldopa (Aldomet); and 18-year history of a convulsive disorder controlled by diphenylhydantoin (Dilantin) until 10 years ago when therapy was discontinued because of a blood dyscrasia; a 4-year history of angina pectoris; a myocardial infarction in 1972; and two cerebrovascular infarctions in 1973. The patient is allergic to caine drugs, iodides, and possibly diphenylhydantoin. Family members had histories of atherosclerosis, coronary artery disease, and diabetes mellitus.

On the initial physical examination the patient was obese and alert, but speech was slightly slurred, the right hand grasp was weak, and the mental status was essentially within normal limits. The blood pressure was 180/120 mm Hg and the pulse rate was 80 and regular. There were many scattered, tense bullae containing serosanguinous fluid over the shoulders, mid and lower back, elbows, heels and soles, knees, palms and dorsa of the hands, antecubital fossae and the upper anterior chest wall and forehead. Where the bullae had healed, milia and diffuse atrophic scarring with hyperpigmentation and hypopigmentation were present (*Figs. 1 and 2*). Fingers and toes showed several digits with dystrophic and atrophic nail changes (*Fig. 3*). The patient was edentulous, and the lips, tongue, gingiva, and buccal mucosa were studded with erosions. Nikolsky's sign was present. There was no evidence of lymphadenopathy. Funduscopy demonstrated grade I to II hypertensive retinopathy. There were no carotid bruits, but decreased pulses were present in the lower extremities. The vaginal mucosa showed some erosions.

Fig. 1. EBA: lesions of the hands show bullae and atrophic scarring.

Downloaded from www.ccjm.org on April 26, 2024. For personal use only. All other uses require permission.

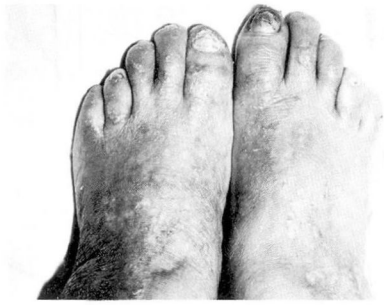

Fig. 2. EBA: lesions of the feet demonstrate areas of hypopigmentation and hyperpigmentation. The second and fourth toes of the right foot and the fifth toes of both feet show atrophic nail changes. Dystrophic nail changes are seen on the other toes.

Laboratory findings

The following laboratory tests initially had normal values: white blood count, electrolytes, blood urea nitrogen (BUN), creatinine, serum glutamic oxaloacetic transaminase (SGOT), serum glutamic pyruvic transaminase (SGPT), serum lactic dehydrogenase (LDH), serum hydroxybutyric dehydrogenase (HBD), creatinine phosphokinase (CPK), alkaline phosphatase, bilirubin, serum amylase, serum lipase, uric acid, cholesterol, inorganic phosphorus, calcium, prothrombin time, partial thromboplastin time, platelets, serum iron, total iron binding capacity, total eosinophil count, glucose-6-phosphate dehydrogenase (G-6-PD), urine porphyrins, and porphyrin precursors (porphobilinogen and delta aminolevulinic acid), erythropoietic protoporphyrins, LE cell preparations, rapid plasma reagin (RPR), indirect immunofluorescence staining for intracellular and basement membrane and smooth muscle and antiparietal cell antibodies, antinuclear factor, serum protein and urine protein electrophoresis, and free thyroxin index.

The following laboratory tests initially had abnormal values: The hemoglobin concentration averaged 10.5 g/dl with normal cell morphology both peripherally and of a bone marrow aspiration. The blood glucose was controlled with diet alone even during a course of high doses of prednisone. Roentgenograms of the chest, urinary tract, gallbladder, small bowel, and facial sinuses were normal. The barium swallow with cine esophagogram revealed narrowing of the upper esophagus at the level of the cricopharyngeal muscle. Endoscopy confirmed the strictures seen on the cine esophagogram. An echogram of the pancreas revealed a prominence of the head of the pancreas, but the CAT scan of the abdomen was within normal limits. The electroencephalogram demonstrated moderate left temporal dysrhythmia in the waking record, but the EMI scan was within normal limits. The direct immunofluorescence of skin biopsy showed linear deposition of IgG, IgM, C_3, and fibrinogen at the dermal epidermal junction on three occasions.

Light microscopy

A biopsy specimen was taken from involved skin. Hematoxylin-eosin staining demonstrated a moderate subepidermal separation with mild necrosis of the overlying keratinocytes. A bulla contained fibrin-like strands, amorphous eosinophilic material, and a few erythrocytes. The base of the bulla retained some dermal papillae which appeared to have mild homogenization of collagen and a mild lymphohistiocytic perivascular infiltrate. In general, the bulla was noninflammatory. Periodic acid Shiff staining did not demonstrate the basal lamina either on the

Fig. 3. EBA: left foot shows atrophic and dystrophic nail changes, including atrophic scarring with milia formation.

Downloaded from www.ccjm.org on April 26, 2024. For personal use only. All other uses require permission.

roof or the floor of the bulla, but rather stained the fibrous strands within the bulla itself. The Verhoeff-Van Gieson stain for elastic tissue demonstrated the absence of elastic tissue within the dermal papillae underlying the bulla. The toluidine blue stain for acid mucopolysaccharides and the crystal violet stain for amyloid deposition were negative.

A skin biopsy specimen taken from previously involved skin demonstrated epidermal atrophy, dermal fibrosis, and milia formation.

Electron microscopy

Specimens were taken for electron microscopy from involved and uninvolved skin. The involved skin showed subepidermal separation with intact basal lamina, evidence of duplicating basal lamina, absence of anchoring fibrils and papillary dermal fibrillar material (*Figs. 4 and 5*). Adjacent to the basal lamina within the dermis, electron dense granular material was observed (*Fig. 6*). The actual bulla was moderately large and displayed bundles of fibrin outlining the roof and the base of the bulla as well as bundles of fibrin scattered throughout the central portion of the bulla (*Fig. 7*).

Specimens taken from uninvolved skin also demonstrated focal, minute, subepidermal separation, intact basal lamina, evidence of duplicating basal lamina, an occasional anchoring fibril, and electron-dense granular material below the basal lamina (*Figs. 8 and 9*). Fibrin-like material was absent from the uninvolved skin.

Discussion

Recently Pearson[3] has stated that the term epidermolysis should not be used to identify this group of dermatoses because it is not appropriate histologically; lysis of the epidermis occurs in only a few of the entities (*Table, Fig. 10*). The designation "mechanobullous dermatoses" most closely depicts the reason why these dermatoses are grouped together.

As can be seen in the *Table*, the

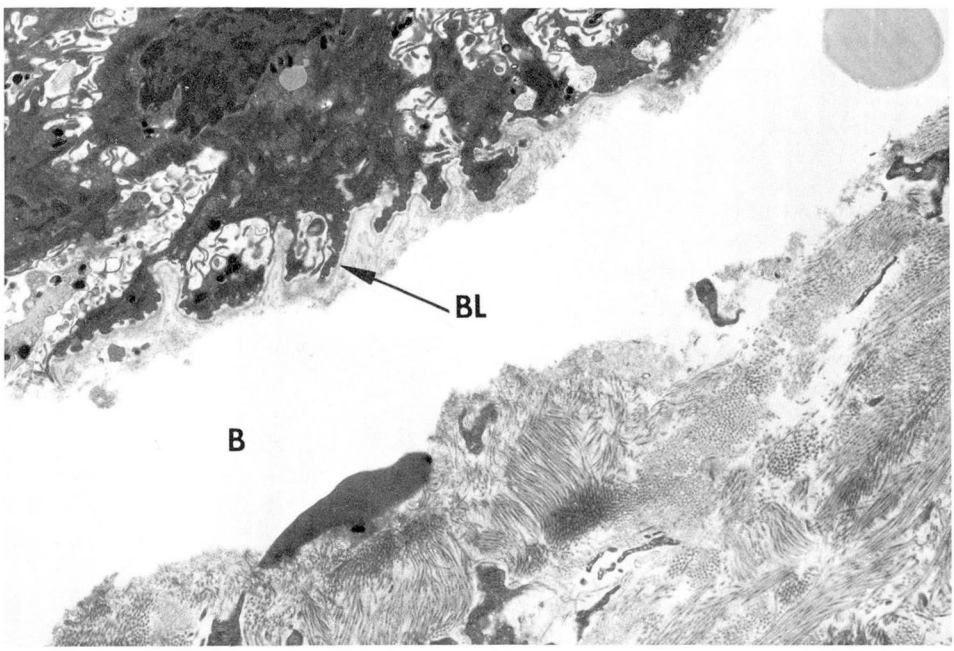

Fig. 4. Electron micrograph of EBA: involved skin; subepidermal bulla (B) with intact basal lamina (BL) (osmium tetroxide, ×9720).

Downloaded from www.ccjm.org on April 26, 2024. For personal use only. All other uses require permission.

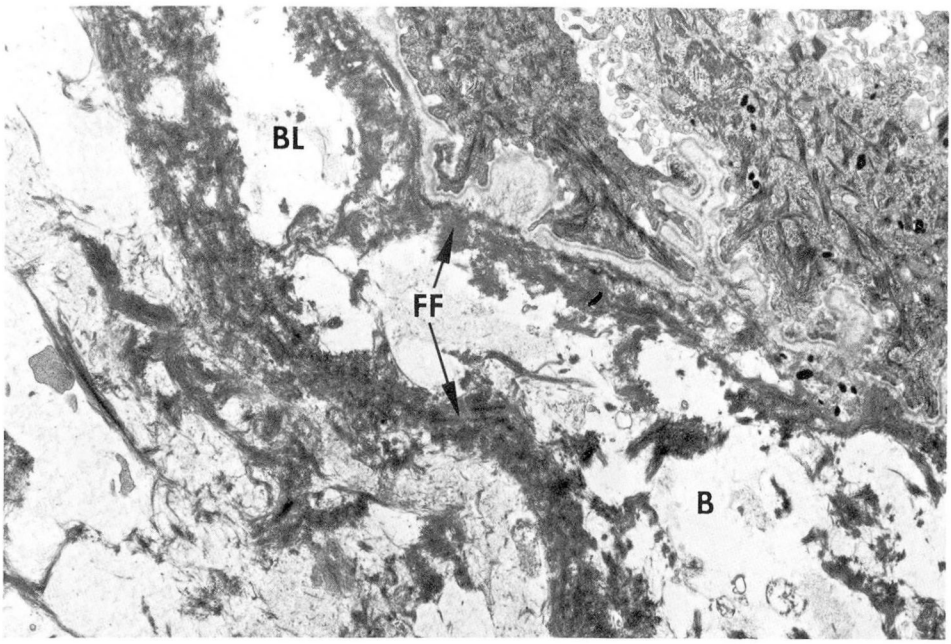

Fig. 5. Electron micrograph of EBA: involved skin; subepidermal separation is outlined by fibrin fibrils (FF); dermal edema is prominent; the basal lamina is intact and demonstrates duplication; anchoring fibrils and papillary dermal fibrillar material are absent (osmium tetroxide, ×9720).

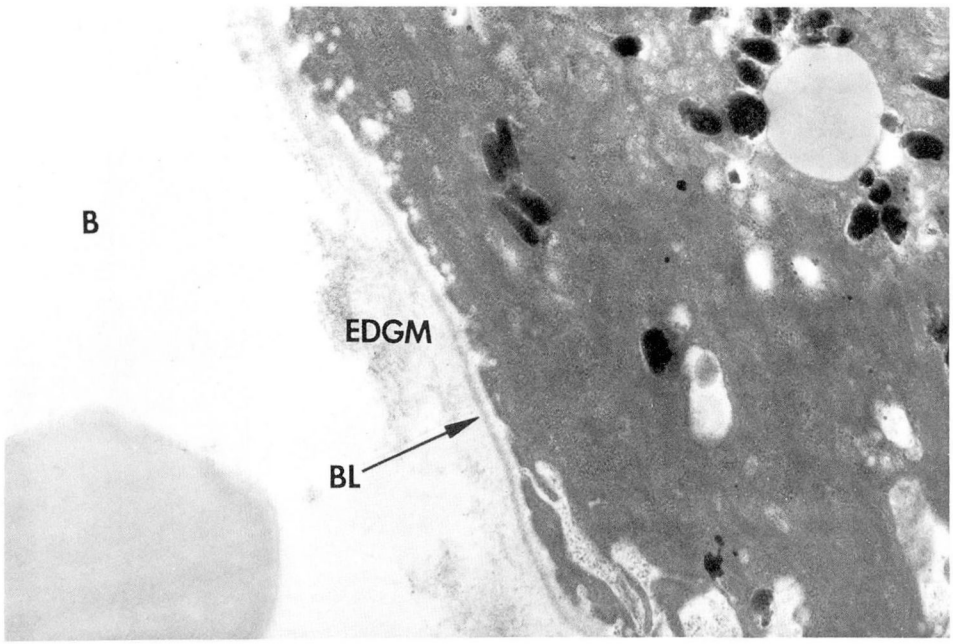

Fig. 6. Electron micrograph of EBA: involved skin; dermal-epidermal junction with an intact basal lamina (BL) with duplication; electron dense granular material (EDGM) is observed adjacent to the (BL) within the subepidermal separation (osmium tetroxide, ×29,700).

Downloaded from www.ccjm.org on April 26, 2024. For personal use only. All other uses require permission.

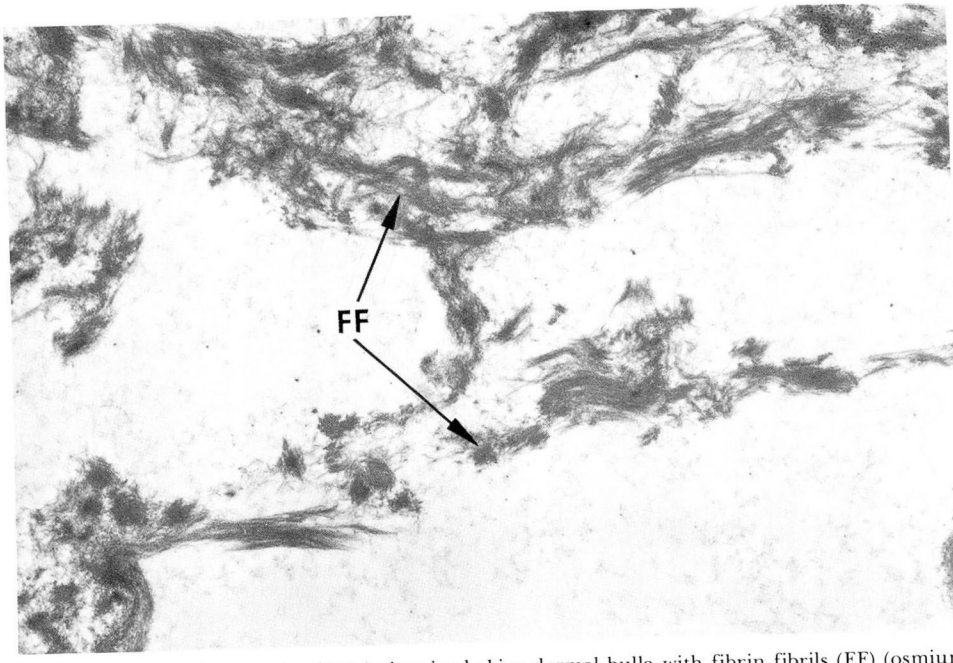

Fig. 7. Electron micrograph of EBA: involved skin; dermal bulla with fibrin fibrils (FF) (osmium tetroxide, ×18,900).

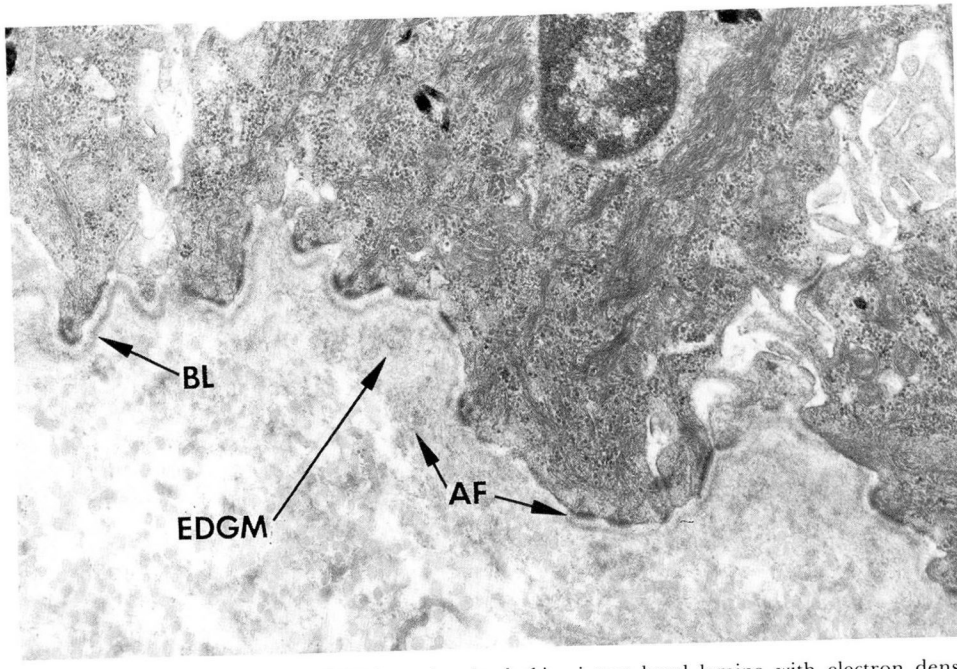

Fig. 8. Electron micrograph of EBA: uninvolved skin; intact basal lamina with electron dense granular material (EDGM) and sparse anchoring fibrils (AF) (osmium tetroxide, ×29,700).

Downloaded from www.ccjm.org on April 26, 2024. For personal use only. All other uses require permission.

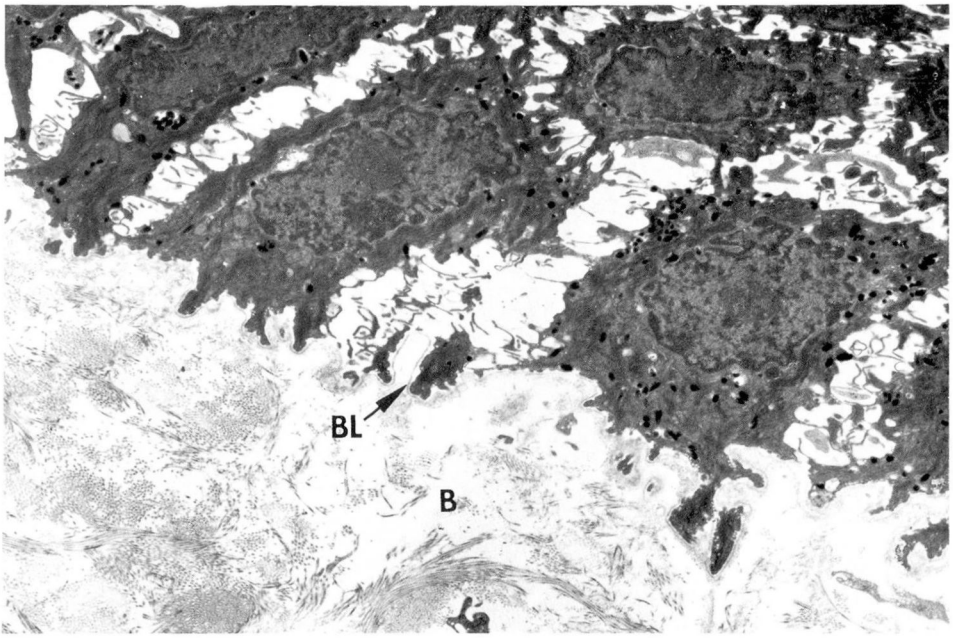

Fig. 9. Electron micrograph of EBA: uninvolved skin; focal, minute, subepidermal separation (B) with an intact basal lamina, sparse to absent anchoring fibrils, and dermal edema.

Table. Major forms of the mechanobullous disease (epidermolysis bullosa)

Older designation	Site of bulla formation*	Suggested name
Nonscarring		
Epidermolysis bullosa simplex (EBS)	Intraepidermal degeneration and cytolysis of the basal keratinocytes	Epidermolysis bullosa simplex (EBS)
Weber-Cockayne disease	Suprabasalar cytolysis	Recurrent bullous eruption of the hands and feet (RBEHF)
Epidermolysis bullosa hereditaria letalis (Herlitz disease)	Between the basal lamina and the plasma membrane of the epidermal basal cells	Junctional bullous epidermatosis (JBE)
Scarring		
Epidermolysis bullosa dystrophica (EBD)		Dermolytic bullous dermatoses (DBD)
Dominant type (EBD-D)	In the upper dermis below the basal lamina	Dominant type (DBD-D)
Recessive type (EBD-R)	In the upper dermis below the basal lamina	Recessive type (DBD-R)
"Acquired" type [E. bullosa acquisita (EBA)]	In the upper dermis below the basal lamina	"Acquired" type (DBD-A)

* See *Fig. 10.*

mechanobullous diseases can be separated into scarring and nonscarring dermatoses. Of the nonscarring bullous dermatoses, some are epidermolytic and others are not. Of the scarring bullous dermatoses, the more common ones are only dermolytic.

According to Roenigk et al,[4] our

Downloaded from www.ccjm.org on April 26, 2024. For personal use only. All other uses require permission.

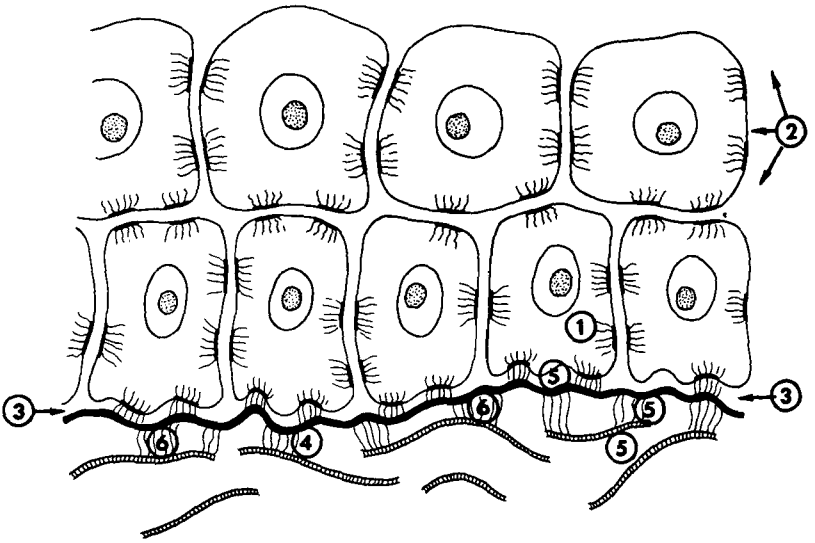

Fig. 10. Sites of bullae formation in the mechanobullous dermatoses; (1) epidermolysis bullosa simplex; (2) recurrent bullous eruption of the hands and feet (Weber-Cockayne disease); (3) junctional bullous epidermatosis (Herlitz disease); (4) dominant type of dermolytic bullous dermatosis (DBD-D); (5) recessive type of dermolytic bullous dermatoses (DBD-R); (6) acquired type of dermolytic bullous dermatosis (DBD-A) (*Table*).

case adequately meets the criteria for the diagnosis of EBA or the acquired type of the dermolytic bullous dermatoses (DBD-A). The lesions are characteristic for DBD-A, namely bullae healing with atrophic scarring and milia secondary to minor trauma and nail dystrophy. The onset occurred during the patient's adult life. Neither she nor her family had a history of skin diseases. All other possible bullous dermatoses are excluded in this patient by the above clinical and laboratory results. Our findings concur with the findings of Woerdeman,[5] Gibbs and Minus,[6] and Metz et al,[7,8] who earlier described essentially that which is demonstrated here with the immunofluorescence studies and both light and electron microscopy.

The skin biopsy for light microscopy represents a subepidermal bullous disorder compatible with EBA, epidermolysis bullosa dystrophica, bullous pemphigoid, erythema multiforme, or porphyria. The demonstration on direct immunofluorescence of IgG, IgM, C_3, and fibrinogen at the basement membrane zone and negative indirect immunofluorescence supports a diagnosis of EBA, lupus erythematosus, or porphyria cutanea tarda. The electron microscopic findings of (1) a dermal-epidermal separation within the papillary dermis with an intact basal lamina, (2) the presence of electron dense granular material adjacent to the basal lamina, (3) the loss of anchoring fibrils, and (4) the absence of papillary dermal fibrillar material certainly are consistent with the previously reported findings for EBA.[5–12]

The demonstration with direct immunofluorescent microscopy of immunoglobulins at the basement

Downloaded from www.ccjm.org on April 26, 2024. For personal use only. All other uses require permission.

membrane zone and the demonstration by electron microscopy of electron dense granular material within the same area is suggestive that this granular material may represent immune complexes. This hypothesis merits further documentation.[8]

The presence of dermal fibrin and fibrin-like material which appears in the dermis and within the dermal bulla is unexplained at this time.

The clinical and laboratory presentations including the findings by light, direct immunofluorescent, and electron microscopy supports the diagnosis of EBA in this patient. Only with the use of electron microscopy could we finally exclude bullous pemphigoid and accurately diagnose EBA.

References

1. Carter DM, O'Keefe EJ: Hereditary cutaneous disorders, *in* Dermatology, Moschella SL, et al, eds. Philadelphia, WB Saunders Co, 1975, pp 1027–1032.
2. Pearson RW: Studies on the pathogenesis of epidermolysis bullosa. J Invest Dermatol **39:** 551–575, 1962.
3. Pearson RW: The mechanobullous diseases, *in* Dermatology in General Medicine, Fitzpatrick TB, et al, eds. New York, McGraw-Hill Book Co Inc, 1971, pp 621–643.
4. Roenigk HH Jr, Ryan JG, Bergfeld WF: Epidermolysis bullosa acquisita; report of three cases and review of all published cases. Arch Dermatol **103:** 1–10, 1971.
5. Woerdeman MJ: Epidermolysis bullosa dystrophica acquisita. Dermatologica **149:** 184–186, 1974.
6. Gibbs RB, Minus HR: Epidermolysis bullosa acquisita with electron microscopical studies. Arch Dermatol **111:** 215–220, 1975.
7. Metz G, Metz J, Frank H: Epidermolysis-bullosa-acquisita in Crohn's disease. Hautarzt **26:** 321–326, 1975.
8. Metz J, Frank H, Metz G: Pathomorphogenesis of blistering in epidermolysis bullosa acquisita and epidermolysis bullosa dystrophica. Arch Dermatol Forsch **254:** 103–112, 1975.
9. Kushniruk W: The immunopathology of epidermolysis bullosa acquisita. Canad Med Assoc J **108:** 1143–1146, 1973.
10. Hashimoto I, Anton-Lamprecht I, Gedde-Dahl T Jr, et al: Ultrastructural studies in epidermolysis bullosa hereditaria; I. Dominant dystrophic type of Pasini. Arch Dermatol Forsch **252:** 167–178, 1975.
11. Briggaman R, Wheeler C: Epidermolysis bullosa dystrophica—recessive; a possible role of anchoring fibrils in the pathogenesis. J Invest Dermatol **65:** 203–211, 1975.
12. Briggaman RA, Wheeler CE Jr: The epidermal-dermal junction. J Invest Dermatol **65:** 71–84, 1975.

Downloaded from www.ccjm.org on April 26, 2024. For personal use only. All other uses require permission.