

Visual disturbances associated with primary empty sella syndrome

Evangelos Xistris, M.D.
Patrick J. Sweeney, M.D.

Department of Neurology

Froncie A. Gutman, M.D.

Department of Ophthalmology

The term empty sella was introduced by Busch¹ in 1951 to describe autopsy findings in which the diaphragma sella was incompetent or formed only a peripheral rim of tissue with the pituitary gland compressed at the bottom of the sella turcica. The term empty sella syndrome was introduced by Colby and Kearns² in 1962 to refer to symptoms of progressive visual impairment in a patient after irradiation for an intrasellar tumor despite lack of tumor recurrence. At operation, the optic nerves and chiasm were seen to be drawn into the sella by adhesions. Three similar cases were described by Lee and Adams³ who also applied the term empty sella syndrome to them. Weiss and Raskind⁴ distinguished primary from secondary empty sella.

Primary empty sella refers to a sella that (a) may or may not be enlarged, (b) admits air on pneumoencephalography or appears empty at surgery, and (c) there has been no operation or irradiation previously for pituitary tumor.

Visual disturbances such as decreased acuity and blurred vision have been described in primary empty sella.⁵ Visual field defects, although considered rare, have also been described.⁵⁻⁷ However, severe visual disturbances have not been reported in primary empty sella. The fol-

lowing is a case report of a patient with primary empty sella, severe visual deficits, and bilateral optic atrophy.

Case report

A 53-year-old black man was admitted to the Cleveland Clinic Hospital with a 3½-year history of blurred vision and progressively decreasing visual acuity in both eyes. At a previous examination bilateral optic atrophy and bitemporal hemianopsia were observed. An enlarged sella was shown on skull roentgenogram. He denied having headaches, diplopia, or any symptoms that suggested endocrine abnormalities. In 1973 evaluation at another hospital revealed normal visual fields. No papilledema was discerned at that time, but skull roentgenograms showed an enlarged sella. Brain scan and electroencephalogram were also normal at that time. Angiography and possible surgery were suggested, but the patient refused, and he signed out of the hospital against medical advice. Subsequent testing as an outpatient revealed normal urinary 17-ketosteroids, thyroid-stimulating hormone levels, follicle-stimulating hormone, and testosterone levels. He had a history of hypertension and syphilis in 1940; the latter was treated by an unknown mode of therapy.

On admission blood pressure was normal and heart rate was 60. Pertinent neurologic findings were an eccentric point of fixation to the right of a target object; visual acuity 20/800 O.D. and finger counting at 3 feet O.S.; bitemporal hemianopsia by confrontation; and bilateral optic atrophy, right greater than left. The pupils were 5 mm bilaterally and reactive directly and consensually to light. The swinging light test was negative.

Pertinent laboratory data revealed normal serum testosterone, luteinizing hormone, and follicle-stimulating hormone levels. Effective thyroxine ratio and 3-hour glucose tolerance test were normal. One of two serum cortisol levels was low.

Serologic testing revealed a weakly positive VDRL and a positive FTA-ABS.

Lumbar puncture revealed an opening pressure of 300 mm and a closing pressure of 250 mm. Total protein was 50 mg/dl; there were no red blood cells and one white blood cell per cubic millimeter. VDRL in the cerebrospinal fluid was negative.

Skull roentgenograms showed an enlarged sella with thinning of the posterior clinoids and minimal undercutting anteriorly (*Figure*). Views of the optic foramina were normal. Bilateral carotid arteriograms showed inferior displacement of the parasellar portion of both carotid arteries with tortuosity of the carotid siphons. Pneumoencephalography showed air in the suprasellar cistern which dipped into the sella. The optic and infundibular recesses of the third ventricle extended into the superior aspect of the sella. EMI scan and electroencephalogram were normal.

The patient was discharged and has been followed as an outpatient without further deterioration of visual acuity.

Discussion

Visual field defects and severe visual deficits are rare complications of primary empty sella. This case is unusual in that the patient had poor visual acuity, bilateral optic atrophy, and bitemporal hemianopsia. The visual defects may be based on two pathogenetic mechanisms: (1) compression of optic nerves and chiasm by overlying structures, and (2) sagging of the optic nerves and chiasm into the enlarged and empty sella with subsequent vascular compromise.

Kaufman⁸ has shown that a deficient diaphragma sella allows normal cerebrospinal fluid pulsations or chronically increased intracranial pressure to be transmitted to the sella. This compresses the pituitary

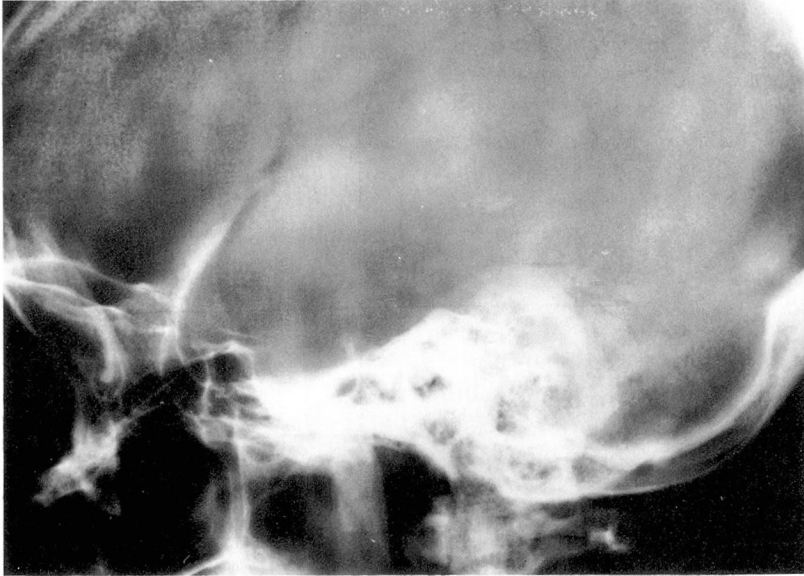


Figure. Lateral skull roentgenogram of patient.

gland against the bony walls of the sella and also produces remodeling and enlargement of the sella. Mortara and Norrell⁶ felt that such compression of the pituitary gland places traction on the pituitary stalk resulting in either a thinning of the floor of the third ventricle or a pulling downward of the third ventricle into the sella. This, in turn, could cause direct compression of the optic nerves or chiasm or it could push the anterior cerebral arteries down onto these structures thereby causing compression indirectly.

Sagging of the optic nerves and chiasm with consequent vascular compromise and subsequent infarction constitute a second means by which visual disturbances in empty sella might occur. This is usually seen in secondary empty sella where scarring and arachnoiditis secondary to either previous surgery or irradiation are thought to pull the chiasm and optic nerves into the sella. However,

such an occurrence is possible with primary empty sella.

Foley and Posner⁹ have observed that patients with both pseudotumor cerebri and primary empty sella are more likely to have visual defects than are patients with either syndrome alone. These patients have chronically increased intracranial pressure and a deficient diaphragma sella. Such a combination of factors was felt to predispose to sagging of the optic nerves and chiasm into the sella. Our patient had increased intracranial pressure manifested by a high opening pressure on lumbar puncture, but did not have any other signs and symptoms of pseudotumor cerebri.

The pneumoencephalographic findings in this patient, although not conclusive, suggest downward migration of the third ventricle into the sella. The mechanism by which this may produce visual field defects has been discussed previously. In addi-

tion, Banerjee and Meagher¹⁰ reported a case of incomplete Foster-Kennedy syndrome and empty sella secondary to aqueductal stenosis. The optic atrophy in this case was attributed to compression and stretching of the optic nerve at its junction with the chiasm produced by the dilated third ventricle.

Of the two mechanisms discussed, the most likely cause of the visual deficits in this patient appears to be sagging of the optic nerves and chiasm into the sella turcica with subsequent vascular compromise of these structures. Although compression of the optic nerves and chiasm directly or indirectly by a downward herniated third ventricle is possible, this could not be demonstrated conclusively by pneumoencephalography. This patient is known to have empty sella syndrome and findings suggestive of increased intracranial pressure. The combination of these two factors has been shown to predispose to sagging of the optic nerves and chiasm into the sella turcica.

Lastly, syphilitic optic neuritis or retrobulbar neuritis can cause optic atrophy and a variety of field defects. Syphilitic basilar meningitis might affect the optic nerve and chiasm and produce optic atrophy and various hemianopsias as well. The patient's cerebrospinal fluid serology was negative, which along with reactive pu-

pils tends to rule out syphilis of the central nervous system as a cause of the observed visual deficits.

Summary

A case of primary empty sella with severe visual deficit is reported. The mechanisms by which these deficits might occur are briefly discussed.

References

1. Busch W: Die Morphologie der Sella turcica und ihre Beziehungen zur Hypophyse. *Arch Pathol Anat* **320**: 437-458, 1951.
2. Colby MY, Kearns TP: Radiation therapy of pituitary adenomas with associated visual impairment. *Mayo Clin Proc* **37**:15-24, 1962.
3. Lee WM, Adams JE: The empty sella syndrome. *J Neurosurg* **28**:351-356, 1968.
4. Weiss SR, Raskind R: Non-neoplastic intrasellar cysts. *Int Surg* **51**: 282-288, 1969.
5. Berke JP, Buxton LF, Kokmen E: The 'empty' sella. *Neurology* **25**: 1137-1143, 1975.
6. Mortara R, Norrell H: Consequences of a deficient sellar diaphragm. *J Neurosurg* **32**: 565-573, 1970.
7. Neelon FA, Goree JA, Lebovitz HE: The primary empty sella; clinical and radiographic characteristics and endocrine function. *Medicine* **52**: 73-92, 1973.
8. Kaufman B: The "empty" sella turcica; a manifestation of the intrasellar subarachnoid space. *Radiology* **90**: 931-941, 1968.
9. Foley KM, Posner B: Does pseudotumor cerebri cause the empty sella syndrome? *Neurology* **25**: 565-569, 1975.
10. Banerjee T, Meagher JN: Foster-Kennedy syndrome, aqueductal stenosis and empty sella. *Am Surg* **40**: 552-554, 1974.