

Macroglobulinemia and malabsorption

Raymond R. Tubbs, D.O.

Division of Laboratory Medicine

John P. McLaughlin, D.O.
Eugene I. Winkelman, M.D.

Department of Gastroenterology

Sharad D. Deodhar, M.D.,
Ph.D.

Department of Immunopathology

James S. Hewlett, M.D.

*Department of Hematology and Medical
Oncology*

Intestinal involvement in IgM monoclonal gammopathy is unusual. In Waldenstrom's original series,¹ one patient had diarrhea. Malabsorption or steatorrhea or both have been reported in other patients with macroglobulinemia.²⁻⁷ In one patient, monoclonal macroglobulin has been identified in dilated lymphatics and in the lamina propria extracellularly with the use of the immunofluorescent technique.⁷ Clinical improvement has been reported following administration of corticosteroids. In this case considerable resolution of histologic abnormalities of the small bowel was documented following treatment with cyclophosphamide and prednisone.

Case report

A 58-year-old married woman was well until August 1969 when fatigue and weakness developed. Her local physician administered parenteral medication unknown to her for anemia. She experienced mild improvement, but within a few weeks fatigue and weakness recurred. In November 1969, following a flu-like illness characterized by rhinorrhea, sore throat, diarrhea, and fever, she became anorexic. This was accompanied by a sensation of epigastric fullness and increased abdominal girth. She was hospitalized at another institution and anemia was diagnosed. The results of an upper gastrointestinal

examination, barium enema, intravenous pyelogram, and liver scan were reported to be normal. An oral cholecystogram did not visualize. A bone marrow examination was reported as normal. She lost 15 kg in weight during the first 3 weeks of hospitalization. A low-fat diet, prednisone, 30 mg daily, and thyroid USP, 3 gr/day, were prescribed. Her appetite improved and no further weight loss occurred. The hemoglobin level was in the normal range and she was discharged from the hospital. In the 3 weeks prior to admission to the Cleveland Clinic her appetite continued to improve and she had no further loss of weight.

At physical examination on admission her height was 157.5 cm, weight 51 kg, temperature (oral) 37.5 C, pulse 120 beats per minute and regular, blood pressure 98/70 mm Hg. No cutaneous abnormalities were noted. The head, eyes, ears, nose, mouth, and throat were normal. A mild diffuse enlargement of the thyroid gland was palpable. No lymphadenopathy was noted. Auscultation of the chest was unremarkable. The liver was palpable 6 cm inferior to the right costal margin, and the spleen descended 6 cm below the left costal margin.

Admission laboratory studies disclosed the following values: hemoglobin, 13.5 g/dl; white blood cell count, 5600/mm³ (58 segmented neutrophils, 34 lymphocytes, 8 monocytes); platelet count, 200,000/mm³; reticulocyte count, 2.6%; urinalysis normal; cholesterol, 200 mg/dl; calcium, 9.4 mg/dl; phosphorus, 3.8 mg/dl; total bilirubin, 0.4 mg/dl; uric acid, 5.0 mg/dl; BUN, 20 mg/dl; glucose, 70 mg/dl.

Analysis of a 72-hour stool specimen for fecal fat was within normal limits. Serum carotene was 40 µg/dl (normal 50–250). D-xylose excretion was decreased (2.6 g/5 hr). The prothrombin time was 15 seconds with a control of 12 seconds.

A chest film was normal. The small bowel series demonstrated extensive flocculation, with edematous mucosal folds (Fig. 1). No segmentation was apparent.

On July 28, 1970, the patient underwent exploratory laparotomy because malignancy was suspected. Diffuse erythema of the jejunum with dilated lacteals and fusiform white lesions of the serosa were noted. Mesenteric lymph nodes were enlarged and white. Representative biopsies of jejunum and mesenteric lymph nodes were performed, and a diagnosis of lymphangiectasia of the intestinal lymphatics and mesenteric lymph nodes was established.

A bone marrow aspirate from the left iliac crest on the third postoperative day was normal. Her subsequent course was unremarkable except for an *Escherichia coli* urinary tract infection. She was discharged February 7, 1970, on a regimen of diazepam (Valium), 5 mg as needed; ampicillin, 500 mg four times daily orally; thyroid USP, 1 gr daily; and digitalis leaf, 100 mg daily. Serum protein studies were initiated before discharge.

The patient was admitted to the hospital a second time on March 19, 1970. She had felt well until 3 weeks prior to admission when she began having several light-colored, loose, watery stools daily, persistent anorexia, a weight loss of 2 kg,

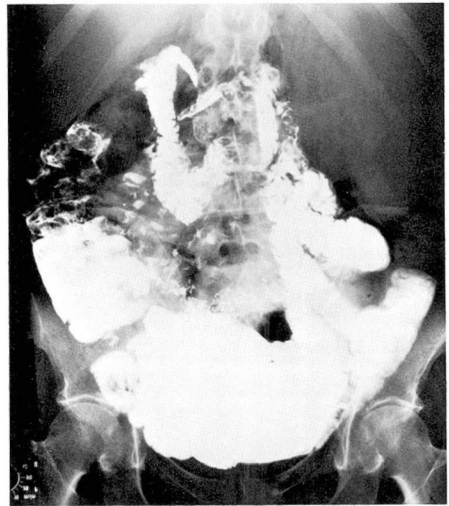


Fig. 1. Small bowel series. No segmentation is apparent. Note the flocculation and edematous mucosal folds.

and an increase in abdominal girth. Physical examination disclosed splenomegaly and a distended abdomen with tympanic high-pitched bowel sounds. Hemoglobin was 8.4 g/dl, white blood cell count 4900 with a normal differential count. Paper electrophoresis of serum performed prior to admission showed an extensive spike in the gamma mobility range, with 4.3 g/dl gamma globulin (total protein 8.7 g/dl) (Fig. 2). Immunoelectrophoresis performed prior to admission demonstrated monoclonal IgM (kappa) immunoglobulin in the serum (Fig. 3). Serum viscosity was 3.1 units, cryoglobulins were positive, and quantitative immunoglobulins were as follows: IgG, 580 mg/dl; IgA, 56 mg/dl; and IgM, approximately 8000 mg/dl. The prothrombin time was 24 seconds with a control 13 seconds. The serum carotene was 20 µg/dl. Stool for fat was negative; Cr⁵¹-labeled albumin studies were compatible with protein-losing enteropathy (12% on two determinations). Significant blast transformation to phytohemagglutinin (79% on day 3, 59% on day 5) was noted. A bone marrow aspirate showed increased cellularity with 46% mature lymphocytes and 14% plasma cells with a few plasmacytoid lymphocytes (200 cells counted). Cyclophosphamide, 50 mg twice daily orally, and prednisone,




Fig. 2. Serum paper electrophoresis before and after chemotherapy. The M-component had disappeared from the serum approximately 3 months after initiation of therapy. Repeat small bowel series and malabsorption studies were normal.

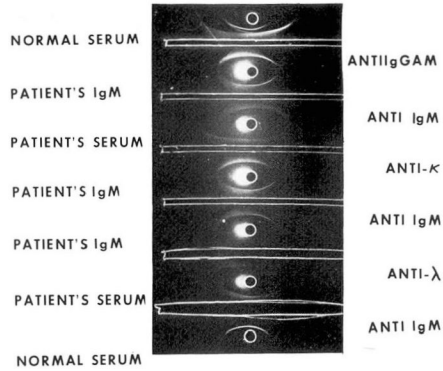


Fig. 3. Serum immunoelectrophoresis demonstrating the presence of an IgM (κ) M-component in the serum.

60 mg every other day orally, were administered and the patient was discharged on April 4, 1970, without dietary restrictions.

Three days later diarrhea and vomiting developed and the patient was admitted to another hospital with severe dehydration and leukopenia. Cyclophosphamide was discontinued for 1 week, then reinstated in a dosage of 100 mg weekly.

The patient was examined in the outpatient department at the Cleveland Clinic June 22, 1970. During the previous 2 months her gastrointestinal complaints had disappeared. Physical examination disclosed persistent hepatosplenomegaly, minimal bilateral moist basilar rales, and trace pedal edema. Auscultation of the heart was normal. Stool for fat revealed no fat on two determinations. The hemoglobin level was 11 g/dl; white blood cell count, 8800 with a normal differential count; prothrombin time was 14 seconds with a control 13 seconds. Serum carotene was 40 µg/dl. Serum paper electrophoresis was normal (Fig. 2). Quantitative immunoglobulins were as follows: IgG, 540 mg/dl; IgA, 47 mg/dl; and IgM, approximately 560 mg/dl. The test for cryoglobulins was negative. Ultracentrifugation of the patient's serum disclosed 19s macroglobulin 2%, 7s globulins 16%, 4s albumin and low molecular weight globulins 82%. A repeat small bowel series was normal. The same medications

were continued, but the dosage of prednisone was reduced to 15 mg/day orally.

Four days later, after returning to Michigan, she was hospitalized with pneumonia. Following treatment with cephalothin and resolution of the pneumonia, she was discharged July 14, 1970, only to be readmitted to the same hospital 4 days later with hyperpyrexia (38 C), arthralgias, visual disturbances, anemia (hemoglobin 6 g/dl), and leukopenia ($1157/\text{mm}^3$ with an absolute neutropenia). Blood cultures were positive for *Staphylococcus aureus*. Despite reverse isolation, several transfusions, and antibiotic therapy with multiple antimicrobial agents, the patient died July 28, 1970.

A necropsy performed at Carson City Hospital, Carson City, Michigan, revealed a consolidating left lower lobe pneumonia, concentric left ventricular hypertrophy with focal myocardial fibrosis (weight 300 g), atherosclerotic coronary artery disease, and a mild white infiltrate in the jejunal perilacteal areas and the small bowel mesentery. Representative tissue was submitted to the Cleveland Clinic for review. Histopathologic evaluation disclosed mild lymphectasia of mucosal and submucosal lymphatics. The degree of lymphectasia, when compared with the original biopsy specimen, was much less severe.

Materials and methods

Protein electrophoresis was done on cellulose acetate using the Beckman microzone system employing B-2 buffer (pH 8.6), Beckman fixative-dye dilution (Ponseau-S, trichloroacetic acid, sulfosalicylic acid), and was read in the Beckman densitometer at 520 nm. Immunoelectrophoresis was done in a Buchler electrophoretic chamber with a Heathkit power supply applying constant exit voltage of 90 volts to serum buffered with barbital to pH 8.2 (ionic strength 0.04), and Behring antisera exposed to the electrophoresed sera. Follow-

ing overnight (16–18 hour) incubation at room temperature in a moist chamber, zone diameters were measured and compared with curves derived from reference sera.

Surgical pathology and necropsy sections were fixed in either formalin or Zenker's solution, processed in the usual manner, and imbedded in paraffin. Sections were stained with hematoxylin and eosin, and with periodic acid Schiff pre- and post-diastase digestion. Segments from the jejunum were fixed in Carnoy's solution, frozen, and stained with oil red O stain reagent.

Immunomicroscopy was performed utilizing the direct immunoperoxidase technique⁸ and Bioware^R monospecific antibodies conjugated with horseradish peroxidase. Following deparaffinization and rehydration of tissue sections in phosphate buffered saline (0.02M, pH 7.5) and Tris buffer 9.4 pH (Tris base 5.47 g, NaCl 6.0 g, Tris-HCl 0.76 g in 1000 ml distilled water), monospecific antisera (anti-human IgG, IgA, IgM, IgD, IgE, κ , λ) conjugated with peroxidase were incubated with the tissue sections for 1 hour. The sections were rinsed in PBS, and the antigen-antibody complexes fixed in denatured alcohol 10 minutes. The tissue was then washed in PBS-Tween 80 (Sigma) (PBS 150 ml with 0.05 ml Tween 80) 10 minutes and then overlaid with the substrate solution (90 mg 3,3' diaminobenzidine tetrachloride and 0.02 ml 30% H_2O_2 in 100 ml PBS). The sections were washed in PBS, counterstained with 1% methyl green, dehydrated in alcohol and xylene, and mounted with permount.

Results

Histopathology. The material studied included a gallbladder meas-

uring 10×3 cm having a smooth and glistening serosa and averaging 0.3 cm in thickness. The mucosa was bile stained. Multiple mixed type calculi were present within the gallbladder. A wedge biopsy specimen of liver measuring $0.5 \times 0.4 \times 0.2$ cm was also submitted. Multiple segments of mesentery, lymph nodes, and jejunum were submitted, the largest measuring $2.5 \times 1 \times 0.5$ cm.

The gallbladder contained a moderate mucosal and submucosal chronic inflammatory infiltrate. The wedge biopsy specimen of liver was histologically normal. The specimens from the jejunum had expanded villi with prominent dilatation of mucosal lymphatics by amorphous, slightly acidophilic material. This material was periodic acid-Schiff negative and

oil red O positive. It was located primarily within lymphatics, but was also identified extracellularly in the lamina propria. An admixture of lymphocytes and plasma cells was present in the lamina propria and submucosa (*Fig. 4*).

Sections of mesentery and mesenteric lymph nodes demonstrated a similar, marked lymphectasia. An admixture of lymphoid cells with plasmacytoid lymphocytes partially effaced the lymph node architecture (*Fig. 5*).

Histopathologic study of necropsy tissues revealed a severe organizing bronchopneumonia, focal myocardial fibrosis, and minimal persistent lymphectasia in the jejunum and mesenteric nodes (*Fig. 6*). A mixed, diffuse infiltrate composed of mature

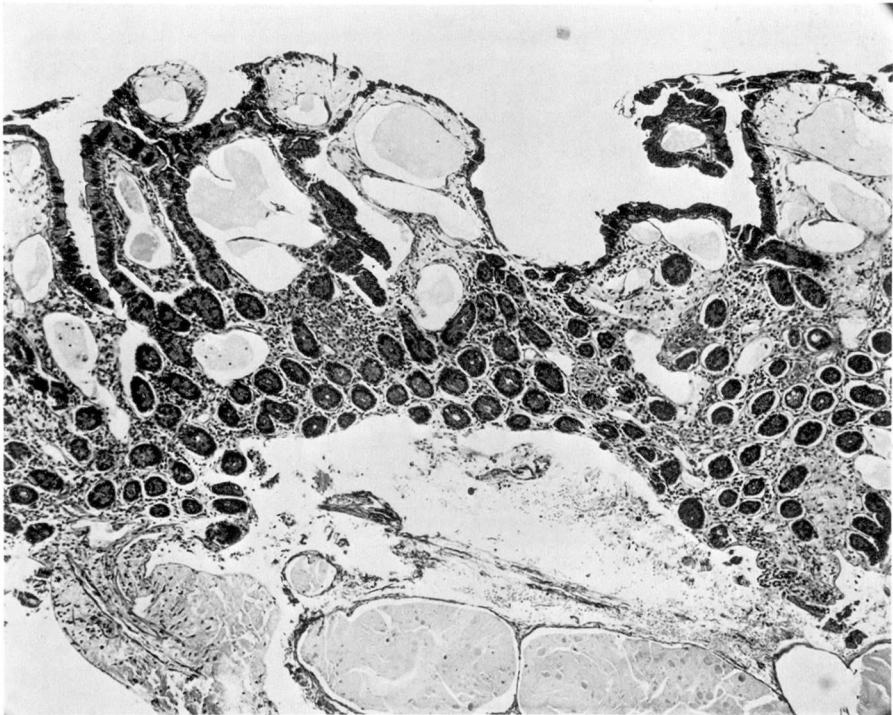


Fig. 4. Initial small bowel biopsy. Note expanded villi with prominent dilatation of mucosal lymphatics by amorphous material. A small amount of the material is present extracellularly (hematoxylin and eosin stain, $\times 64$).

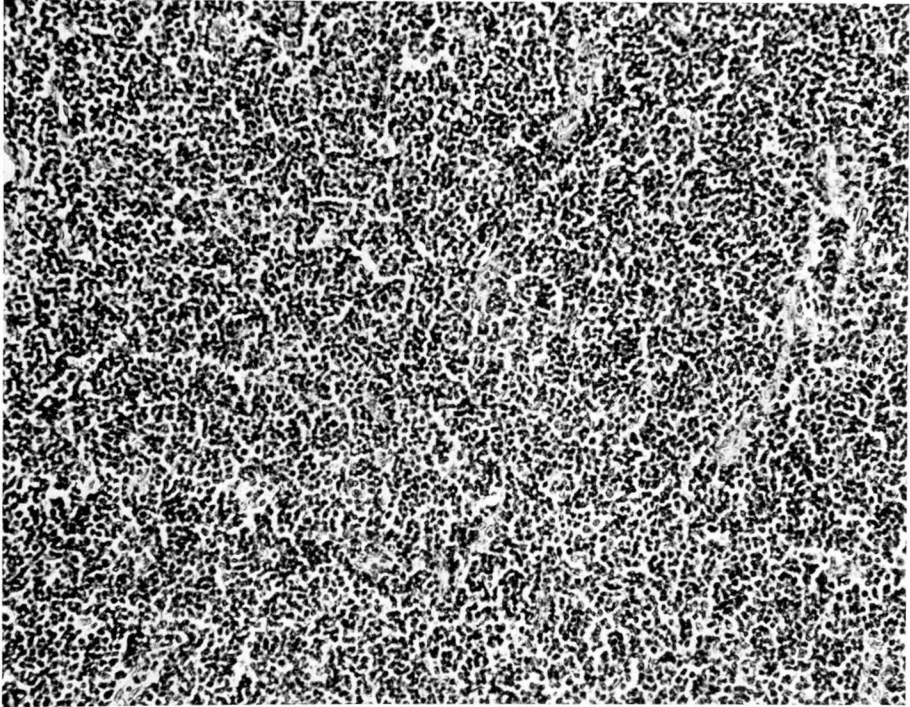


Fig. 5. Severe effacement of mesenteric lymph node by lymphoplasmacytic infiltrate (hematoxylin and eosin stain, $\times 160$).

lymphocytes, plasma cells, plasmacytoid lymphocytes, and occasional lymphoid cells with Dutcher bodies, was present in lung, bone marrow, spleen, and lymph nodes.

Immunomicroscopy. Deposition of all immunoglobulin heavy chains and both light chains within the inspissated material in dilated submucosal lymphatics and intestinal lacteals was demonstrated (*Fig. 7*). Occasional mononuclear cells within the interstitium demonstrated cytoplasmic staining only with anti-IgM-HPO conjugate. There was no extracellular deposition of IgM within the small bowel other than within the dilated lymphatic channels.

Discussion

Gastrointestinal manifestations of IgM monoclonal gammopathy have

been described in only a few patients.^{1-7, 9-14} Of those reported, six have had clinical manifestations of malabsorption and extracellular acidophilic deposits within small bowel mucosa.^{2, 7} In our case the acidophilic material was only slightly PAS positive, but abundant neutral fat was present within the dilated lacteals. Previous studies have demonstrated greater PAS positivity of the extracellular material.^{2-4, 6} Pruzanski et al⁷ have suggested that the acidophilic material may represent monoclonal IgM-phospholipid complexes.

The mechanism by which malabsorption occurs in this entity is uncertain. Pruzanski et al⁷ reported that the following factors may be involved: 1) impaired circulation with stasis of lymph, 2) blockage of absorption by extracellular deposits of

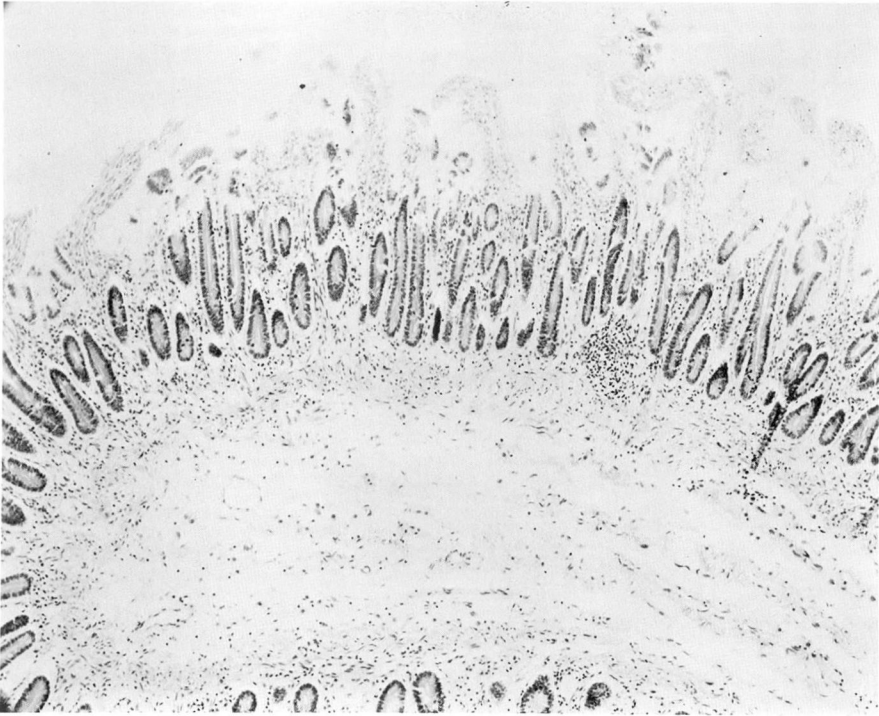


Fig. 6. Compare this necropsy section of jejunum with *Figure 4*. Note diminution of lymphectasia (hematoxylin and eosin stain, $\times 64$).

immunoglobulin, 3) decrease in absorptive surface due to alteration of villi, and 4) deficient local immunity. In our case clinical resolution of malabsorption occurred concomitantly with the disappearance of the M-component from the serum, suggesting that mucosal deposition of the monoclonal immunoglobulin is the primary pathogenetic mechanism. However, immunomicroscopy demonstrated a polyclonal extracellular deposition of immunoglobulins. Furthermore, clinical improvement of malabsorption was also associated with histologic improvement in lymphectasia. These observations suggest that obstruction and stasis of lymphatic circulation due to effacement of mesenteric lymph nodes by the malignant infiltrate are of pri-

mary importance in the pathogenesis of the lesion.

Summary

Intestinal involvement in Waldenström's macroglobulinemia is rare. It is characterized by massive lymphectasia of small bowel, mesentery, and lymph node lymphatic vessels, and the deposition of amorphous material extracellularly in the lamina propria. The associated malabsorption syndrome clinically disappears or improves with chemotherapy. A case is reported in which considerable resolution of histologic abnormalities of the small bowel occurred after treatment with cyclophosphamide and prednisone and concomitant disappearance of the serum M-component. Deposition of the monoclonal

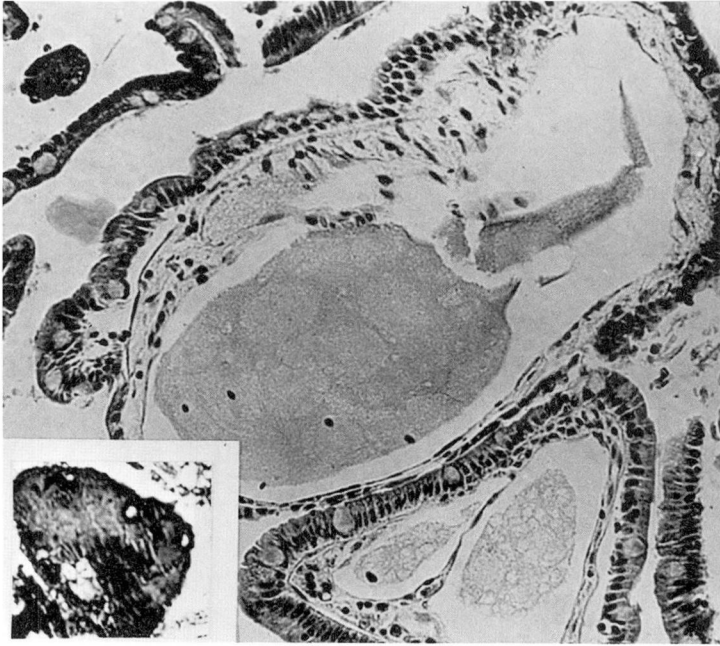

Fig. 7. Photomicrograph demonstrating extracellular deposition of mu heavy chain within dilated lymphatics. A direct immunoperoxidase technique was employed using mu-specific antisera conjugated with peroxidase, deaminobenzidine and H_2O_2 as the substrate, and 1% methyl green counterstain. The inspissated material present in dilated lymphatics in mesenteric lymph nodes also contained IgG, IgA, IgD, IgE, κ , and λ , as demonstrated using the same direct immunoperoxidase technique and monospecific IgG antiserum (insert) (methyl green counterstain, $\times 64$).

immunoglobulin in the small bowel mucosa has been implicated in the primary pathogenesis of the intestinal abnormality. Results of immunomicroscopy suggest that the underlying mechanism is obstruction and stasis of lymph circulation. The obstruction may relate to the effacement of mesenteric lymph nodes by the malignant lymphoid infiltrate.

References

1. Waldenstrom J: Incipient myelomatosis or "essential" hyperglobulinemia with fibrinogenopenia—a new syndrome? *Acta Med Scand* **117**: 216–247, 1944.
2. Cabrera A, de la Pava S, Pickren JW: Intestinal localization of Waldenstrom's disease. *Arch Intern Med* **114**: 399–407, 1964.
3. Beker S, Grases PJ, Merino F, et al: Intestinal malabsorption in macroglobulinemia. *Am J Dig Dis* **16**: 648–656, 1971.
4. Khilnani MT, Keller RJ, Cuttner J: Macroglobulinemia and steatorrhea; roentgen and pathologic findings in the intestinal tract. *Radiol Clin North Am* **7**: 43–55, 1969.
5. Olmer J, Mongin M, Muratore R, et al: Étude de sept cas personnels de macroglobulinémie de Waldenstrom. *Sang* **31**: 415–440, 1960.
6. Schechterman L, Tyler SJ: Waldenstrom's macroglobulinemia. Localization in ileum and lacrimal glands. *NY State J Med* **70**: 2025–2029, 1970.
7. Pruzanski W, Warren RE, Goldie JG, et al: Malabsorption syndrome with infiltration of the intestinal wall by extracellular monoclonal macroglobulin. *Am J Med* **54**: 811–818, 1973.
8. Cawley L: Immunomicroscopy workshop, American Society of Clinical Pathologists, March 10, 1977.
9. Bedine MS, Yardley JH, Elliott HL, et al: Intestinal involvement in Waldenstrom's macroglobulinemia. *Gastroenterology* **65**:

- 308-315, 1973.
10. Bradley J, Hawkins CF, Rowe DS, et al: Macroglobulinaemia and steatorrhoea. *Gut* **9**:564-568, 1968.
 11. Ren G de, Wayoff M, Grilliat JP, et al: Infiltration lymphomateuse maligne des voies aéro-digestives supérieures, et macroglobulinémie. *Ann Oto-Laryng* **77**: 978-981, 1960.
 12. Dawborn JK: Macroglobulinaemia and severe intestinal haemorrhage in lymphosarcoma. *Med J Aust* **48**: 515-516, 1961.
 13. Castleman B, Kibbee BU: Case Records of the Massachusetts General Hospital Case 18-1961. *N Engl J Med* **264**: 504-512, 1961.
 14. Debray J, Lemaire A: Particularités cliniques, hématologiques et biologiques de deux cas de macroglobulinémie. *Sang* **31**: 447-453, 1960.