

# Regional portal hypertension

Raul Aron, M.D.  
Alejandro Zapolanski, M.D.  
Avram M. Cooperman, M.D.  
Robert E. Hermann, M.D.

*Department of General Surgery*

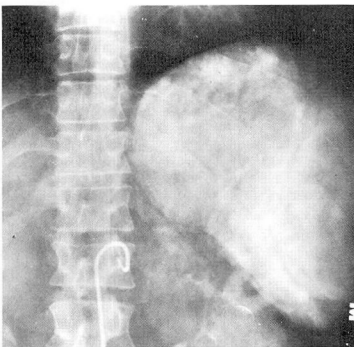
Thrombosis of the splenic vein may result in massive upper gastrointestinal bleeding. In this situation, the venous return from the spleen, body and tail of the pancreas, and short gastric vessels is blocked, creating a high pressure system in the left side of the portal venous system with formation of collaterals and gastroesophageal varices. Those located in the submucosal plexus of the stomach and the lower esophagus are exposed to rupture and bleeding when the mucosal barrier is violated. Although this is an uncommon entity, isolated thrombosis of the splenic vein is found in chronic pancreatitis,<sup>1</sup> pancreatic pseudocyst,<sup>2,3</sup> pancreatic carcinoma,<sup>1,4,5</sup> and less frequently in islet cell adenoma, retroperitoneal fibrosis, and cavernous transformation of the splenic vein.

The diagnosis, treatment, and prognosis of splenic thrombosis differ from other types of portal hypertension. This condition is probably more common than has been suspected, although the exact incidence is unknown.

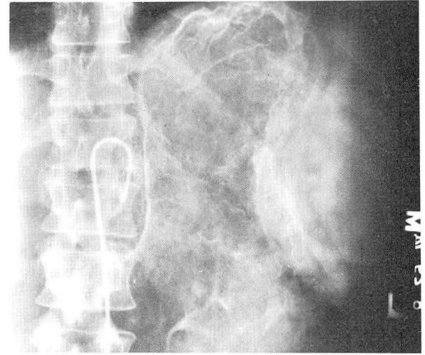
## Case 1

A 39-year-old woman was in good health until 2 months before hospital admission. During this time she twice noted melena and anemia. The hemoglobin levels

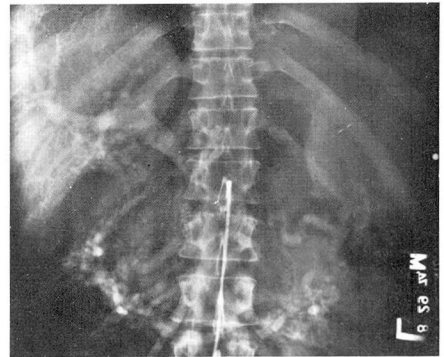
were 4.6 g/dl and 5.6 g/dl. She was hospitalized and transfusions were given. An upper gastrointestinal roentgenogram and barium enema were normal. She had consumed an excessive amount of alcohol for 20 years. Physical examination disclosed moderate splenomegaly. Endoscopic examination of the upper gastrointestinal tract revealed a few scattered superficial erosions of the body of the stomach and antrum without active bleeding. No varices were seen in the esophagus and stomach. The percutaneous liver biopsy specimen was normal. Celiac and superior mesenteric arteriography revealed no visualization of the splenic vein, but large collaterals drained the spleen, and gastric varices were seen in the venous phase (Figs. 1 and 2). The portal vein and superior mesenteric vein were visualized and patent (Fig. 3). A percutaneous splenoportogram confirmed the thrombosis of the splenic vein and demonstrated large gastroepiploic collaterals. The splenic pulp pressure was 350 mm H<sub>2</sub>O. A laparotomy was performed and large, tortuous veins were found in the gastrosplenic ligament and along the fundus and greater curvature of the stomach. The spleen was enlarged to three times its normal size. The liver, stomach, and duodenum were normal. Portal vein pressure was 130 mm H<sub>2</sub>O. The pancreas was indurated and firm throughout its length. A splenectomy with ligation of the largest venous collaterals was performed. The patient has remained asymptomatic without further bleeding during a 3-year follow-up period.



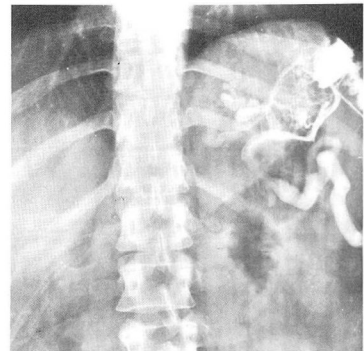
**Fig. 1.** Venous phase of celiac injection does not demonstrate splenic vein.



**Fig. 2.** Arteriogram shows large gastric varices.



**Fig. 3.** Superior mesenteric arteriogram shows patent portal vein.



**Fig. 4.** Splenoportography complements angiography in demonstrating splenic vein thrombosis.

## Case 2

A 69-year-old man was referred for evaluation of recurrent upper gastrointestinal bleeding of unknown origin. Two months

earlier, he had undergone laparotomy for massive gastrointestinal bleeding. A hemigastrectomy with Billroth II reconstruction had been performed, despite the fact that no bleeding site was found at operation. The patient had an episode of massive bleeding on the 12th postoperative day and required 16 units of blood. His medical history revealed moderate alcohol intake for many years. Physical examination was essentially unremarkable. Endoscopy performed after his admission revealed no pathologic changes in the upper gastrointestinal tract. Celiac and superior mesenteric angiography demonstrated thrombosis of the splenic vein with gastric and esophageal varices. These findings were further confirmed by splenoportogram (*Fig. 4*). The patient underwent a laparotomy and, at operation, the large venous collaterals and varices around the gastric remnant and changes in the pancreas were found. He had chronic pancreatitis. The liver was normal. A splenectomy was performed, and the patient had an uneventful recovery. He had no further bleeding after one year of follow-up.

### Case 3

A 64-year-old man had been followed at the Cleveland Clinic for 5 years for idiopathic retroperitoneal fibrosis. He had undergone laparotomy in the past with ureterolysis which was due to the same condition. This time, when examined at the Cleveland Clinic, he had a history of tarry stools, and hematemesis necessitated 22 units of blood. A vagotomy and pyloroplasty had been performed previously. The patient continued to note melena. Endoscopy at another hospital revealed friable mucosa on the distal esophagus with a normal stomach and duodenum. A splenoportogram revealed narrowing of the splenic vein with large varices in the stomach and a splenic pulp pressure of 480 mm H<sub>2</sub>O. At laparotomy a markedly enlarged spleen with huge varicosities around the stomach area was found. The liver and pancreas were normal. The retroperitoneum was thickened. Splenectomy and ligation of the larger varices was performed. The postoperative period was complicated by a sub-

phrenic abscess which cleared. The patient has remained free of further bleeding for 3 years.

### Case 4

A 34-year-old man had a history of heavy alcohol intake for 15 years and abdominal pain and jaundice for the past 6 months. Preoperative roentgenograms disclosed extensive calcifications in the pancreas, and a normal esophagus, stomach, and duodenum were noted on endoscopy. The percutaneous liver biopsy specimen revealed stasis and changes suggestive of extrahepatic biliary obstruction and no cirrhosis. Celiac and superior mesenteric angiography revealed thrombosis of the splenic vein with a patent portal vein and extensive varices in the stomach. A laparotomy was planned to decompress the biliary system. At operation, the distal common duct was obstructed in its intrapancreatic portion. The liver was normal and the pancreas showed marked induration throughout the gland consistent with chronic pancreatitis. Large varicosities were present around the fundus of the stomach, and the spleen was enlarged to four times its normal size. A Roux-Y cholecystojejunostomy was performed. Although this patient had no gastrointestinal bleeding at the time of examination, splenectomy was done to lower portal pressure and prevent episodes of future bleeding.

He committed suicide one year later.

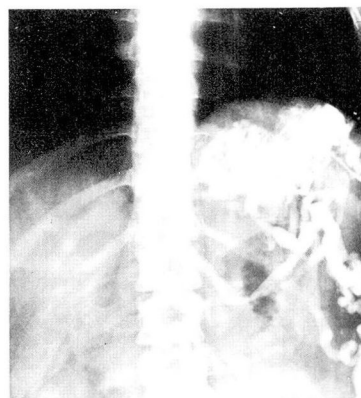
### Discussion

Patients with bleeding esophageal varices secondary to portal hypertension and cirrhosis are often seen in medical practice. Efforts to prolong life by correcting portal hypertension surgically are frequently disappointing because of the magnitude of the procedure, progression of primary liver disease, and alterations that follow diversion of the portal flow from the liver. The four cases reported here represent a special category of portal hypertension in which correction is relatively simple, possibly

permanent, and the long-term prognosis good. These patients had normal liver function, normal pressures in the portal vein, and thrombosis of the splenic vein. Because the venous drainage of the spleen is impaired, regional hypertension distal to the site of thrombosis forces the development of venous collateral pathways. These collaterals are of two types: portoportal and portosystemic. In portoportal the high pressure system drains through collaterals around the greater and lesser curvature of the stomach into the normal portal system (*Fig. 5*). As a direct result of this, submucosal varices of the stomach and esophagus develop, some of which are responsible for the development of lower esophageal varices. Portoportal communications are more common in our experience and may explain why esophageal varices are seldom seen by angiography or endoscopy. A high degree of suspicion and awareness of this condition are necessary to determine the diagnosis, order the appropriate studies, and accurately treat it.

The triad of alcoholic pancreatitis, splenomegaly, and gastrointestinal bleeding is common in these patients. It is not rare that previous examinations have not determined the cause of bleeding.

Conventional studies such as barium roentgenograms and endoscopy may fail to reveal the gastric varices if they are hidden by the gastric folds. The diagnosis can be confirmed accurately by celiac and superior mesenteric angiography or splenoportography. A nonvisualized splenic vein and a patent portal vein will be seen. Gastric varices, particularly around the fundus of the stomach, and marked enlargement of the gastroepiploic veins will also be seen. It is important to make the diagnosis preoperatively, since at operation it may be



**Fig. 5.** Collaterals around the stomach are present in splenic vein thrombosis.

difficult and cumbersome to assess the patency of the splenic vein. The presence of large venous collaterals along the greater and lesser curvature of the stomach with upper gastrointestinal bleeding and no other obvious lesion should alert the surgeon to consider regional portal hypertension. If this finding is not recognized and other operations (e.g., gastric resection) are performed, not only will they fail to control the bleeding, but the condition may be aggravated, since the interruption of the veins along the curvatures of the stomach will interrupt the collaterals draining to the coronary vein and further increase the hypertension in the submucosal veins of the gastric remnant. Cure of regional portal hypertension can be achieved by splenectomy.

The incidence of splenic vein thrombosis in patients with chronic pancreatitis has been estimated at 8% and 24% in two series of patients studied by splenoportography. It is difficult to say how many of those patients bleed, and until this question is answered, prophylactic splenectomy is not justified. A possible exception to this is when regional portal hypertension is found at laparotomy done for other reasons.



In reviewing the literature, we found that the earliest report on splenic vein thrombosis was published by Frick<sup>6</sup> in 1922. Although the definitive diagnosis was made at autopsy, the patient had recurring episodes of bleeding from the upper gastrointestinal tract for 11 years prior to his death.

Following the original papers, many reports were published of patients with this entity with presenting symptoms of gastrointestinal hemorrhage.<sup>2, 3, 5, 7-10</sup> Occasionally splenic vein thrombosis was not associated with bleeding. A review of the English literature by Sutton et al<sup>3</sup> revealed that 64% of patients had hematemesis. The cause of the thrombosis was not obvious in 30% of patients. Very rarely, thrombosis of the splenic vein may result in rupture of the spleen.<sup>11</sup> In this instance, the splenic rupture follows acute passive hyperemia.

Another uncommon cause of splenic vein thrombosis is cancer of the head of the pancreas. As these tumors encroach upon the portal vein, mesenteric varices and gastric varices develop and may bleed acutely or chronically.

We believe that regional portal hypertension should be a primary consideration in patients with upper gastrointestinal bleeding when conventional studies fail to demonstrate the site of bleeding, particularly when a history of pancreatitis is obtained. Angiography should be performed, and if the splenic vein is not visualized, splenoportography should then be done. This will provide the patient and surgeon with the correct diagnosis and simplify accurate treatment.

## Summary

Regional portal hypertension due to

splenic vein thrombosis has been described as a cause of bleeding from the upper gastrointestinal tract. Although there have been several reports, it occurs relatively infrequently.

The cause, method of determining a diagnosis, treatment, and prognosis of regional portal hypertension differ from other types of portal hypertension. Patients with this disease usually have a normal liver and normal pressure in the portal vein. Drainage of splenic blood is impaired, creating venous collaterals.

## References

1. Johnston FR, Myers RT: Etiologic factors and consequences of splenic vein obstruction. *Ann Surg* **177**: 736-739, 1973.
2. Salam, AA, Warren WD, Tyras DH: Splenic vein thrombosis; a diagnosable and curable form of portal hypertension. *Surgery* **74**: 961-972, 1973.
3. Sutton JP, Yarbrough DY, Richards JT: Isolated splenic vein occlusion; review of literature and report of an additional case. *Arch Surg* **100**: 623-626, 1970.
4. Gray SH: Spontaneous rupture of the spleen following venous thrombosis in carcinoma of the pancreas; report of case. *Arch Pathol* **6**: 433-435, 1928.
5. Hershfield NB, Morrow I: Gastric bleeding due to splenic vein thrombosis; a report of three cases. *Canad Med Assoc J* **98**: 649-652, 1968.
6. Frick A: Chronic splenomegaly with attacks of gastrorrhagia due to recurrent thrombosis of the splenic vein. *JAMA* **78**: 424-425, 1922.
7. Agrawal SN, Mathur M: Splenic vein obstruction. *J Indian Med Assoc* **60**: 380-381, 1973.
8. Goldstein GB: Splenic vein thrombosis causing gastric varices and bleeding. *Am J Gastroenterol* **58**: 319-325, 1972.
9. Turrill FL, Mikkelsen WP: "Sinistral" (left-sided) extrahepatic portal hypertension. *Arch Surg* **99**: 365-368, 1969.
10. Yale CE, Crummy AB: Splenic vein thrombosis and bleeding esophageal varices. *JAMA* **217**: 317-320, 1971.
11. Byerly WG: Thrombosis of the splenic vein with secondary rupture of the spleen. *NC Med J* **36**: 352-354, 1975.