

Chronic upper airway obstruction

Methods of detection and recognition

Joseph A. Golish, M.D.
Muzaffar Ahmad, M.D.
James R. Yarnal, Ph.D., D.O.

Department of Pulmonary Diseases

Occult chronic upper airway obstruction is an unusual cause of the symptom complex of wheezing dyspnea. If unrecognized, appropriate therapy will be delayed and the results may be disastrous. The medical history, physical examination, chest roentgenogram, and results of pulmonary function testing can provide clues that enable the clinician to suspect this entity. A definitive diagnosis can be made by other physiologic, roentgenographic, and endoscopic procedures. A special pulmonary function test known as the flow-volume loop may be the most desirable of these procedures. It is a safe, accurate, and inexpensive method of diagnosing occult upper airway obstruction.

Case report

A 36-year-old woman who had smoked 1½ packs of cigarettes daily for 18 years had a 4-month history of suspected bronchial asthma. During that time she had experienced occasional episodes of wheezing and dyspnea at times associated with coughing and hoarseness. Exertion was a definite precipitating factor, although symptoms sometimes occurred at rest. The symptoms were increasing in frequency and intensity, and her exercise tolerance had diminished.

One month before, a diagnosis of bronchial asthma had been made and therapy with ephedrine sulfate,

theophylline, and hydroxyzine hydrochloride (Marax) and tetracycline was instituted. She obtained partial relief, but an exacerbation resulted in her going to the local emergency room; subcutaneous epinephrine provided some relief of symptoms.

She had been seen one week previously for follow-up of acute myelocytic leukemia. Her respiratory symptoms had increased after recent chemotherapy with vincristine, adenine arabinoside (Ara-A), and a tapering course of prednisone. Bilateral inspiratory and expiratory wheezing was noted on examination. The chest roentgenogram was interpreted as normal. Pulmonary function studies were interpreted as "severe obstruction to airflow with good oxygenation and a slight diffusion defect, consistent with asthma or bronchitis" (Table 1). Complete blood count, automated multiple analysis system (SMA-18), urinalysis, and electrocardiogram were normal. A diagnosis of bronchial asthma, precipitated by an upper respiratory infection (asthmatic bronchitis) was made, and the bronchodilator program was escalated.

At the time of this evaluation, she described a progression of her wheezing dyspnea despite therapy. She denied sputum production, hemoptysis, orthopnea, paroxysmal nocturnal dyspnea, and peripheral edema. Her medical history was important in that

a diagnosis of acute myelocytic leukemia had been made 8 months previously. Two weeks after initiation of chemotherapy, pneumonia developed, which resolved after 11 days of ventilatory support and antimicrobial therapy.

Physical examination demonstrated a mildly obese white woman in moderate respiratory distress. She was afebrile and there was no palpable adenopathy. Chest examination demonstrated increased work of breathing with use of the accessory respiratory musculature. Auscultation revealed bilateral inspiratory and expiratory wheezing, especially over the central airways. The chest roentgenogram was normal, but the subglottic tracheal air column was poorly seen. Pulmonary function studies were as previously described (Table 1), although the dramatic decrease in peak flow seemed disproportionate to the degree of obstruction. Additionally, there was no associated hyperinflation, air trapping, maldistribution of ventilation, diffusion abnormality, or hypoxemia.

A flow-volume loop was performed and demonstrated a fixed upper airway obstruction (Table 2). Laryngoscopy revealed a firm circumferential stenosis in the subglottic region and a granulomatous lesion in the right posterior subglottic area. Tracheostomy was performed and resulted in total resolution of

Table 1. Pulmonary function survey

Lung compartments		Distribution	
FRC	91%	N ₂ wash out time	2.1'
ERV	116%	Term N ₂ concentration	2%
RV	98%	Diffusion	
VC	93%	D _L CO _{single breath}	23.1 ml CO/min/torr
TLC	93%		
RV/TLC	34.5% (32.7%)		
Breathing mechanics		Arterial blood studies	
FVC	92%	pH	7.45
PEF	29%	pCO ₂	37 torr
FEF _{200-1200 ml}	27%	Bicarb.	25.6 mEq/L
FEV ₁	49%	pO ₂	85 torr
FEV ₁ /FVC	47%	O ₂ sat.	95%
(FEV ₁ /PEF)	13	BE	+2.0
FEF _{25%-75%}	28%	(A-a O ₂)	15 torr

No significant change was noted in breathing mechanics after inhalation of isoproterenol.

FRC = functional residual capacity, ERV = expiratory reserve volume, RV = residual volume, VC = vital capacity, TLC = total lung capacity, FVC = forced vital capacity, BE = base excess.

Table 2. Flow-volume loop

FVC	92%
FIF _p	46%
FIF _{25%}	48%
FIF _{50%}	42%
FIF _{75%}	47%
FEF _p	52%
FEF _{75%}	52%
FEF _{50%}	61%
FEF _{25%}	141%
(FEF _{50%} /FIF _{50%})	1.7

No significant improvement was noted after inhalation of aerosolized isoproterenol.

the respiratory symptoms and physical findings.

Clues to diagnosis of occult upper airway obstruction

The symptom complex of wheezing dyspnea has several causes. Bronchial asthma is by far the most common, although other disorders can have the same presenting symptoms and should be considered in the differential diagnosis, e.g., congestive heart failure, pulmonary embolus, localized bronchial obstructions, and hypersensitivity pneumonitis. Occult upper airway obstruction is another such entity and may be potentially lethal if misdiagnosed and improperly treated. For the purposes of this discussion, the upper airway is defined as that part of the respiratory tract extending from the lips to the tracheal carina. A variety of neoplastic, infectious, infiltrative, and degenerative processes may involve any portion of that airway intrinsically or extrinsically.¹ If the site of obstruction lies above the suprasternal notch, it is not subject to changes in intrathoracic pressure. Such an obstruction is extrathoracic. In an intrathoracic upper airway obstruction the trachea is narrowed below the suprasternal notch and above the carina.

The historical clues for chronic upper

airway obstruction vary and are nonspecific. They tend to vary with the particular lesion. The patient may describe previous instrumentation of the upper airway at the time of tracheostomy, endotracheal intubation, or thyroidec-tomy. Such a procedure may have been done in the remote past and neither the patient nor the physician associates it with the current symptoms. In addition, many causes of upper airway obstruction, such as tumors or granulomatous infection, demonstrate no such antecedent event. Wheezing and dyspnea tend to be gradually progressive and the exertion required to precipitate symptoms is predictable. Bouts of noisy respiration and shortness of breath may be caused by mucosal edema or accumulation of secretions at the site of obstruction. Characteristically, there should be no symptomatic response to bronchodilators, although steroids and sympathomimetics such as epinephrine may decrease the edema and degree of obstruction. Tracheal tumors in particular will often vary in the degree of obstruction, depending on body position. Some patients localize the obstruction to the windpipe or upper chest as a sensation of blockage or choking. A harsh, dry cough, hoarseness, or hemoptysis are other clues that might point toward upper airway obstruction rather than diffuse bronchial disease.²

On physical examination, the patient with upper airway obstruction will often manifest coarse, sonorous rhonchi without the sibilant, whistling sounds characteristic in the asthmatic. These adventitial sounds are heard best centrally over the sternum and intrascapular area, although they may be projected to the peripheral lung fields. If the upper airway obstruction is extrathoracic, i.e., above the suprasternal notch, the obstruction may be more obvious during

the inspiratory phase of respiration rather than during the expiratory phase. This is in contradistinction to bronchial asthma, where expiration is more prominently impaired.

On occasion, narrowing of the tracheal air column may be seen on a plain chest roentgenogram. This is often a "blind spot" for the radiologist and many films are too underpenetrated to visualize this area. In a Mayo Clinic series of 53 patients with tracheal tumors, only 13 had abnormal tracheas on the chest roentgenograms.³ Hyperinflation as a roentgenographic stigmata of chronic obstructive pulmonary disease (COPD) is rarely present in the patient with upper airway obstruction.

Pulmonary function studies in patients with chronic upper airway obstruction provide physiologic data suggestive of this diagnosis (*Table 3*). There may be a dramatically disproportionate reduction in the early flow rates for a given reduction in the forced expiratory volume at one second. This is reflected by an elevated ratio of the forced expiratory volume over the peak expiratory flow.⁴ The mid and late flows, reflective of small airways function, may be well preserved. There should be little or no objective change in the mechanics of breathing after inhalation of an aerosol bronchodilator. A

Table 3. Physiologic clues to chronic upper airway obstruction

Mechanics
Disproportionately diminished PEF and $FEF_{200-1200\text{ ml}}$ for a given FEV_1
$FEV_1/PEF > 10\text{ ml/L/sec}$
$FEF_{25\%-75\%}$ may be preserved
No change postbronchodilator
$MVV_{\text{actual}}/MVV_{\text{predicted}} < 0.85$
Compartments show slight elevation in RV, FRC, RV/TLC
Distribution, diffusion, and arterial blood gas studies normal

measured maximal voluntary ventilation will be less than predicted for a given forced expiratory volume (FEV_1) because of the inspiratory obstruction. Hyperinflation is absent or present to only a mild degree, and there is rarely evidence of maldistribution, maldiffusion, or significant hypoxemia because of the intact peripheral airways and pulmonary parenchyma.⁵

In the case reported here, certain clues to occult chronic upper airway obstruction were present. Although it antedated the onset of symptoms by 4 months, the patient had undergone an 11-day course of respiratory support via an oral endotracheal tube. On physical examination the rhonchi that were noted were low-pitched and sonorous. Although projected to the peripheral lung fields, they were most notable in the central and substernal areas. There was a suggestion of narrowing of the subglottic tracheal air column on the chest roentgenogram. The pulmonary function survey indicated that some mechanism of decreased airflow, besides diffuse bronchial obstruction and asthma, was present (*Table 1*). The peak expiratory flow was severely diminished disproportionately to the moderately impaired forced expiratory volume at one second. The resulting FEV_1/PEF ratio was elevated at 13 (normal 10). Inhalation of aerosol bronchodilators did not improve the mechanics of breathing. The breathing compartments, distribution of ventilation, diffusion of gases, and arterial blood studies were surprisingly well maintained in a patient thought to have severe bronchial asthma.

Definitive diagnosis of occult upper airway obstruction

Several procedures are available to confirm the diagnosis of suspected upper airway obstruction: tomograms of the

trachea, lateral xerograms of the neck soft tissues, cineradiography, and tantalum tracheography. The major disadvantage in each of these procedures is that they visualize only a portion of the upper airway and frequently need to be performed in conjunction with one another to document or exclude upper airway obstruction.⁶ The most direct means of detecting upper airway obstruction and determining a specific diagnosis is endoscopic examination. This can be performed with a laryngoscope or fiberoptic bronchoscope. Although the latter approach is the most specific, it is also the most invasive of those described.

Like the spirogram of the pulmonary function survey, the flow-volume loop is a graphic display of breathing mechanics during the forced vital capacity maneuver (Fig. 1A). Unlike the simple spirogram, however, the instantaneous flow rates obtained from the flow-volume loop are much more sensitive indicators of transient changes in airway dynamics.⁷ These changes allow for detection of airway obstruction and increased airway resistance. The site of increased resistance can be identified, whether diffuse bronchial obstruction, unilateral bronchial stenosis, or narrowing of the upper airway. Furthermore, the nature and site of the upper airway obstruction can be demonstrated, thereby reducing the diagnostic possibilities (Table 4), facilitating the choice of an invasive diagnostic technique, and

even aiding in the type of therapeutic intervention.

When airflow is diminished because of upper airway obstruction, the configuration of the flow-volume loop is abnormal in the early inspiratory or expiratory portions or both. In the *fixed* upper airway obstruction, a plateau is seen early in the inspiratory and expiratory phases (Fig. 1B). In the *variable extrathoracic* upper airway obstruction, that plateau only occurs early in *inspiration* (Fig. 1C). In contradistinction, the *variable intrathoracic* upper airway obstruction produces a plateau early in *expiration* only (Fig. 1D).

In cases of *variable* upper airway obstruction, the degree of obstruction var-

Table 4. Diminished flow secondary to upper airway obstruction

Fixed intrathoracic or extrathoracic upper airway obstruction
Laryngeal or tracheal stricture
Extensive laryngeal or tracheal tumor or granuloma
Cricoarytenoid ankylosis
Extensive mediastinal disease
Variable extrathoracic upper airway obstruction
Myxedema
Cord paralysis
Laryngomalacia
Localized laryngeal tumor or granuloma
Oropharyngeal tumor
Lingual tonsil or thyroid
Variable intrathoracic upper airway obstruction
Tracheocondromalacia
Localized tracheal tumor or granuloma
Foreign body
Limited mediastinal disease

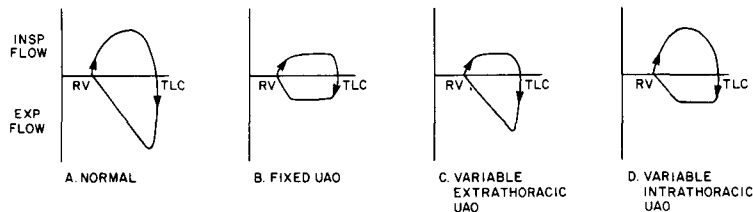


Fig. 1 A-D. Flow-volume loop in upper airway obstruction.

ies with the phase of respiration. This situation occurs when the lesion is non-circumferential and some part of the laryngeal or tracheal wall may respond to the changes in pleural and airway pressures. This variability in obstruction may also occur when the lesion is circumferential, but the diseased wall of the larynx or trachea is flaccid and can respond to changes in pressure within the airway or external to it. With these varying kinds of obstruction, the location of the lesion above the suprasternal notch, i.e., extrathoracic, or below the suprasternal notch, i.e., intrathoracic, determines the configuration of the flow-volume loop. With a variable intrathoracic obstruction, such as tracheomalacia, the trachea dilates in response to the negative intrapleural pressure during inspiration (Fig. 2). As a result, inspiratory flows are often normal. However, when pleural pressures become positive, the diseased trachea responds by narrowing its caliber early in the expiratory portion. This results in the expiratory plateau that occurs with variable intrathoracic upper airway ob-

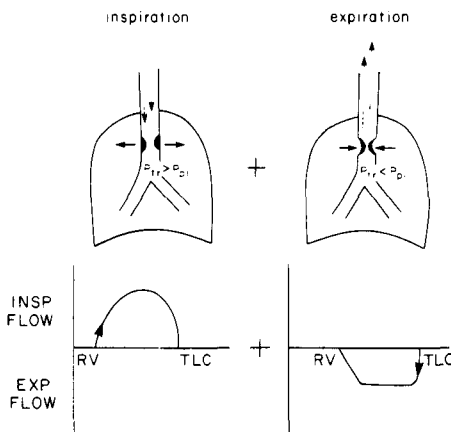


Fig. 2. Variable intrathoracic upper airway obstruction. (Adapted from Kryger M: Chronic upper airway obstruction; early detection and recognition. *Am J Med* 61: 87, 1976; with permission of American Journal of Medicine.)

struction. When the variable lesion is above the suprasternal notch, such as bilateral vocal cord palsies, negative intralaryngeal pressures during inspiration result in a narrowed airway and impaired flow during the early inspiratory phase of the flow-volume loop (Fig. 3). During exhalation, the positive intralaryngeal pressures generated dilate the flaccid area of obstruction, and the expiratory portion of the loop is normal.²

In fixed upper airway obstruction, the diameter of the airway is not responsive to changes in tracheal and pleural pressures. The plateau configuration, therefore, is present both in the inspiratory and expiratory phases. This results in a boxlike shape to the flow-volume loop (Fig. 1B).

The flow-volume loop of the patient described had the boxlike configuration of a fixed upper airway obstruction. The instantaneous flow rates obtained from that curve are listed in Table 2. The forced vital capacity was normal, excluding any restrictive problem. There

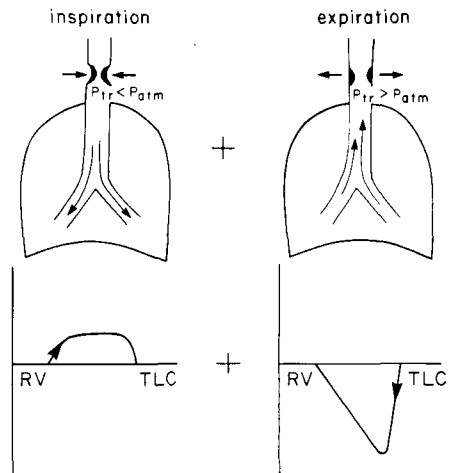


Fig. 3. Variable extrathoracic upper airway obstruction. (Adapted from Kryger M: Chronic upper airway obstruction; early detection and recognition. *Am J Med* 61: 87, 1976; with permission of American Journal of Medicine.)

was a remarkable reduction in all of the inspiratory flow rates, whereas the expiratory flow rates were reduced only in the early part of the curve. The forced expiratory flow at 25% of vital capacity or the $FEF_{25\%}$ was remarkably well maintained and indicated normal small airways caliber. The mid-vital capacity ratio or $FEF_{50\%}/FIF_{50\%}$ was 1.7 and, therefore, above the normal value of 0.8 to 1.0.⁸ This disproportionate reduction in the inspiratory flow rate is suggestive of an extrathoracic location to the obstructive phenomenon. After inhalation of a bronchodilator, there was essentially no change in the configuration of the loop or the instantaneous flow rate. This study was diagnostic, therefore, of a fixed upper airway obstruction, most likely extrathoracic in its location. The presence of a diffuse bronchial obstructive disorder such as asthma was excluded. The differential diagnosis was then limited to a laryngeal or subglottic tracheal stricture or granuloma (*Table 4*). Direct laryngoscopy under general anesthesia confirmed those diagnoses and a tracheotomy resulted in total resolution of the airway obstruction.

Subtle clues to the presence of chronic upper airway obstruction may be gleaned from the medical history, physical examination, chest roentgenogram,

and routine pulmonary function testing. A definitive diagnosis requires the use of more specialized physiologic, roentgenographic, and endoscopic studies. The pulmonary function test known as the flow-volume loop is highly sensitive, specific, and noninvasive. Furthermore, it can limit the differential diagnostic possibilities and allow one to select more appropriately the more invasive techniques and therapy.

References

1. Proctor DF: The upper airways. Part II. The larynx and trachea. *Am Rev Respir Dis* **115**: 315-342, 1977.
2. Kryger M, Bode F, Antic R, et al: Diagnosis of obstruction of the upper and central airways. *Am J Med* **61**: 85-93, 1976.
3. Houston HE, Payne WS, Harrison EG Jr, et al: Primary cancers of the trachea. *Arch Surg* **99**: 132-140, 1969.
4. Empey D: Assessment of upper airways obstruction. *Br Med J* **3**: 503-505, 1972.
5. Sackner MA: Physiologic features of upper airway obstruction. *Chest* **62**: 414-417, 1972.
6. Fraser RG, Paré JA: Chapter 11, Diseases of the airways, in *Diagnosis of Diseases of the Chest*, v. 3, ed 2. Philadelphia, WB Saunders, 1979, pp 1297-1325.
7. Hyatt RE, Black LF: The flow-volume curve; a current perspective. *Am Rev Respir Dis* **107**: 191-199, 1973.
8. Rotman HH, Liss HP, Weg JG: Diagnosis of upper airway obstruction by pulmonary function testing. *Chest* **68**: 796-799, 1975.