

# Percutaneous femoral single catheter technique

Fred W. Schoonmaker, M.D.

*Denver, Colorado*

After a generation of coronary arteriography two basic techniques have evolved, the first being the more traditional brachial and the second the percutaneous femoral artery approach with multiple preformed catheters. Design and performance of these catheters have required consideration of curve and manipulations. The development consideration at this institution involved pursuing a basic percutaneous single catheter through systematic analysis of these existing approaches. Optional designs took into account the problem definition of torque control, catheter stiffness, angle, and tip flexibility, thereby eliminating either a cutdown or many changes with guidewires and preformed catheters.

Fundamentally, a nonspecific curve for selective canalization of both the left and right coronary arteries as well as ventriculography and bypass graft opacification resulted. A polyurethane, 100 cm, No. 8 French catheter with a 45° curve and flexible tip was used.

The technique that evolved was not designed to take the place of, but more to offer an alternative to the already well-established and existing techniques.

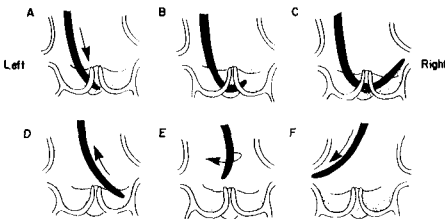
## **Technique**

The catheter is introduced percutaneously from

either the right or left femoral artery by a Seldinger guide. Advancement over the aortic arch is without a guide. Selective canalization of the left and right coronary arteries is made by loops or rotations (*Figure*). The left artery is catheterized by advancing the tip of the catheter into the noncoronary cusp posteriorly. As the loop is formed, the tip will approach the coronary ostia for opacification. Difficulties may occur in advancing too rapidly with passage of the tip across the aortic valve into the left ventricle. Withdrawal should be made and the tip repositioned in the noncoronary sinus.

The right coronary artery is approached differently, by simple clockwise rotation to approach the right ostia slowly. If rotation is too rapid or at an inappropriate level for the orifice, the catheter may not be engaged. Another approach to a more laterally or posteriorly located artery is to form a loop parallel to the plane of the valve with the distal end pointing tangentially away from the center of the loop. Manipulation or slow clockwise rotation will advance the catheter circumferentially into the ostia. Right ostia that do not form right angles to the aortic root will often require this second loop technique.

Ventriculography is accomplished by advancing the catheter against the aortic valve directly or with loop formation until it passes through the valve and enters the left ventricle. It should be



**Figure.** Diagrammatic drawing shows the loop and rotations needed for selective canalization of the left and right coronary arteries.

**Table.** Complications in 12,000 cases

Complications (major)	Total	Percent
Death	6	0.050
Myocardial infarction	7	0.058
Cerebrovascular accident	2	0.017
Femoral arterial occlusion	23	0.197
*Arrhythmias: ventricular tachycardia and/or fibrillation	11	0.092
Total	49	

\* Last 5 years

guided into the midventricle with the tip parallel to the long axis. The end and side holes enhance diffuse media dispersal and prevent recoil. Prematurity may require that minimal adjustment be made by slightly advancing, withdrawing, or rotating into a more acceptable position away from the septum and to a parallel plane to the mid-portion of the left ventricle.

With the anteriorly located anastomosis of saphenous bypass grafts and the tendency for the catheter to maintain an anterior position in the ascending aorta, clockwise rotation of the tip is ideally suited for entry and visualization of these grafts. Intraaortic balloon assist devices and prosthetic valves have shown no unusual difficulty for complete study. Single or multiple pharmacologic challenges can be met rapidly when one becomes proficient with the single catheter technique. Such would include ergotamine maleate for spasm, nitroglycerin for systolic contraction, arterial narrowing or selective injections of nitroglycerin or isotopic studies for repeating both coronary and ventricular evaluations without changing catheters.

Complications have been infrequent and fall into two general categories: (1) local and femoral, and (2) cardiac or cerebral. The *Table* lists the major complications in the 12,000 cases that have been done at this hospital since the inception of this technique in 1967.