

The use of drains in abdominal surgery

Roland S. Philip, M.D.*

Surgeons are often faced with the decision of whether or not to drain the peritoneal cavity and, if so, when. Drainage is usually considered beneficial when there is a well-localized, thick-walled collection of fluid. Management is less clear, however, when the problem affects the entire peritoneal cavity. Since the appearance of Yates' classic paper on drains in 1905,¹ it has been thought that a fibrous capsule rapidly forms around drainage tubes placed in the peritoneal cavity, causing the drains to seal off and drain only a small, localized area.

Most experimental work on drains has been performed in animals. In this study, the occasion of elective surgery was used to examine the flow pattern of radiopaque contrast material injected through drain tubes placed during operation.

Materials and methods

In two patients undergoing elective cholecystectomy for calculous disease of the gallbladder, Shirley sump tubes were placed for drainage of the hepatic portal area. Immediately after the abdominal wall and skin were closed, approximately 30 ml of 50% diatrizoate sodium (Hypaque) was injected through the sump tube, and a roentgenogram was obtained in the operating room. Subsequent

*Department of Surgery, Kaiser-Permanente Medical Center, Cleveland, Ohio 44120.

studies were performed in the radiology department. All injections were performed by hand, utilizing 50% Hypaque as the contrast material. The patient in Case 1 had studies performed on postoperative days 1 and 3; the patient in Case 2 had studies performed on postoperative days 1, 2, 3, and 5.

Results

In Case 1, the opaque material spread throughout the lesser omental sac with no apparent loculation (*Fig. 1A-C*). In Case 2, the opaque material spread throughout the free peritoneal cavity on days 1, 2, and 3. On the fifth postoperative day, contrast material seemed to be localized to the subhepatic space (*Fig. 2A-E*).

Discussion

In 1905, Yates¹ published a persuasive work on the effect of peritoneal drainage. After reviewing both the clinical

and experimental papers published up to that time, he performed an extensive series of experiments on dogs to determine the efficacy of drains in the peritoneal cavity. His principal conclusions were: (1) drainage of the general peritoneal cavity is physically and physiologically impossible as relative encapsulation of the drain is immediate; and (2) absolute encapsulation occurs early.

Hanna² felt that drainage is indicated in peritonitis and then described a more effective drainage system. He noted that experimentally injected methylene blue, if not removed by drainage, will spread in the peritoneal cavity. In animal experiments and clinical studies concerning prophylactic drainage, Nora et al³ concluded that drains had the dangerous potential of introducing exterior infection. In the discussion of Nora's³ work, Blackwood described an experiment in which fluid instilled into the peritoneal cavity of dogs would not exit

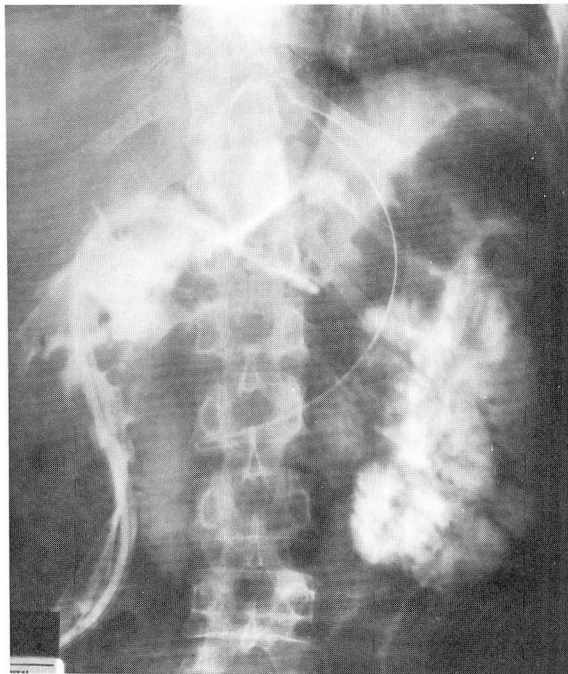


Fig. 1A. Case 1. Immediately postoperative. Opaque material completely outlines the lesser sac.

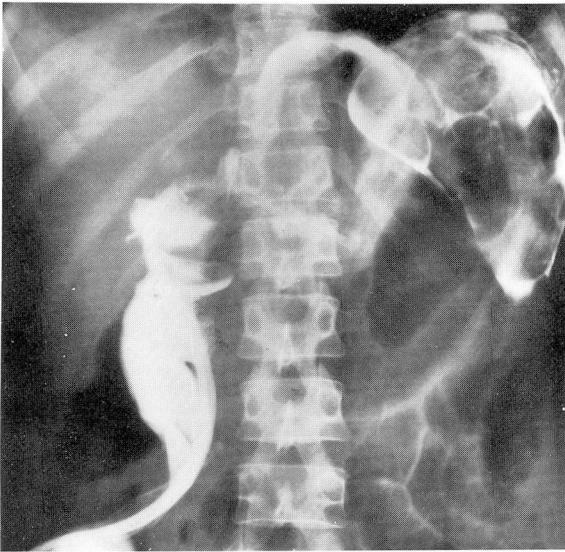


Fig. 1B. Case 1. Postoperative day 1. Opaque material outlines the lesser sac and drain area.

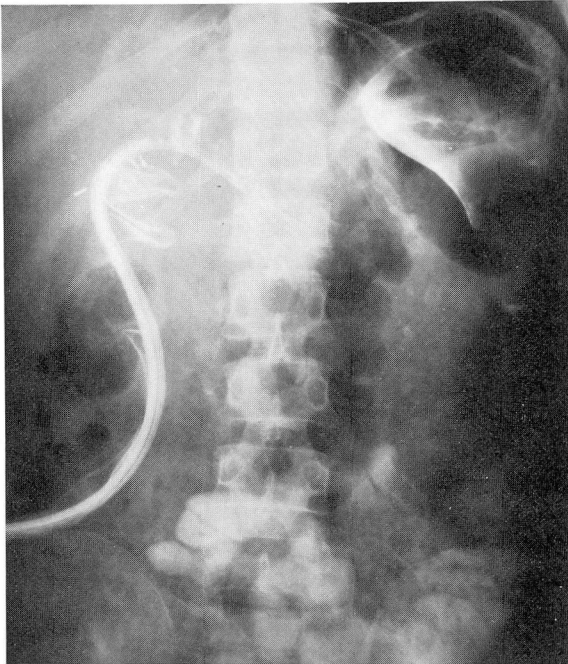


Fig. 1C. Case 1. Postoperative day 3. Opaque material still flows freely in the lesser sac.

through the drains because they were sealed by the peritoneum or omentum. Duthie⁴ agreed that draining the abdomen is of no use in generalized peritonitis since the drain becomes sealed off

from the peritoneal cavity within 6 hours of insertion, but acknowledged that even this generally accepted principle is disregarded by some.

Myers⁵ found that drains were effec-

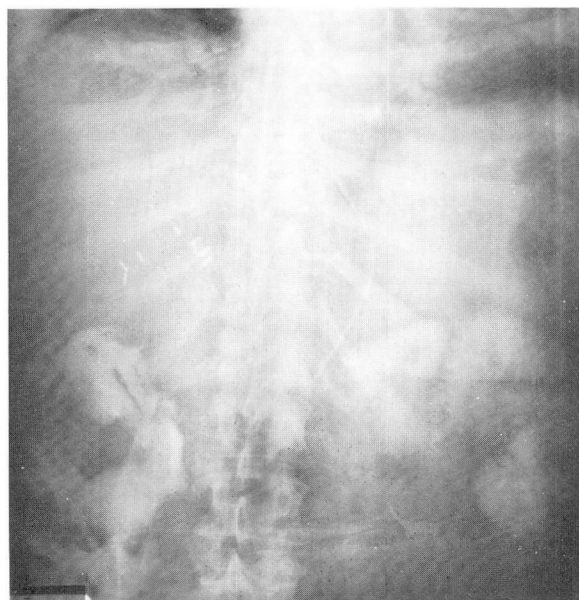

Fig. 2A. Case 2. Immediately postoperative. Opaque material flows in the right lower quadrant.

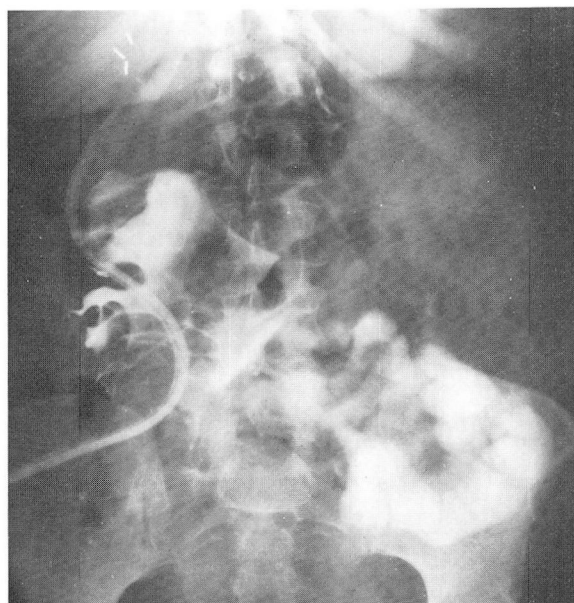


Fig. 2B. Case 2. Postoperative day 1. Opaque material flows freely in the lower abdomen.

tive only for a limited area and for a short period of time. He believed they should be used only when drainage is expected, and removed when there is no

additional discharge, and that negative pressure applied to the drain improves its function. Ranson⁶ reported prolonged functioning of a modified sump

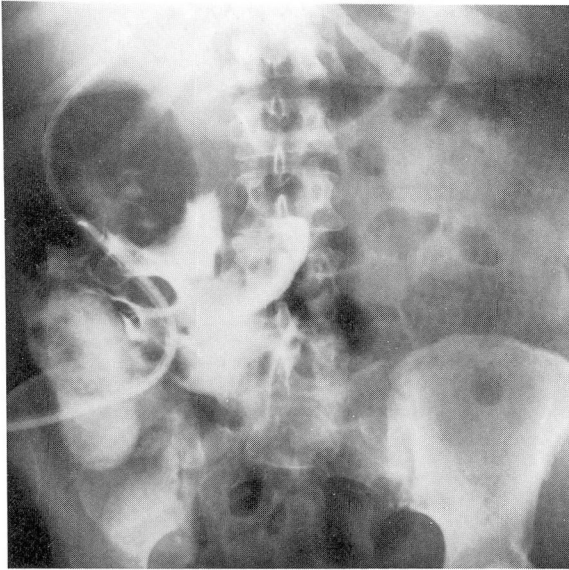


Fig. 2C. Case 2. Postoperative day 2. Opaque material flows freely in the lower abdomen.

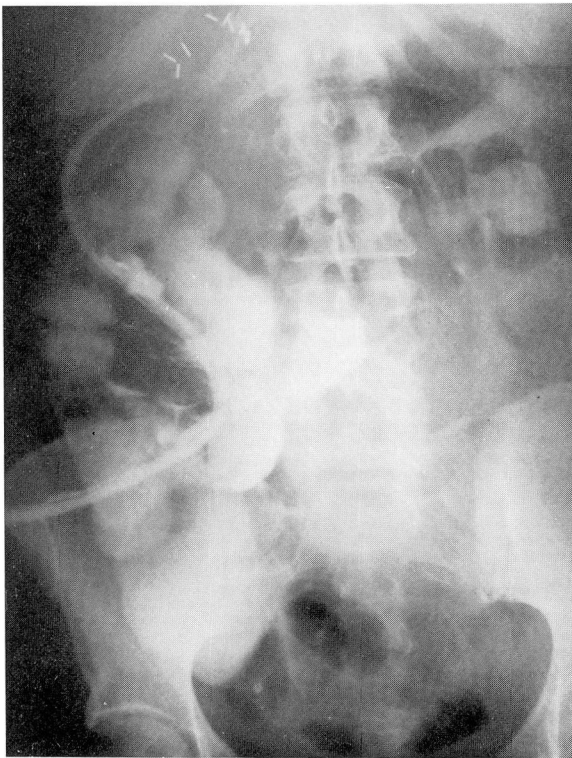


Fig. 2D. Case 2. Postoperative day 3. Opaque material flows freely in the lower abdomen and among the intestinal loops.

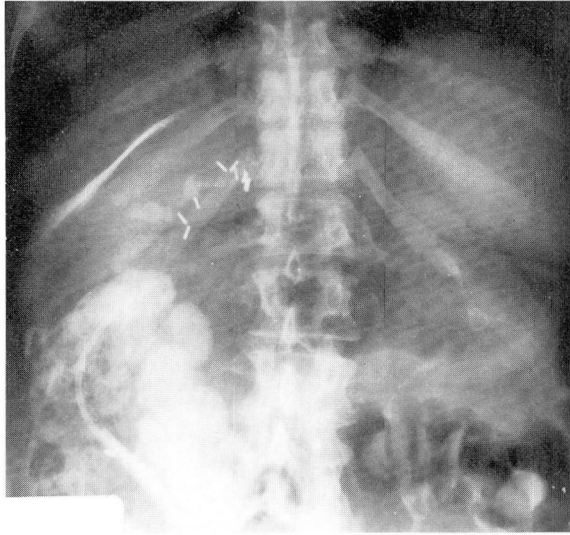


Fig. 2E. Case 2. Postoperative day 5. Opaque material is localized in the perihepatic area.

drain for periods of up to 6 weeks. Sollasol et al⁷ described a tubular silicone drain capable of functioning for long periods of time. Formeister and Elias⁸ described a suction drain made of non-reactive material that remains patent and functions for long periods of time. Hermann,⁹ in reviewing the techniques and indications for abdominal draining, emphasized his support for Yates' statement that drains "serve no purpose in the treatment of generalized peritonitis."

The problem of whether or not to drain has been present throughout the modern surgical era. Some experimental work performed in dogs demonstrates that drains seal rapidly and could not possibly be useful in draining anything but a localized collection. Other studies also performed in dogs reveal that the efficacy of drains depends in part on their construction, with regard to both material used and whether or not suction is to be applied. Many reports describe the long-term functioning of drains in human subjects.

In the present work performed clinically, injected contrast material spread either throughout the lesser omental sac or in the general peritoneal cavity, depending on where the tip of the drain lay. These dye injections were performed over a period of days and therefore demonstrate that the peritoneal cavity in man potentially could be drained over a prolonged period of time. Many variables were not subject to experimental control, such as infection or possible outflow with the drains not injected.

When other areas of medicine are examined, a real question as to the validity of canine experiments performed more than three quarters of a century ago may be raised. The example of peritoneal dialysis, in which there is continued egress of fluid through the drain catheter for long periods of time, is offered.

At the present time there is not enough well-documented clinical work to draw absolute conclusions as to the efficacy of attempting to drain the peri-

toneal cavity; the use of drains remains part of the art rather than the science of medicine.

Summary

Radiopaque dye injected immediately after the abdomen was closed and serially over the remaining hospital course spread throughout the lesser omental sac in one patient and the free peritoneal cavity in the second. There was no evidence during the study that loculation of the dye had occurred. Although the paucity of experimental work in the literature on the functioning of drains tends to support the belief that they are only locally effective, the cases reported here demonstrate that the entire noninfected peritoneal cavity could be drained. The use of drains in patients with generalized peritonitis might thus be more effective than has been previously thought.

References

1. Yates JL. An experimental study of the local effects of peritoneal drainage. *Surg Gynecol Obstet* 1905; **1**: 473-92.
2. Hanna EA. Efficiency of peritoneal drainage. *Surg Gynecol Obstet* 1970; **131**: 983-5.
3. Nora PF, Vanecko RM, Bransfield JJ. Prophylactic abdominal drains. *Arch Surg* 1972; **105**: 173-6.
4. Duthie HL. Drainage of the abdomen. *N Engl J Med* 1972; **287**: 1081-3.
5. Myers MB. Use and abuse of drains in abdominal surgery. *J La State Med Soc* 1973; **125**: 7-9.
6. Ranson JH. Safer intraperitoneal sump drainage. *Surg Gynecol Obstet* 1973; **137**: 841-2.
7. Solassol C, Joyeux H, Benhamou A, Pujol H, Romieu C. Drainage de longue durée en chirurgie abdominale. La lame multibulbaire en silicone. *Nouv Presse Med* 1975; **4**: 1570.
8. Formeister JF, Elias EG. Safe intra-abdominal and efficient wound drainage. *Surg Gynecol Obstet* 1976; **142**: 415-6.
9. Hermann G. Intraperitoneal drainage. *Surg Clin North Am* 1969; **49**: 1279-88.