

# Mitral valve prolapse in children and adolescents

Douglas S. Moodie, M.D.

*Department of Cardiology*

*Department of Pediatrics and Adolescent  
Medicine*

Mitral valve prolapse appears to be a frequent cardiovascular finding, particularly in young females. Echocardiographic surveys have demonstrated findings of mitral valve prolapse in 6%–10% of normal young women.<sup>1</sup> Although well described in adults,<sup>2–4</sup> the clinical features of mitral valve prolapse in children and adolescents have seldom been discussed.<sup>5–9</sup> In this study, we review the clinical, electrocardiographic (ECG), echocardiographic, and angiographic findings, exercise response, and follow-up history in patients with mitral valve prolapse seen at the Cleveland Clinic who were less than 20 years of age.

## Material and methods

Twenty-six patients less than 20 years of age with mitral valve prolapse detected by echocardiography were seen between February 1979 and December 1981 at the Cleveland Clinic. There were 14 females and 12 males whose ages ranged from 3 to 20 years with a mean of 15 years. Of the 26 patients, 4 had Marfan's syndrome, one forme fruste. Two patients had mitral valve prolapse associated with congenital heart disease; one of these had tetralogy of Fallot and the other had ostium primum atrial septal defect with Down's syndrome. One patient had anorexia nervosa with mitral valve prolapse. These

7 patients were eliminated from our series to permit concentration on patients with isolated mitral valve prolapse with no obvious secondary abnormality. Thus, our study consisted of 19 patients with isolated mitral valve prolapse whose ages ranged from 6 to 24 years (mean, 16 years). There were 11 females and 8 males, a female/male ratio of 1.4:1.

A detailed history was obtained and physical examination given all patients. All had routine chest radiographs, standard 12-lead ECGs and M-mode echocardiographic examinations. Echocardiograms were obtained with an ATL machine with a multichannel recorder. Various transducers, both focused and unfocused, were used ranging from 2.25 to 5 MHz. Recordings from the free wall of the mitral valve leaflets were obtained with the transducer placed perpendicular to the chest wall along the left sternal border. In every patient mitral valve prolapse was arbitrarily defined as any movement of the mitral valve leaflets posterior to an imaginary line drawn parallel to the chest wall from the closure or C-point of the mitral valve echogram.

Seven patients underwent ECG stress exercise tests with the Bruce protocol on a treadmill. Blood pressure and 12-lead ECGs were recorded every minute during the exercise test and during the postexercise period, which lasted three to five minutes. Five patients had Holter monitor recording, one patient a His bundle study, and 3 patients underwent cardiac catheterization. All patients were contacted six months to two years after evaluation at the Cleveland Clinic with a mean follow-up of one year.

Results

*Clinical features.* The most common clinical signs and symptoms are listed in

*Table 1.* Sixteen of 19 patients (84%) had a heart murmur, and one third of the patients complained of palpitations. In addition, there were vague symptoms of lightheadedness and near syncope, and one patient complained of chest pain.

*Physical findings.* A mid-systolic click was noted in 14 of 19 patients (74%). Thirteen of 19 (68.4%) also had a grade I to II/VI midsystolic to late systolic murmur, and 3 of 19 patients had a louder, grade III/VI mid-late systolic murmur.

Thirteen of 19 patients (68.4%) had both a click and a murmur at the time of the initial presentation (*Table 2*). Three of 19 (16%) had a murmur, but no click. One of 19 patients (5%) had a click but no murmur, and 2 of 19 patients (11%) had silent mitral valve prolapse with no click or murmur (*Table 2*). No diastolic murmurs were noted in any of the patients.

One of 19 patients (5%) had pectus excavatum, and one had scoliosis. All children were between the third and 97th percentile for weight and height.

**Table 1.** Clinical signs and symptoms (19 patients)

	Patients	
	Number	Percent
Heart murmur	16	84
Palpitations	6	31
Lightheadedness	2	11
Near syncope or syncope	2	11
Supraventricular tachycardia	1	5
Chest pain	1	5

**Table 2.** Cardiac physical examination (19 patients)

	Patients	
	Number	Percent
Click and murmur together	13	68
Murmur but no click	3	16
Click but no murmur	1	5
No click or murmur	2	11

*Radiographic findings.* Chest radiographs were normal in all but 2 patients. One had mild pectus excavatum and one had mild scoliosis.

*Electrocardiographic findings.* All patients had sinus rhythm. Twenty-six percent (5/19 patients) had abnormalities on the resting ECG tracing consisting of T-wave inversion or diphasic T-waves in the inferior leads. Two patients (11%) presented with bigeminy; one (5%) developed atrial fibrillation after catheterization, but had sinus rhythm at follow-up.

*Echocardiographic features.* All patients had echocardiographic features of mitral valve prolapse based on criteria previously described.<sup>10</sup> None had marked left atrial or left ventricular enlargement. *Figure 1* demonstrates the mid-systolic click coinciding with maximum prolapse of the mitral valve seen on the echocardiogram.

*Exercise testing.* Stress ECG exercise tests were performed by 7 of 19 patients (37%). Six of 7 patients demonstrated normal work capacity, heart rate response, and blood pressure during exercise. Two patients had resolution of premature ventricular contraction (PVC) with exercise. One patient had reduced total work performance. None had ventricular ectopy or arrhythmias during exercise. Five had ST-segment depression during the exercise test.

*His bundle studies.* One patient underwent His bundle study, which demonstrated a mild conduction abnormality through the atrioventricular (AV) node; however, a Holter monitor recording one year after this study was normal.

*Ambulatory monitoring.* Five of 19 patients (26%) underwent 24-hour Holter monitor recording. Three of the 5 patients had sinus rhythm throughout the recording; one of these had a documented history of supraventricular

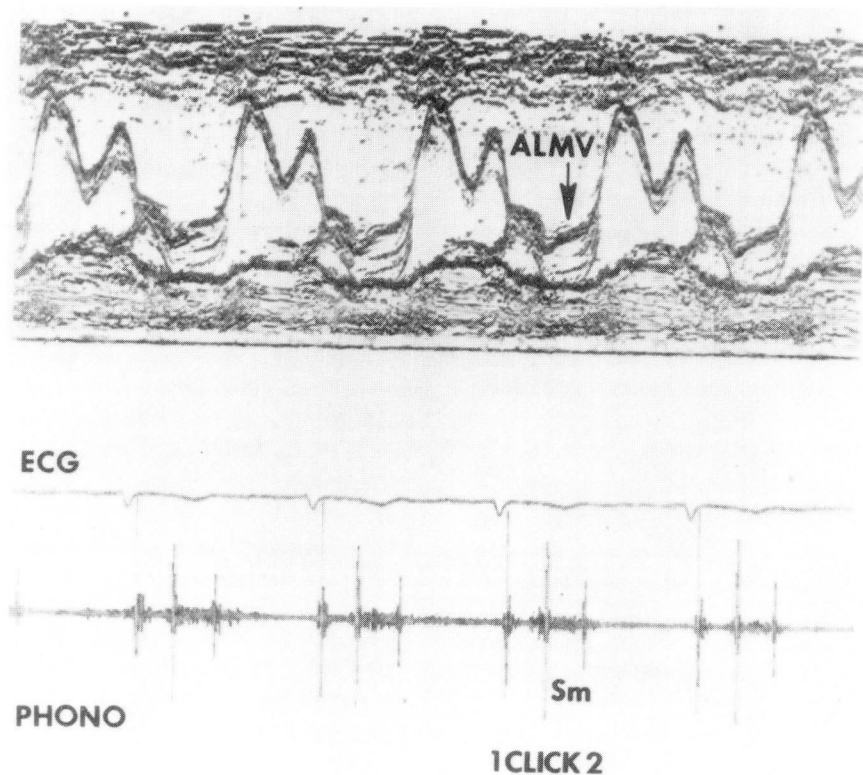
tachycardia. One patient had a Mobitz type I block with occasional PVCs, and one patient showed evidence of AV dissociation with multifocal PVCs and premature atrial contractions.

Angiography was performed in 3 of 19 patients (18%) with no evidence of notable mitral insufficiency. One patient who had frequent PVCs at rest that decreased with exercise had mild left ventricular dysfunction visualized on a left ventriculogram in the right anterior oblique projection. One patient with Mobitz type I block with occasional PVCs had a mild left ventricular contraction abnormality compatible with a mild myocardiopathy. One patient with more severe arrhythmias with AV dissociation, multifocal PVCs, and premature atrial contractions had moderately severe left ventricular dysfunction compatible with moderate myocardiopathy (*Fig. 2*).

*Follow-up.* All patients have been followed from six months to two years with a mean follow-up of one year. Currently, 18 of 19 patients (95%) are asymptomatic and New York Heart Association Functional Class I with no exercise limitations. Seventeen of 19 patients (90%) are not receiving medication. One patient is taking nadolol (Corgard) for a documented history of supraventricular tachycardia. One is receiving propranolol (Inderal) for frequent PVCs and a moderately severe myocardiopathy. This patient is Functional Class II.

## Discussion

The major pathologic finding common to all patients with mitral valve prolapse is myxomatous degeneration of the leaflets of the mitral valve, resulting in redundancy of the mitral leaflet tissue, which prolapses into the left atrium during systole. The posterior mitral valve leaflet appears to be more affected



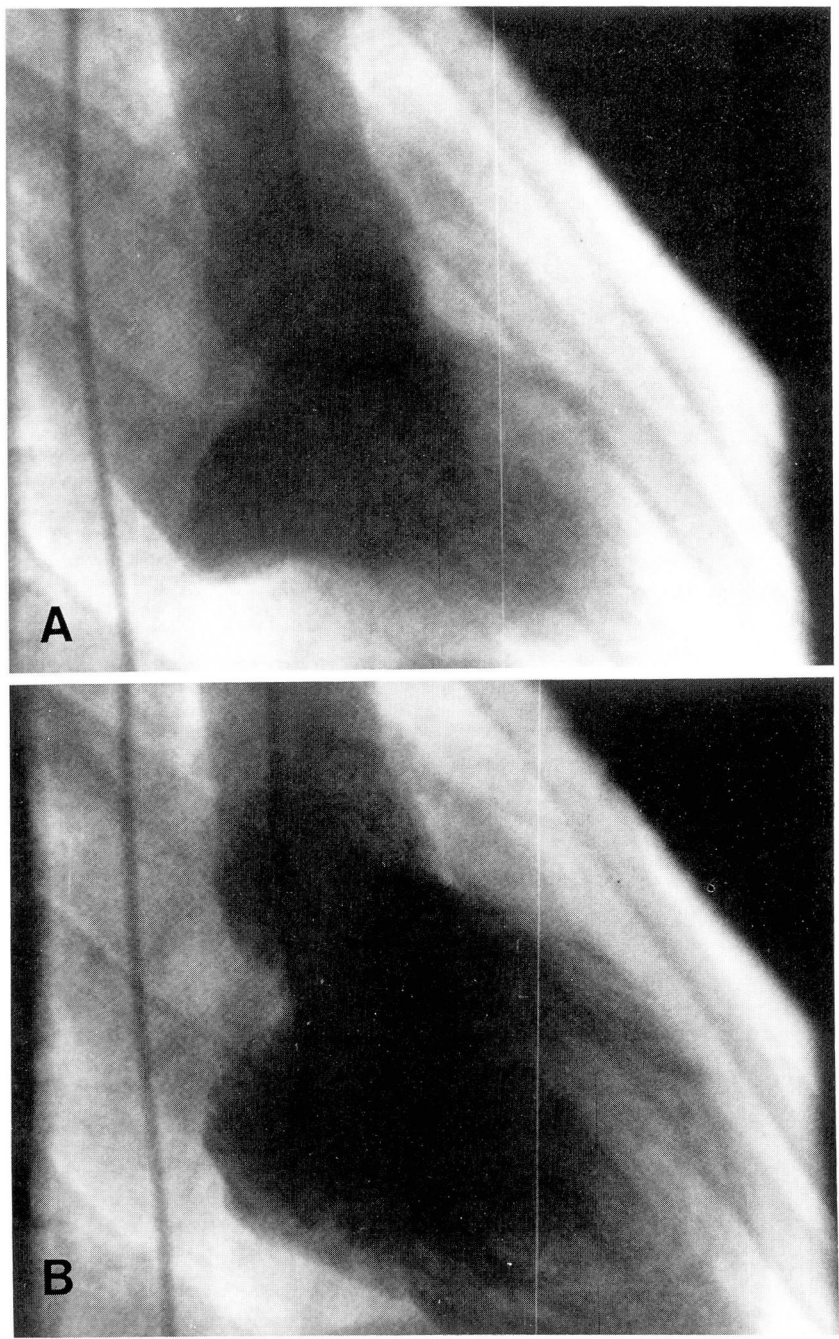
**Fig. 1.** M-mode echocardiogram, electrocardiogram, and phonocardiogram in a patient with mitral valve prolapse. The phonocardiogram demonstrated that the click of mitral valve prolapse occurs at the time of maximum leaflet prolapse. A late systolic murmur is noted. ALMV = anterior leaflet of the mitral valve, ECG = electrocardiogram, phono = phonocardiogram, Sm = systolic murmur.

by this process than the anterior leaflet. There may also be elongation of chordae tendineae and enlargement of the mitral valve annulus. Histologically, pools of mucinous substance are seen and special staining techniques identify large amounts of mucopolysaccharides. Primordium of the mitral valve develops between the 35th and 42nd day of fetal life, when the vertebrae and thoracic cage are beginning chondrification and ossification. Whatever affects fetal development at this stage might affect both the mitral valve and the bony thorax.

In most instances, the cause of mi-

tral valve prolapse is unknown. Several studies have documented an increased familial incidence and indicate an autosomal dominant mode of inheritance as in Marfan's syndrome.<sup>11</sup> We did not identify familial cases in our study group and did not systematically conduct physical examinations of first degree relatives. However, in a random sampling of parents and siblings, we found no evidence of mitral valve prolapse in the families of these patients. Four of 19 patients had Marfan's syndrome and were excluded as the association of Marfan's syndrome and mitral valve prolapse is well known. Mitral





**Fig. 2.** Left ventriculogram, RAO view, systolic (A) and diastolic (B) frames demonstrating moderately severe left ventricular dysfunction in a patient with mitral prolapse and moderately severe primary myocardial disease.

valve prolapse has been described in patients with rheumatic heart disease<sup>4, 12</sup>, congenital heart disease, particularly atrial septal defect<sup>13</sup> and in pediatric and adult patients with cardiomyopathy.<sup>14</sup> Two of our 26 patients had congenital heart disease. One had Down's syndrome with an ostium primum atrial septal defect, and one patient had tetralogy of Fallot. One study<sup>15</sup> reports 3 of 5 adult patients with tetralogy of Fallot demonstrating mitral valve prolapse. In most cases of mitral valve prolapse, the cause is entirely unknown.

Many studies have alluded to the prevalence of this syndrome in females.<sup>3, 4, 9</sup> Our female/male ratio of 1.4:1 is somewhat less than that reported by others, with a ratio of 2-5:1. Other surveys have demonstrated findings of mitral valve prolapse in 6%-10% of normal young women.<sup>1</sup> The total number of patients with mitral valve prolapse constituted 3% of all the new patients seen during that two-year period in our Pediatric Cardiology Clinic and would perhaps suggest that mitral valve prolapse is not as prevalent as has been previously described.

The major indication for referral of patients to our institution in this study was the presence of a heart murmur and/or palpitations. Lightheadedness, near syncope, documented supraventricular tachycardia, and chest pain were infrequent findings. No patient in our study had had a previous stroke or complained of migraine headaches. No patient was referred specifically for the presence of frequent PVCs.

A common finding in the prolapsing mitral valve syndrome has been the isolated midsystolic click (*Fig. 1*). The click is a high frequency sound of short duration that has been described as

clicking, snapping, or popping in character. Midsystolic click, its intensity and exact timing in systole can vary considerably from beat to beat, irrespective of the respiratory cycle. The clicks are best heard at the left lower sternal border and at the apex, and are thought to be generated by the sudden tensing of the redundant leaflet and an elongated chordae tendineae. Echocardiographic studies (*Fig. 1*) have shown that the click begins at the onset of mitral valve prolapse and reaches peak intensity at the time of maximum leaflet prolapse. The systolic click is often accompanied by a late systolic murmur, which is initiated by or begins just before the click (*Fig. 1*). The murmur is crescendo-decrescendo, peaking at the time of maximum mitral leaflet prolapse during late systole and occasionally extending through the aortic second heart sound. Most of our patients presented with both a click and a murmur (68.4%); only 2 had no click or murmur, the classic *silent* mitral valve prolapse. This coincides with the low prevalence described in pediatric patients in a previous report.<sup>9</sup> Conditions that reduce left ventricular volume, such as standing, the Valsalva maneuver, tachycardia, and ingestion of amyl nitrite, will lengthen the systolic murmur, and the click will move closer to the first heart sound. Conditions that increase left ventricular volume, namely squatting, bradycardia, and ingestion of propranolol and pressor agents, reduce the intensity and shorten the murmur in systole, and the click will move toward the second heart sound. There has been a prevailing belief that it is critical to examine a patient with mitral valve prolapse in the supine, standing, sitting, and squatting positions, and in some instances it may be necessary to use

medication such as amyl nitrite to bring out the clinical findings. However, in our study, most patients were examined in the sitting, supine, and standing positions and could be clearly identified because in most the classic click murmur was clearly audible without medications.

A characteristic asthenic body habitus has been associated with mitral valve prolapse.<sup>16</sup> We have also noted an unusual neurasthenic body habitus, particularly in young females. This was present even after excluding patients with Marfan's syndrome. Thoracic and skeletal abnormalities have been described by Bon Tempo et al.<sup>17</sup> We found only one patient with straight back syndrome and pectus excavatum, and only one patient with scoliosis. Thus, we had a low prevalence of the skeletal abnormalities that have been more frequently described in the past.

We also have a low prevalence of the characteristic electrocardiographic pattern of posteroinferior myocardial ischemia. Bisset et al<sup>9</sup> described T-wave inversion or diphasic T-waves in the inferior leads in 48% of 116 patients. We noted these changes in 5 of 19 patients (26%). Lardani et al<sup>18</sup> from this institution, detected a 36% prevalence of T-wave changes in the inferior leads in adults. Bisset's group<sup>9</sup> also recently described arrhythmias at presentation in 17 of 119 patients with mitral valve prolapse. The most common rhythm disturbance in their group was unifocal ventricular ectopic beats (59%). Pickoff et al<sup>19</sup> also described frequent PVCs as a presenting feature of mitral valve prolapse in childhood. None of our patients presented with PVCs as a primary problem. Only 2 patients (11%) had bigeminy or PVCs demonstrated at rest. The reason for the difference between the

low prevalence of PVCs in our study and the higher figures in previously described pediatric studies remains unclear.

Bisset's study also recorded the results of exercise ECGs in 43 patients who underwent graded exercise testing. Twenty-three of their patients (35%) had ST-segment depression during exercise, 9% demonstrated multifocal-unifocal PVCs during and after exercise, and 11% had both ST-segment depression and PVCs during exercise. Two of their patients who had frequent PVCs in the preexercise period developed regular sinus rhythm with exercise. Six of 7 of our patients had a completely normal work capacity, heart rate, and blood pressure response. Two of our 7 patients with PVCs had resolution or reduction of PVCs with exercise. Only one patient with myocardial pathology had a reduced total work performance. None of our patients demonstrated ventricular ectopy or arrhythmias during exercise. Five patients had ST-segment depression during exercise.

Our studies agree with those of Bisset et al<sup>9</sup> in that the prognosis for isolated mitral valve prolapse in children appears to be excellent, as indicated in our results above. The growth and development patterns in our patients have been normal, and all patients are living normal lives without marked exercise restriction. From our experience, the findings of ventricular ectopy should at least alert the clinician to the possibility of an underlying myocardial process, even when the physical examination, chest radiograph, and ECG do not suggest underlying primary myocardial disease. In patients who have frequent ventricular ectopy that increases during exercise and is well demonstrated on ambulatory monitoring, we advise cath-

eterization to rule out primary myocardial disease.

We strongly recommend subacute bacterial endocarditis prophylaxis for dental, gastrointestinal, and genitourinary surgical procedures. Among 87 consecutive patients with subacute bacterial endocarditis in one series, 10 (11%) had mitral valve prolapse.<sup>20</sup> In most cases, subacute bacterial endocarditis occurs in the patient with mitral prolapse who has a distinct mitral regurgitation murmur rather than only a nonejection click.<sup>21</sup> However, 7 cases of subacute bacterial endocarditis have occurred in patients with a click alone<sup>22</sup> and one case of subacute bacterial endocarditis has been reported in a patient who had neither a click nor a murmur before the appearance of subacute bacterial endocarditis in what later proved to be mitral valve prolapse.

Most pediatric patients with mitral valve prolapse live full, normal, productive lives; however, because of the rare but possible complications that can occur, we advise patients to be followed up on a regular basis in our cardiology clinic.

## References

1. Markiewicz W, Stoner J, London E, Hunt SA, Popp RL. Mitral valve prolapse in one hundred presumably healthy females (abstr). *Circulation* 1975; **52** (suppl II): II-77.
2. Barlow JB, Bosman CK, Pocock WA, Marchand P. Late systolic murmurs in non-ejection ("mid-late") systolic clicks; an analysis of 90 patients. *Br Heart J* 1968; **30**: 203.
3. Jersaty RM. Mitral valve prolapse; click syndrome. *Prog Cardiovasc Dis* 1973; **15**: 623-652.
4. Pocock WA, Barlow JB. Etiology and electrocardiographic features of the billowing posterior mitral leaflet syndrome; analysis of a further 130 patients with a late systolic murmur or nonejection systolic click. *Am J Med* 1971; **51**: 731-739.
5. Schwartz DC, Kaplan S, Meyer RA. Mitral valve prolapse in children; clinical, echocardiographic, and cine angiographic findings in 81 cases. *Am J Cardiol* 1975; **35**: 160-169.
6. Schmaltz AA, Ibrahim ZI, Apitz J. Clinical, angio- and echocardiographic findings in 45 children with mitral valve prolapse syndrome. *Eur J Cardiol* 1978; **7**: 49-58.
7. Engle MA. The syndrome of apical systolic click, late systolic murmur, and abnormal T waves. *Circulation* 1969; **39**: 1-2.
8. Screenivasan VV, Liebman J, Linton DS, Downs TD. Posterior mitral regurgitation in girls possibly due to posterior papillary muscle dysfunction. *Pediatrics* 1968; **42**: 276-290.
9. Bisset GS III, Schwartz DC, Meyer RA, James FW, Kaplan S. Clinical spectrum and long-term follow-up of isolated mitral valve prolapse in 119 children. *Circulation* 1980; **62**: 423-429.
10. Meyer RA. Pediatric Echocardiography. Philadelphia: Lea and Febiger, 1977: 175.
11. O'Rourke RA, Crawford MH. The systolic click-murmur syndrome: clinical recognition and management. *Curr Probl Cardiol* 1976; **1**: 1-60.
12. McLaren MJ, Hawkins DM, Lachman AS, Lakier JB, Pocock WA, Barlow JB. Non-ejection systolic clicks and mitral systolic murmurs in black schoolchildren in Soweto, Johannesburg. *Br Heart J* 1976; **38**: 718-724.
13. Betriu A, Wigle ED, Felderhof CH, McLoughlin MJ. Prolapse of the posterior leaflet of the mitral valve associated with secundum atrial septal defect. *Am J Cardiol* 1975; **35**: 363-369.
14. Jersaty RM. Mitral ballooning; a possible mechanism of mitral insufficiency in diseases associated with reduced end-systolic volume of the left ventricle. *Chest* 1971; **60**: 114-115.
15. Rippe JM, Sloss LJ, Angoff G, Alpert JS. Mitral valve prolapse in adults with congenital heart disease. *Am Heart J* 1979; **97**: 561-573.
16. Hurst JW, Logue RB, Schlant RC, Wenger NK, eds. *The Heart, Arteries, and Veins*. New York: McGraw-Hill, 1978: 1016.
17. Bon Tempo CP, Ronan JA Jr, de Leon AC Jr, Twigg HL. Radiographic appearance of the thorax in systolic click-late systolic murmur syndrome. *Am J Cardiol* 1975; **36**: 27-31.
18. Lardani H, Moreyra A, Manubens S, Belardi J, Fava M, Sheldon WC. Electrocardiographic findings in 125 patients with idio-



- pathic prolapse of the mitral valve studied by angiography. *Cleve Clin Q* 1976; **43**: 181-194.
19. Pickoff AS, Gelband H, Ferrer P, Garcia O, Tamer D. Premature ventricular contractions as a presenting feature of mitral valve prolapse in childhood. *J Pediatr* 1979; **94**: 615-617.
20. Corrigan D, Bolen J, Hancock EW, Popp RL. Mitral valve prolapse and infective endocarditis. *Am J Med* 1973; **63**: 215-222.
21. Jeresaty RM. Mitral valve prolapse. New York: Raven Press, 1979: 187.
22. Pandian MG, Lichtman A. Mitral valve prolapse and bacterial endocarditis. *Conn Med J* 1976; **40**: 675-676.