

# Coronary artery fistulae: a 10-year review

Robert E. Hobbs, M.D.  
H. David Millit, M.D.  
Prakash V. Raghavan, M.D.  
Douglas S. Moodie, M.D.  
William C. Sheldon, M.D.

*Department of Cardiology*

Coronary fistulae are abnormal communications between a coronary artery and cardiac chamber or great vessel. Rarely recognized clinically, these uncommon entities are occasionally discovered during the performance of coronary arteriography. Most reported cases of coronary fistulae are associated with a variety of symptoms or complications,<sup>1-4</sup> and on this basis some authors advocate surgical repair of all coronary fistulae when discovered. We have found that most fistulae are small and rarely result in symptoms or complications. To study this concept further, we have reviewed the Cleveland Clinic's ten-year experience with this coronary anomaly.

## **Methods and materials**

The data base consisted of all patients who underwent coronary arteriography at The Cleveland Clinic Foundation from 1971 to 1981. A computerized survey identified patients with coronary artery anomalies including coronary artery fistulae. Cardiac catheterization reports, cineangiograms, and clinical records were reviewed for completeness. Follow-up visits or telephone surveys with the referring physician were undertaken. Repeat coronary arteriography was performed in selected patients.

## Results

During the ten-year study, 55,856 patients underwent coronary arteriography at the Cleveland Clinic. Of these, 101 patients (0.2%) were found to have coronary artery fistulae. Sixty-eight of the 101 patients (67.3%) were male and 33 (32.7%) were female. Age ranged from 5 to 74 years with a mean of 53.5 years.

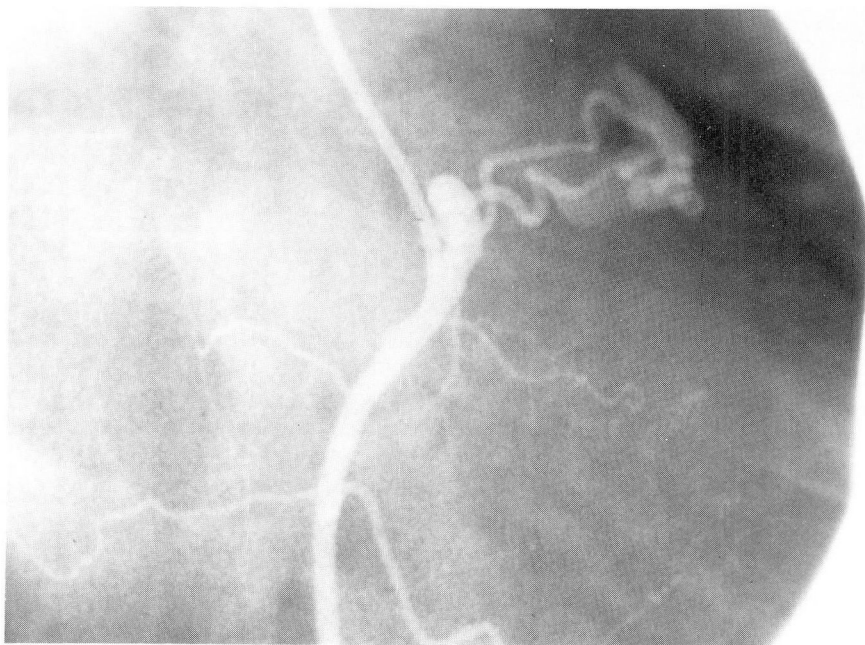
Associated diseases included arteriosclerotic heart disease in 57 patients (56.4%); hypertension in 20 (19.8%); congenital heart disease in 9 (8.9%); and rheumatic heart disease in 8 (7.9%). Twenty-three patients (22.8%) had no associated cardiac diseases.

Eighty patients (79.2%) had a single coronary artery fistula, and 21 patients (20.8%) had multiple fistulae (*Figs. 1 and 2*). Multiple fistulae originated in more than one coronary artery and

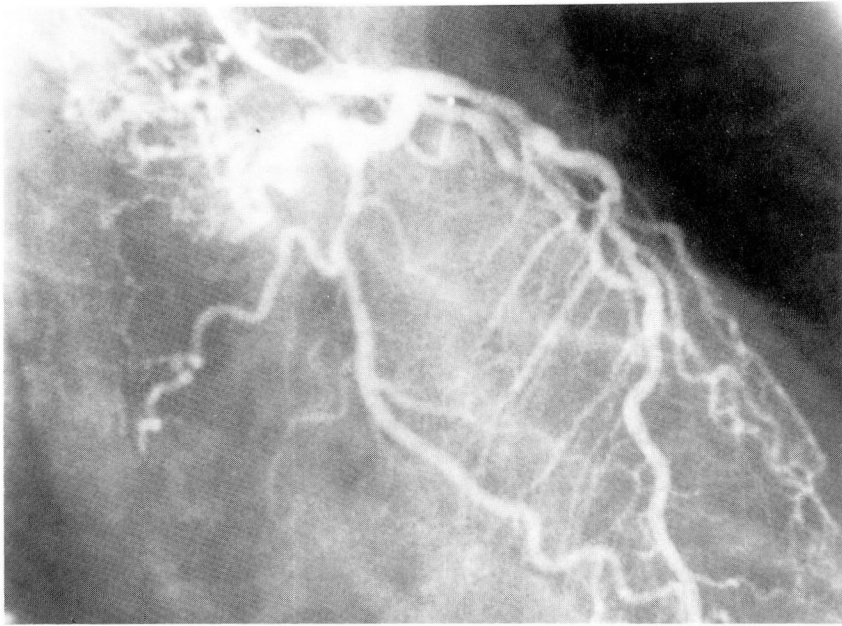
drained in most cases into a single recipient chamber. The sites of origin and drainage are listed in *Table 1*.

A total of 122 fistulae were identified. Thirty-two fistulae (26.2%) originated from the right coronary artery, 38 (31.1%) from the left anterior descending, and 52 (42.6%) from the circumflex artery. Seventy-one fistulae (58.2%) drained into the right side of the heart, and 51 (41.8%) drained into the left. Drainage sites listed in the order of frequency included pulmonary artery (65.6%), left ventricle (17.2%), left atrium (6.6%), right atrium (7.4%), and right ventricle (3.3%). One hundred ten fistulae were classified as small, three as medium, and nine as large.

In 98 of 101 patients (97%) the fistulae were discovered as incidental findings at the time of catheterization and were not suspected clinically. Only 3 of 101 patients (3%) had a continuous



**Fig. 1.** Selective right coronary arteriography, right anterior oblique projection. A small fistula originates near the origin of the vessel and passes rightward to the main pulmonary artery.



**Fig. 2.** Selective left coronary arteriography, right anterior oblique projection. Multiple small fistulae (upper left) originate from the proximal portions of the left anterior descending and circumflex branches and drain into the pulmonary artery.

**Table 1.** Sites of origin and drainage

Drainage	Single fistula			Origin				
	RCA	LAD	Cx	Total	RCA	LAD	Cx	Total
SVC/RA	3	0	3	6	2	0	1	3
RV	3	0	1	4	0	0	0	0
PA	6	17	29	52	11	11	6	28
LA	2	2	0	4	2	0	2	4
LV	<u>0</u>	<u>4</u>	<u>9</u>	<u>13</u>	<u>3</u>	<u>4</u>	<u>1</u>	<u>8</u>
Total	14	23	42	79	18	15	10	43

RCA = right coronary artery, LAD = left anterior descending, Cx = circumflex, SVC = superior vena cava, RA = right atrium, RV = right ventricle, PA = pulmonary artery, LA = left atrium, LV = left ventricle.

murmur or other manifestations suggestive of a coronary fistula.

Ninety patients were treated medically whereas 11 underwent surgical correction. Medical treatment was advocated if the fistulae were small and clinical manifestations lacking. Four of 11 surgically treated patients had ligation of the fistula as the sole indication for

surgery, and the remaining 7 patients underwent correction of other cardiac defects as well. The presence of a large fistula associated with signs and symptoms was the major indication for surgery. No operative deaths occurred in this series.

Follow-up ranged from 1 to 11 years. Thirty-two of 101 patients subsequently

died of associated cardiac diseases, but no deaths were attributed to coronary fistulae. During the follow-up interval, none of the medically treated patients developed signs, symptoms, or complications as a result of coronary fistulae. Eight medically treated patients underwent repeat cardiac catheterization, which demonstrated no change in the fistula's size compared to the previous study. In the surgically treated group, ligation of the fistula eliminated the murmur and improved functional capacity. Three surgically treated patients also had angiographic studies postoperatively, which showed obliteration of the fistulous connection.

## Discussion

*Etiology.* Coronary artery fistulae are uncommon anomalies found in all age groups.<sup>5,6</sup> Most are congenital in origin and are thought to arise from the persistence of the intratrabecular vascular network within the myocardium.<sup>7</sup> Pulmonary artery fistulae may represent accessory coronary arteries arising from the pulmonary trunk and communicating with branches of the two normal coronary arteries.<sup>8</sup> Acquired coronary artery fistulae occasionally are discovered as late sequelae of penetrating or nonpenetrating thoracic injury.<sup>9-12</sup> Traumatic coronary artery fistulae are more common in the right coronary artery and usually communicate with the right side of the heart. Traumatic atrial septal defect, ventricular septal defect, or valve disruption may also occur. Aortocoronary vein fistulae have been reported as a potential complication of coronary artery bypass surgery.<sup>13,14</sup>

*Anatomy.* Fistulae may arise from one or both coronary arteries. The vessel proximal to a fistula is usually normal, but may be aneurysmally dilated, elongated, and/or tortuous. The diameter of

a fistula tends to be larger at the origin than at the drainage site. Two types of drainage patterns occur: a single direct communication with the recipient chamber or multiple fistulous channels draining into one or more sites.

*Hemodynamics.* Hemodynamic manifestations depend on the size of the shunt and the drainage site.<sup>15</sup> Most fistulae are small and have insignificant shunts, but occasionally large fistulae with massive flow rates are encountered. Because of their low resistance, fistulae may receive preferential shunting of blood from the proximal coronary artery. Fistulae that drain into the right side of the heart function as left-to-right shunts. Hemodynamic consequences of large fistulae include right-sided volume overload with an increase in pulmonary blood flow. Fistulae draining into the left side of the heart are hemodynamically similar to aortic regurgitation, and may result in left ventricular volume overload.<sup>16</sup> Drainage into a low-pressure chamber may be associated with blood flow during systole and diastole, resulting in a continuous murmur. The vast majority of coronary artery fistulae are found to be hemodynamically insignificant at the time of cardiac catheterization. Pressures within the cardiac chambers are normal and shunts are undetectable by oximetry.

*Clinical manifestations.* Most patients with coronary artery fistulae are asymptomatic.<sup>16,17</sup> The most common symptoms include dyspnea, fatigue, and weakness. Congestive heart failure secondary to volume overload is most likely to occur in infancy or in old age.<sup>18</sup> Angina pectoris is quite rare in the absence of arteriosclerotic coronary artery disease.<sup>6</sup> Life expectancy is normal in most cases.

Results of physical examination usually are normal; however, large fistulae

may be associated with a variety of abnormal findings. Arterial and venous pulses and pulse pressures are usually normal. Large fistulae or fistulae draining into the left ventricle may be associated with a brisk, collapsing pulse and wide pulse pressure similar to that occurring in aortic regurgitation. Larger fistulae are also associated with a prominent cardiac impulse and palpable systolic thrill. The first and second heart sounds usually are normal, but P-2 may be prominent. Murmurs are frequently undetectable in patients with small fistulae. A continuous murmur with a superficial quality is the most frequently observed abnormality.<sup>6, 17, 19</sup> With left ventricular drainage, a diastolic decrescendo murmur is characteristic, but a systolic murmur may occur with retrograde flow. The location of the murmur occasionally is helpful in localizing the drainage site.

*Diagnostic studies.* The electrocardiogram in most cases is normal or nonspecific.<sup>17</sup> Electrocardiographic abnormalities secondary to larger fistulae reflect the hemodynamic alterations and chamber enlargement. The chest roentgenogram is usually normal, but may demonstrate enlargement of the recipient chamber, prominence of the pulmonary vascularity, or of the aortic knob.

The echocardiogram is normal in most cases. Increased right ventricular dimensions and paradoxical septal motion are seen as a consequence of right-sided volume overload. Increased left ventricular dimensions and contractility often reflect a left ventricular volume overload pattern. Contrast echocardiography combined with selective coronary arteriography may clarify the drainage site.<sup>20</sup> Cardiac catheterization and selective coronary arteriography permit the precise diagnosis of coronary artery

fistulae and are especially helpful when clinical manifestations are absent or when multiple fistulous vessels are discovered. Shunts are undetectable in most cases and intracardiac pressures are usually normal.<sup>8</sup>

*Natural history.* Little is known about the natural history of coronary artery fistulae. Few patients die in infancy and childhood and the majority of adult patients are asymptomatic. The clinical course reflects the size and location of the fistula.<sup>17</sup> Small fistulae do not seem to undergo progressive enlargement in most cases, and are seldom associated with symptoms or complications. Their discovery during coronary arteriography or postmortem examination in various age groups supports the benign nature of these anomalies. Larger fistulae are more likely to be associated with clinical manifestations and complications.

*Complications.* The incidence of progressive enlargement of fistulae is unknown (Table 2). Documentation requires serial angiographic studies, which have been performed in few patients with inconclusive results. We were unable to demonstrate progressive enlargement in our patients. Premature atherosclerosis may be a potential complication, although it was not found in our series. Bacterial endocarditis has rarely been reported and appears to be inde-

**Table 2.** Potential complications

Progressive enlargement
Premature atherosclerosis
Bacterial endocarditis
Rupture
"Coronary steal syndrome"
Myocardial ischemia or infarction
Pulmonary hypertension
Thromboembolism
Congestive heart failure
Death

pendent of fistula size.<sup>21</sup> Rupture of a fistulous vessel is extremely rare. The "coronary artery steal syndrome," producing angina pectoris from a diversion of blood into the low resistance channel, is much less common than expected. Myocardial infarction or ischemia rarely is seen.<sup>22</sup> Mild-to-moderate pulmonary hypertension may occur as a consequence of large left-to-right shunt. Congestive heart failure occurs most commonly in infancy and old age.

**Management.** The management of patients with coronary artery fistulae remains controversial. Although some authors advocate ligation of all fistulae when diagnosed, others hold a more conservative view.<sup>23, 24</sup> The potential goals of surgical intervention are the preservation of myocardial function, the prevention of symptoms or complications, and prolongation of life. Small coronary artery fistulae are not incompatible with a normal life span and do not require surgical repair. Clear indications for surgical intervention include the presence of large shunts, other major cardiac lesions, symptoms, or complications.<sup>16, 22, 25</sup> Surgery is not indicated in the asymptomatic patient with a small fistula. The most commonly employed surgical technique consists of ligation of the distal orifice from within the recipient chamber.<sup>25</sup> Proximal ligation may be complicated by myocardial ischemia or infarction. Ligation of the fistula usually results in the disappearance of the murmur and improvement in the hemodynamic status.

### Summary

Most coronary artery fistulae are small, benign anomalies, which are discovered during the routine performance of coronary arteriography. Follow-up studies indicate that small fistulae tend to remain small, and do not result in

symptoms or complications. Large fistulae, which are associated with signs, symptoms, and complications, should be surgically ligated at their drainage sites when discovered.

### References

1. Barnes RJ, Cheung ACS, Wu RWY. Coronary artery fistula. *Br Heart J* 1969; **31**: 299-305.
2. Hudspeth AS, Linder JH. Congenital coronary arteriovenous fistula. *Arch Surg* 1968; **96**: 832-835.
3. Edis AJ, Schattenberg TT, Feldt RH, Danielson GK. Congenital coronary artery fistula; surgical considerations and results of operation. *Mayo Clin Proc* 1972; **47**: 567-571.
4. Rittenhouse EA, Doty DB, Ehrenhaft JL. Congenital coronary artery-cardiac chamber fistula; review of operative management. *Ann Thorac Surg* 1975; **20**: 468-485.
5. Effler DB, Sheldon WC, Turner JJ, Groves LK. Coronary arteriovenous fistulas; diagnosis and surgical management; report of fifteen cases. *Surgery* 1967; **61**: 41-50.
6. Chia BL, Chan ALK, Tan LKA, Ng RAL, Chiang SP. Coronary artery-left ventricular fistula. *Cardiology* 1981; **68**: 167-179.
7. Grant RT. Development of cardiac coronary vessels in the rabbit. *Heart* 1926; **13**: 261.
8. Gobel FL, Anderson CF, Baltaxe HA, Amplatz K, Wang Y. Shunts between the coronary and pulmonary arteries with normal origin of the coronary arteries. *Am J Cardiol* 1970; **25**: 655-661.
9. Anderson GP, Adicoff A, Motsay GJ, Sako Y, Gobel FL. Traumatic right coronary arterial-right atrial fistula. *Am J Cardiol* 1975; **35**: 439-443.
10. Austin SM, Applefeld MM, Turney SZ, Mech KF Jr. Traumatic left anterior descending coronary artery to right ventricle fistula; report of two cases. *South Med J* 1977; **70**: 581-584.
11. Alter BR, Wheeling JR, Martin HA, Murgio JP, Treasure RL, McGranahan GM Jr. Traumatic right coronary artery-right ventricular fistula with retained intramyocardial bullet. *Am J Cardiol* 1977; **40**: 815-819.
12. Ikäheimo MJ, Takkunen JT. Fistula from coronary artery to pulmonary artery after blunt trauma to chest. *Chest* 1978; **74**: 602-603.
13. Starling MR, Groves BM, Frost D, Toon R, Arom KV. Aorto-coronary vein fistula; a

- complication of coronary artery bypass graft surgery. *Chest* 1981; **79**: 64-68.
14. Vieweg WVR. Continuous murmur following bypass surgery. *Chest* 1981; **79**: 4-5.
  15. Cooley DA, Ellis PR Jr. Surgical considerations of coronary arterial fistula. *Am J Cardiol* 1962; **10**: 467-474.
  16. Pezzella AT, Falaschi G, Ott DA, Cooley DA. Congenital coronary artery-left heart fistulas; report of three cases. *Cardiovasc Dis* 1981; **8**: 355-363.
  17. deNef JJE, Varghese PJ, Losekoot G. Congenital coronary artery fistula; analysis of 17 cases. *Br Heart J* 1971; **33**: 857-862.
  18. Verani MS, Lauer RM. Echocardiographic findings in right coronary arterial-right ventricular fistula; report of a neonate with fatal congestive heart failure. *Am J Cardiol* 1975; **35**: 444-447.
  19. Neufeld HN, Lester RG, Adams P Jr, Anderson RC, Lillehei CW, Edwards JE. Congenital communication of a coronary artery with a cardiac chamber of the pulmonary trunk ("coronary artery fistula"). *Circulation* 1961; **24**: 171-179.
  20. Reeder GS, Tajik AJ, Smith HC. Visualization of coronary artery fistula by two-dimensional echocardiography. *Mayo Clin Proc* 1980; **55**: 185-189.
  21. Stansel HC Jr, Fenn JE. Coronary arteriovenous fistula between the left coronary artery and persistent left superior vena cava complicated by bacterial endocarditis. *Ann Surg* 1964; **160**: 292-296.
  22. Housman LB, Morse J, Litchford B, Stein R, Mazur J, Starr A. Left ventricular fistula as a cause of intractable angina pectoris; successful surgical repair. *JAMA* 1978; **240**: 372-374.
  23. Jaffe RB, Glancy DL, Epstein SE, Brown BG, Morrow AG. Coronary arterial-right heart fistulae; long-term observations in seven patients. *Circulation* 1973; **47**: 133-143.
  24. Nunn DB, Thrower WB, Boone JA, Lipton M. Coronary arteriovenous fistula simulating patent ductus arteriosus. *Am Surg* 1962; **28**: 476-482.
  25. Baim DS, Kline H, Silverman JF. Bilateral coronary artery-pulmonary artery fistulas; report of five cases and review of the literature. *Circulation* 1982; **65**: 810-815.