

Dermatology feature

Kenneth J. Tomecki, M.D.,
Section Editor

Ehlers-Danlos syndrome, type II (mitis)

Omar S. Salem, M.D.
Kenneth J. Tomecki, M.D.

Department of Dermatology

The type II (mitis) variant of Ehlers-Danlos syndrome (EDS) is an autosomal dominant disorder characterized by mild skin hyperextensibility, mild joint hypermobility, easy bruisability, and poor wound healing with formation of wide atrophic fish-mouthed scars following minor trauma. The course of the disease is benign and affected patients have a normal life expectancy. We report a family with type II EDS and include a review of this variant and an updated classification of EDS.

Case report

A 12-year-old girl presented to the Department of Dermatology at The Cleveland Clinic Foundation in January 1982, with a history of delayed wound healing, easy bruisability, and double-jointedness. She had frequent episodes of gingival bleeding after routine dental flossing, but denied any other unusual bleeding tendency. She was born three weeks prematurely, the product of an otherwise normal pregnancy and delivery. The remainder of her personal and familial history was unremarkable except for the known occurrence of double-jointedness in several members of the maternal side of the family.

Physical examination revealed several gaping, atrophic, "fish-mouthed" scars on the extensor surfaces of the upper and lower extremities (*Fig. 1*); hypermobility of several joints, particularly those of the hands and vertebral column (*Fig. 2*); mild hyperextensibility of the skin; marked stria formation on the breasts; and a few

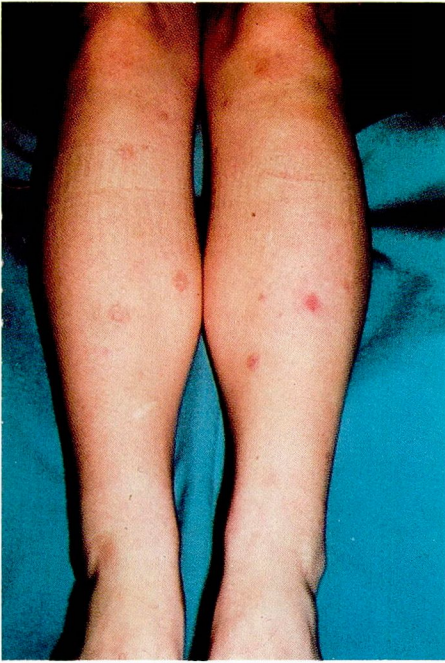

Fig. 1. Typical scarring of EDS, mild (patient).

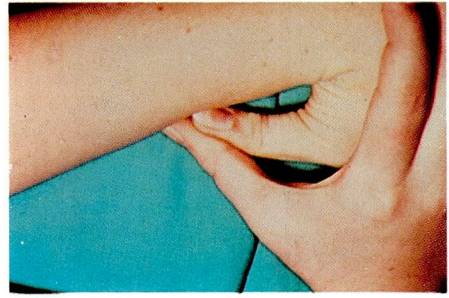


Fig. 2. Passive apposition of the thumb to the forearm (patient).

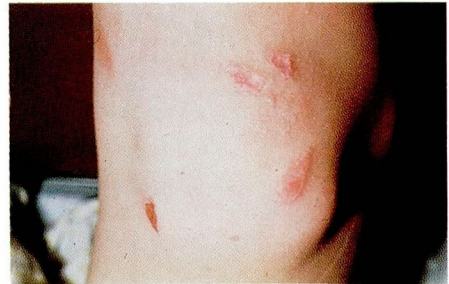

Fig. 3. Typical scarring of EDS, mild (brother of patient).

crusted papules on the nose and chin. Echinomoses were absent and the tongue was not hyperextensible (negative Gorlin's sign). Examination of the patient's mother revealed mild skin stretchability and moderate joint laxity. The patient's 10-year-old brother had several scars on the elbows and knees identical to those seen on the patient (Fig. 3); his skin was mildly hyperextensible and the joints of his hands were moderately lax. Results of physical examination of the father of the patient and a 15-year-old brother were normal.

The following laboratory data on the patient were either normal or negative: SMA-18 chemistry profile, complete blood count with differential, serologic test for syphilis, Westergren sedimentation rate, antinuclear antibody titer, urinalysis, and 24-hour urinary total porphyrin screen. Examination of skin biopsy specimens by routine histology and transmission electron microscopy from apparently normal skin was unremarkable.

Discussion

History, clinical appearance, and the apparent autosomal dominant mode of transmission supported the diagnosis of EDS, type II (mitis) in our patient. EDS is the prototype of the heritable disorders of connective tissue; other such disorders include Marfan's syndrome, osteochondrodysplasias, pseudoxanthoma elasticum, alkaptonuria, homocystinuria, Weil-Marchesani syndrome, cutis laxa, osteogenesis imperfecta, mucopolysaccharidoses, and Menke's syndrome.¹ Specific disturbances in collagen, elastin, and/or glycosaminoglycans occur in many of these disorders.

Although there are at least ten distinct clinical genetic variants of EDS (Table), more than 50% of patients with features of EDS cannot be adequately

Table. Clinical-genetic variants of Ehlers-Danlos syndrome*

Type	Mode of inheritance	Biochemical defect
I Gravis	Autosomal dominant	?
II Mitis	Autosomal dominant	?
III Benign hypermobile	Autosomal dominant	?
IV Ecchymotic or arterial	Autosomal dominant	Type III collagen deficiency
	Autosomal recessive	Type III collagen deficiency
V X-linked	X-linked recessive	? Lysyl oxidase deficiency
VI Ocular	Autosomal recessive	Lysyl hydroxylase deficiency
VII Multiple congenital dislocation	Autosomal recessive	Procollagen N-peptidase deficiency
	? Autosomal dominant	Structural mutation in procollagen I
VIII Periodontitis	Autosomal dominant	?
IX	X-linked recessive	Lysyl oxidase deficiency
X	Autosomal recessive	Fibronectin deficiency

* From Table 1 in Cupo et al,² by permission of the authors and publisher.

classified except as EDS type unspecified.^{1,2} Of the six EDS subtypes for which specific biochemical defects are known, five result from defective collagen synthesis and one from a deficiency of fibronectin (*Table*).

The classical clinical features of EDS include hyperextensible skin, a tendency to form gaping, atrophic, papyraceous scars after minor trauma, easy bruisability, and hypermobile joints. The severity of these changes varies with the different subtypes of the disease. Patients with type II EDS typically have mild disease activity. Subcutaneous spherules, molluscoid pseudotumors, and varicose veins occur infrequently in these patients. Musculoskeletal deformities are also rare, and when present are usually mild.³ Spontaneous perforation of the major arteries and of the gastrointestinal tract, ophthalmologic abnormalities, and periodontitis, hallmarks of types IV, VI, and VIII EDS respectively, rarely occur in the type II variant.⁴

Patients with type II EDS invariably exhibit subtle clinical changes, which often escape detection and accurate diagnosis, but the presence of these

changes in a person with similarly affected family members should suggest the diagnosis. Unfortunately, there are no specific laboratory data to support the diagnosis, and there is no known associated biochemical defect. Routine histologic examination of biopsy specimens from normal skin of affected individuals has not demonstrated any significant abnormalities.⁵ Ultrastructural examination of similar biopsy specimens has shown fraying of collagen fibrils with an impairment of their ability to aggregate into fibers.^{2,6,7} Such changes also occur in EDS types I, III, and V, and are thus not diagnostic for any particular type of the disease.

Although patients with EDS may seek evaluation from dermatologists and pediatricians, the syndrome certainly warrants the attention of other physicians. Unfortunately, there is no proved effective therapy for this group of diseases.

References

- Hollister DW. Heritable disorders of connective tissue; Ehlers-Danlos syndrome. *Pediatr Clin North Am* 1978;**25**: 575-592.
- Cupo LN, Pyeritz RE, Olson JL, McPhee SJ, Hutchins GM, McKusick VA. Ehlers-Danlos

- syndrome with abnormal collagen fibrils, sinus of Valsalva aneurysms, myocardial infarction, panacinar emphysema and cerebral heterotopias. *Am J Med* 1981; **71**: 1051-1058.
3. Beighton P. *The Ehlers-Danlos Syndrome*. London: William Heinemann Medical Books Limited, 1970.
 4. Sulica VI, Cooper PH, Pope FM, Hambrick GW Jr, Gerson BM, McKusick VA. Cutaneous histologic features in Ehlers-Danlos syndrome; study of 21 patients. *Arch Dermatol* 1979; **115**: 40-42.
 5. McKusick VA. *Heritable disorders of connective tissue*. 4th ed. St. Louis: CV Mosby, 1972.
 6. Black CM, Gathercole LJ, Bailey AJ, Beighton P. The Ehlers-Danlos syndrome; an analysis of the structure of the collagen fibres of the skin. *Br J Dermatol* 1980; **102**: 85-96.
 7. Sevenich M, Schultz-Ehrenburg U, Orfanos CE. Ehlers-Danlos syndrom; eine Fibroblasten- und Kollagenkrankheit. Typisierung und elektronenmikroskopische Befunde bei fünf Kranken. *Arch Dermatol Res* 1980; **267**: 237-251.