

TETRALOGY OF FALLOT

Report of a Case

H. SCOTT VAN ORDSTRAND, M.D.

Abbott¹ has classified congenital defects of the cardiovascular system in three principal groups: (1) the a-cyanotic group, (2) the group of cases in which there is an arteriovenous shunt with possible transient cyanosis due to reversal of flow through the defect, and (3) the cyanotic group (*morbus caeruleus*) in which cyanosis is permanently present.

The tetralogy of Fallot is the most common member of the cyanotic group. The tetrad consists of a defect of the ventricular septum, pulmonary or infundibular stenosis, dextroposition of the aorta, and hypertrophy of the right ventricle. The aorta arises from both ventricles above a large, smooth-walled defect in the upper part of the interventricular septum. Maude Abbott² found the average duration of life in 83 cases to be $12\frac{3}{4}$ years. White³ has reported a case in which the patient lived to the age of 59 years and 9 months.

REPORT OF CASE

The patient, a 15 year old boy, was admitted to the clinic on December 23, 1937, with the chief complaints of dyspnea on slight exertion, poor appetite, constipation, and abdominal pain. A blue baby at birth, he had always had a poor appetite and had taken a very inadequate diet. Since birth there had been dyspnea on slight exertion and cyanosis had been present constantly. In the 8 months before his admission, there had been several episodes of bleeding from the mouth and into the subcutaneous tissues, and for 2 weeks he had complained of pain in the lower part of the abdomen and increased constipation.

The general physical examination revealed a slender, undernourished boy with dusky bluish skin and deeply cyanotic mucous membranes. The tongue showed marked geographic ridging. The thorax was increased in the anteroposterior diameter and was somewhat pear-shaped with limited diaphragmatic excursion. The lungs were clear on percussion and auscultation. The area of relative cardiac dullness extended to the midclavicular line in the fifth intercostal space. The heart rhythm was regular and the rate 92 per minute. A palpable systolic thrill was present in the third left interspace adjacent to the sternum. The mitral first sound and the pulmonic second were accentuated. A harsh systolic murmur was present in the second and third left intercostal spaces adjacent to the sternum, and, in addition, a diastolic murmur was present over the pulmonary area when the patient was in the recumbent position only. The liver and spleen could not be felt. There was marked clubbing of the fingers and toes (Figs. 1 and 2), and slight pitting edema

TETRALOGY OF FALLOT

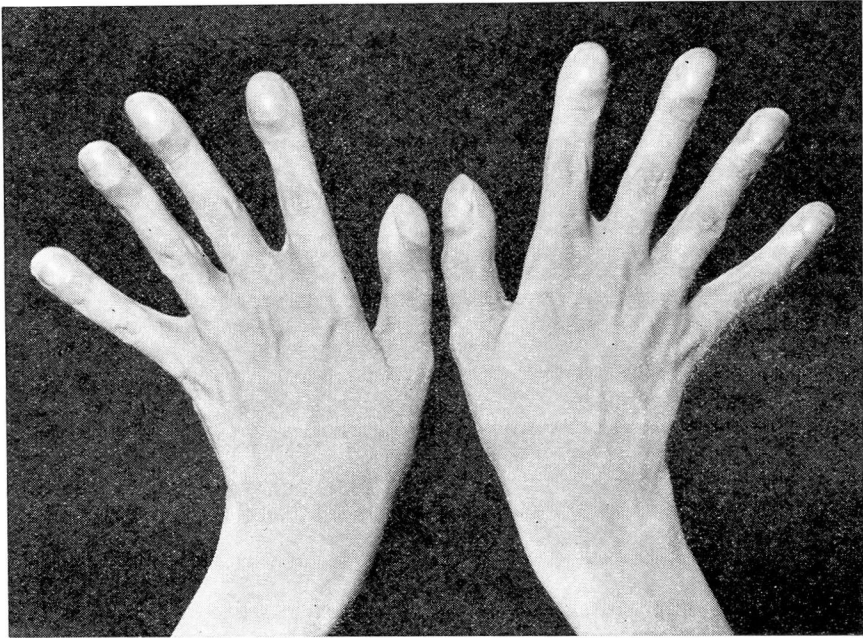


FIGURE 1: Photograph showing clubbing of fingers.

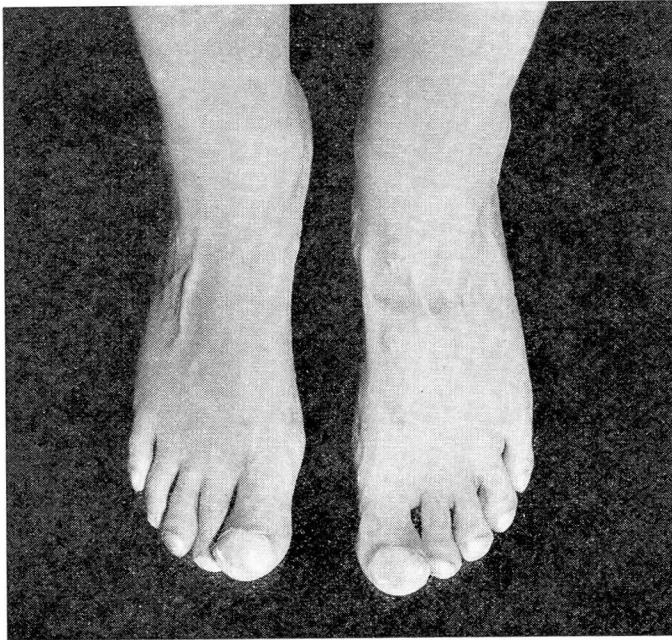


FIGURE 2: Photograph showing clubbing of toes.

H. SCOTT VAN ORDSTRAND

was present in the lower legs. A few petechiae were present about the umbilicus. A tourniquet test did not bring out additional petechiae.

Roentgenograms of the chest revealed a boot-shaped heart and increased hilar lung shadows. The electrocardiogram showed sinus tachycardia with a rate of 110 per minute. Right axis deviation was present. Roentgen examination of the colon gave normal findings.

The red blood cells numbered 7,750,000 per c.mm. The hemoglobin content was 136 per cent. The white blood cell count was 9,300 per c.mm. The bleeding and coagulation time and the platelet count were normal.

The urine had a specific gravity of 1.016 and contained four plus albumin. Microscopic examination revealed many hyaline and granular casts. The Wassermann and Kahn reactions of the blood were negative. The cevitamic acid content of the blood plasma was 0.129 mg. per 100 cc. (normal 0.9 mg.).

DISCUSSION

This case illustrates all the significant features of the cyanotic type of congenital heart disease. A high degree of cyanosis was present constantly and was due principally to the fact that the dextroposed aorta received blood from both the right and left ventricles. There was clubbing of the fingers and toes. Examination of the blood revealed an increase in the number of red blood cells and in the hemoglobin content. This represents an attempt on the part of the hematopoietic system to compensate for the deficient oxygenation of the tissues.

In view of the dietary history and the reduction in the cevitamic acid content of the blood plasma, it was concluded that the hemorrhagic manifestations were the result of deficiency disease, particularly of vitamin C. The abdominal distress was considered to be due to an irritable colon, the symptoms of which had been enhanced by the long continued use of irritating cathartics.

REFERENCES

1. Abbott, M. E. and Weiss, E.: The Diagnosis of Congenital Cardiac Disease, in "Blumer's Bedside Diagnosis," Philadelphia, W. B. Saunders Co., 2:353, 1928.
2. Abbott, M. E.: Atlas of Congenital Cardiac Disease, New York, The American Heart Association, 1936.
3. White, P. D.: Heart Disease, New York, MacMillan Co., 1931.