

RHINOPHYMA

Report of a Case

R. S. DINSMORE, M. D., AND K. W. KELLER, M. D.

Occasionally, a marked hypertrophy of the nasal tissues and enlargement of the sebaceous glands develop in patients with acne rosacea, resulting in a large, bulbous nose. To this condition, the name rhinophyma is applied. The nasal enlargement may appear simultaneously with the onset of acne rosacea but more frequently it develops several years later. Involvement of areas other than the nose is rarely seen, although Sams¹ reports a case with marked tumefaction of the chin, and mentions several cases where tissues adjacent to the nose were involved. Rhinophyma rarely occurs in women. All six cases treated at the Cleveland Clinic since 1930 have occurred in men.

A specific etiological factor for the parent disease, acne rosacea, has not been definitely discovered. Among the contributing causes have been mentioned excessive use of alcohol, liver disease, constipation, folliculitis of the face, exposure, substitution of cleansing creams for soap and water, and focal infection².

Ayres and Anderson³ reported 77 cases of acne rosacea and pityriasis folliculorum in which large numbers of *Demodex folliculorum* were found in the pustules. There was a marked reduction in the number of parasites and remarkable improvement or cure following the application of an antiparasitic ointment. They believe they have discovered a significant etiological factor for acne rosacea.

The following case illustrates a typical rhinophyma and a type of treatment which, in our experience, has given a very satisfactory result.

REPORT OF CASE

The patient was a white, single man, 41 years of age, who came under observation in December, 1937, with the complaints of an acne-like eruption on the face and marked enlargement of the nose. Fifteen years prior to admission there appeared on his face a moderate erythema with superimposed papules and pustules. The nose, which was also involved in this eruption, began to enlarge slowly until, at the time of our examination, it was four or five times the normal size, most of the enlargement having occurred during the preceding three years. The eruption had persisted unabated throughout this period, and there were many pitted scars on the cheeks, forehead, nose, and chin. There was no pain, tenderness, or pruritus. Enlargement of the nose did not interfere with nasal breathing.

The past and family histories disclosed nothing of significance. There was no history of the ingestion of iodides, bromides, patent medicines,

or excessive amounts of alcohol or tobacco. No symptoms referable to the gastro-intestinal tract had been experienced.

Examination revealed a well-developed and nourished man without abnormal physical findings, except for the condition of the nose

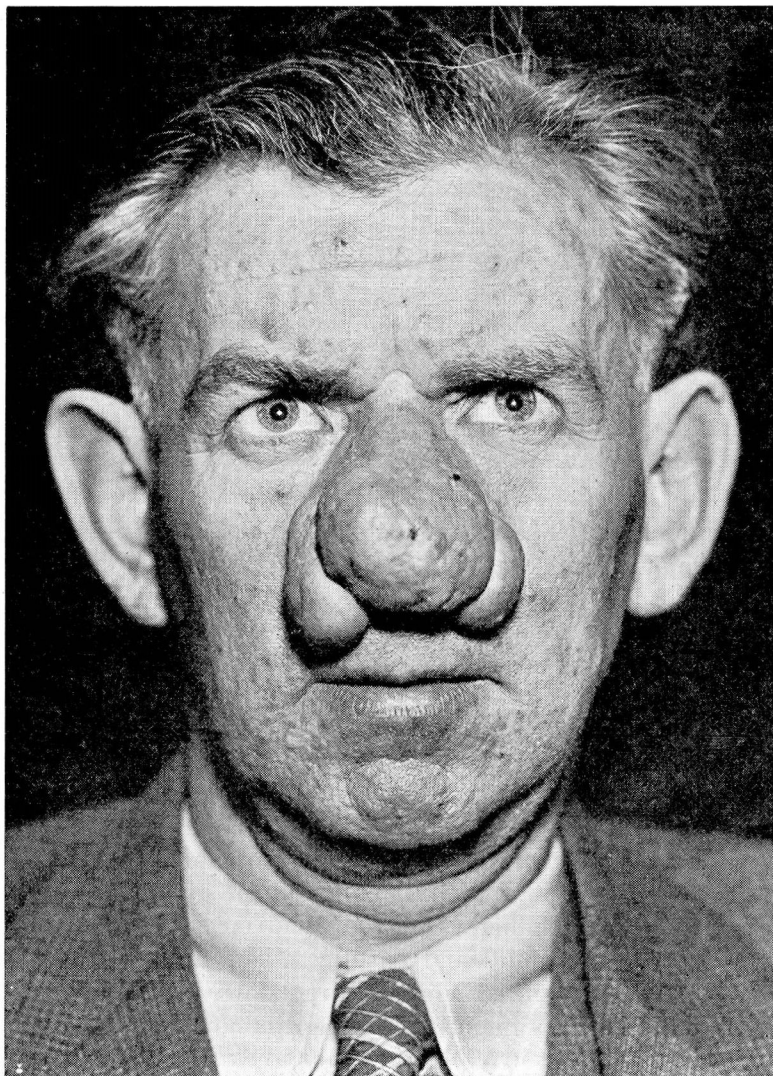


FIGURE 1: Photograph of patient before operation.

(Fig. 1). Many papules, small pustules, and pitted scars were concentrated on the forehead, nose, and adjacent parts of the cheeks and chin. A few comedones were found on the forehead and there were a great many patulous, sebaceous follicles and telangiectases over the entire face.

RHINOPHYMA

The beard was involved by a moderate folliculitis. The nose in aggregate was the size of a small lemon and consisted of a large central lobe and a smaller lateral lobe on each side.

Examination of the urine and blood, including complete blood counts and estimation of the level of the blood sugar, and an Ewald test meal




FIGURE 2: Photograph of patient after operation.

gave normal findings. The Wassermann reaction of the blood was negative. Examination of sebum from the enlarged sebaceous glands revealed many *Demodex folliculorum*.

The patient was admitted to the hospital for surgical removal of the rhinophyma. Local treatments to ameliorate the folliculitis were given before operation.

Because of its unusual size, only the left half of the growth was removed at the first operation. Under avertin and gas-oxygen anesthesia, several straight cutting needles were inserted parallel to the left nostril from the proximal end of the swelling distally to the normal tip of the nose. The needles delineated the outline of a normal nose. The lobule on the left side was excised, leaving the normal ala intact. The left half of the central mass was then excised down to the needles, leaving this half of the nose essentially normal in size and contour. Bleeding was controlled by pressure bandages.

The postoperative care consisted of dry heat administered several times daily and removal of all crusts which hindered smooth epithelialization. Ten days after the first stage of the operation, the right half was removed in a similar manner. The patient made an uneventful recovery from both procedures (Fig. 2).

There are several methods of treating rhinophyma, but the above procedure of simply excising the excess tissue has given a very satisfactory result.

Microscopic sections show numerous deeply penetrating ducts lined by epithelium from which new islands of skin arise. The denuded area is covered with surprising rapidity by epithelium which in color and texture is nearly identical with the normal skin of the nose, a result which is impossible to obtain by the use of skin grafts.

Microscopically, sections of the skin and underlying tissue showed slight thickening and keratosis of the surface epithelium, considerable diffuse edema and chronic inflammation of the underlying stroma, numerous large sebaceous glands extending deeply into the underlying tissues, and several small cysts lined by keratotic squamous epithelium similar to that on the surface.

REFERENCES

1. Sams, Wiley M.: Rhinophyma with unusual involvement of the chin, *Arch. Dermat. & Syph.*, 26:834-838, (November) 1932.
2. Ormsby, O. S.: *Diseases of the Skin*, Lea & Febiger, Philadelphia, 1193-1199, 1937.
3. Ayres, S., Jr. and Anderson, N. P.: Acne Rosacea; Response to local treatment for *Demodex folliculorum*, *J.A.M.A.*, 100:645-647, (March 4) 1933.