

# Necrobiotic granuloma formation at a collagen implant treatment site<sup>1</sup>

Javier Ruiz-Esparza, M.D.  
Mary Bailin, R.N.  
Philip L. Bailin, M.D.

**Collagen implantation in a patient for correction of facial wrinkles eventually resulted in necrobiotic granulomas at the treatment site which eventually resolved. Reaction at the test site had been negative.**

**Index terms:** Collagen, implantation • Skin  
**Cleve Clin Q** 50:163–165, Summer 1983

Highly purified bovine dermal collagen (Zyderm) is being used for soft tissue augmentation to correct contour defects of various etiologies. Although the incidence of side effects is extremely low, two reports in the literature have described granuloma formation at the site of test injections. We report a case of a patient who had a negative test site reaction, but then developed necrobiotic granulomas of a transient nature at the treatment site while the test site remained negative.

## Case report

A 59-year-old white woman was seen for correction of facial furrows and wrinkles. There were no contraindications to collagen implantation such as personal or family history of connective tissue diseases, history of allergic reactions to medications, or history of silicone injections.

On physical examination she had rhytides in her glabellar skin, upper lip, cheeks, and chin that were distensible and judged amenable to correction by Zyderm injection. A test injection consisting of 0.1 cc of Zyderm was applied intradermally to her left forearm. The patient returned a month later with a history of no reaction locally nor systemically. Inspection and palpation failed to reveal any induration at the test site. She then received 1 cc of Zyderm for corrective purposes to the rhytides of the perioral skin (Fig. 1). No immediate reaction occurred. A few weeks later, localized

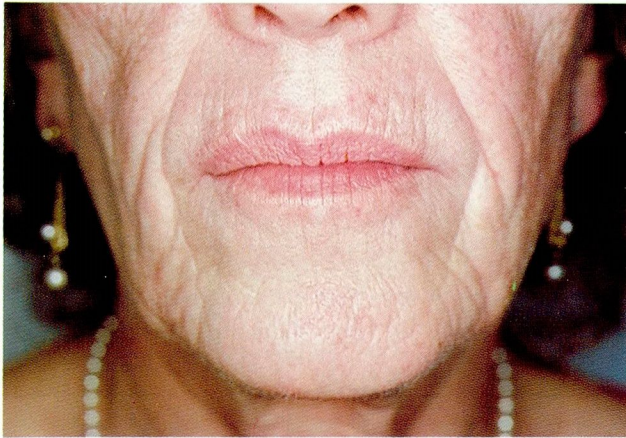
swelling of the injected skin was noticed (Fig. 2). No signs of reaction were present at the forearm test site. The patient denied any alcohol intake or excessive sun exposure. Cold compresses were recommended, and the patient was sent home without any further injections. Erythema and induration persisted for the following 10 weeks. A biopsy specimen was obtained from one of the nodules 12 weeks after injection (Fig. 3). Histopathologic examination revealed several granulomas in the reticular dermis. They demonstrated central eosinophilic necrobiosis and a peripheral palisading of histiocytes. Numerous giant cells and abundant plump epithelioid cells surrounded the granulomas. A dense lymphohistiocytic infiltrate was present in the adjacent dermis. The epidermis and epidermal appendages were unremarkable. Periodic acid-Schiff, Gomori methenamine-silver nitrate, and acid-fast stains were negative for organisms. When the patient was seen again five and a half months after the treatment injection, the nodules had essentially resolved (Fig. 4).

## Comment

Zyderm is a sterile material composed of highly purified bovine dermal collagen which is injected intradermally for restitution of lost substance from scars,<sup>1,2</sup> rhytides, postrhinoplasty irregularities, glabellar frown lines, depressed skin grafts, etc. The incidence of adverse reactions has been 1.3% among 5109 treated patients, and includes localized erythema, swelling, induration and/or urticaria (Physician Package Insert, Collagen Corporation, Palo Alto, California, May 1982). Also, four cases of herpes simplex eruptions at implantation sites occurred in patients who had been affected previously.

Recently, 2 reports have appeared in the literature describing granuloma formation after Zyderm injection for test purposes.<sup>3,4</sup> Necrobiosis in the granulomas was observed histologically in one case.<sup>4</sup> The other case was interpreted as a foreign-body granuloma.<sup>3</sup>

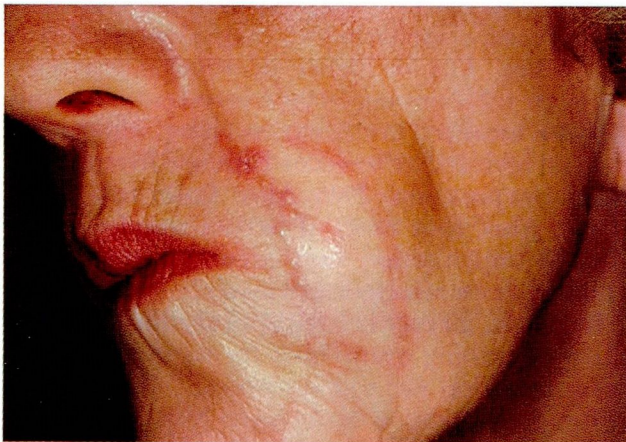<sup>1</sup> Department of Dermatology, The Cleveland Clinic Foundation. Submitted for publication Feb. 1983; accepted March 1983.



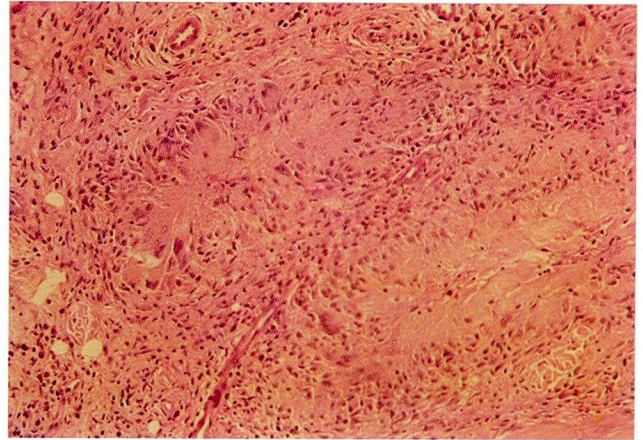
**Figure 1.** Perioral area prior to Zyderm injections.

Necrobiotic granulomas developed in our patient in the perioral furrows and wrinkles injected with Zyderm, and persisted for six months before disappearing spontaneously. The test site remained negative throughout. This type of reaction has not been reported to the best of our knowledge. The Zyderm Physician's Reference Guide (Collagen Corporation) states under Adverse Treatment Responses that of 2869 patients "two experienced probable Zyderm collagen sensitization manifested by localized swelling or redness at treatment sites following a response-free test implantation. Both of these reactions resolved spontaneously within two weeks." The histology is not described. Our patient's reaction persisted six months but may represent the same phenomenon. The patient responded with a granulomatous reaction only at the treatment sites while the test site remained negative.

The lack of reaction at the test site presents an interesting problem in interpretation. It is possi-

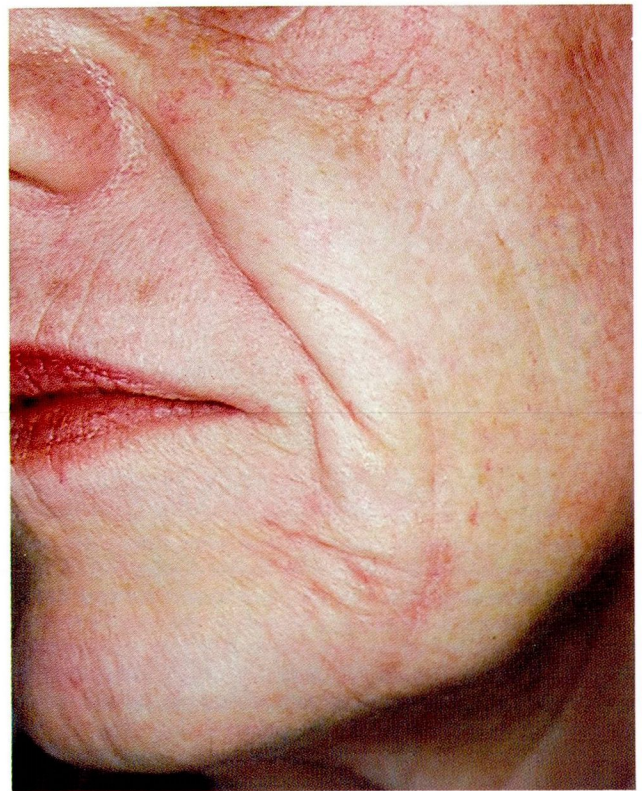


**Figure 2.** Three months after Zyderm injections, photograph shows raised erythematous papules at the injected sites.



**Figure 3.** Photomicrograph of the deep dermis showing granulomas with peripheral palisading of histiocytes and central foci of necrobiosis.

ble that the test injection may produce an allergic sensitization that is manifested only on the second exposure. Perhaps the test site collagen was already "incorporated" in the host tissues and was therefore not recognized as "foreign" when the treatment injections were given. Reportedly, immunofluorescent staining with antibody to bo-



**Figure 4.** Five months after allergic response with total resolution of lesions.

vine collagen indicates disappearance of implanted material by six weeks (Karen Burke, M.D., personal communication).

It is also possible that the substratum of host collagen was different in the volar forearm and in the face, and that chronically sun-exposed collagen responds differently when combined with the collagen implant.<sup>5</sup>

Lastly, the possibility that the collagen contained in the test injection and in the treatment injection were antigenically different, although highly unlikely, cannot be absolutely excluded.

The incidence of adverse reactions to Zyderm remains low in our experience and matches that of the manufacturer's series. It is the purpose of this paper to document the occurrence of this granulomatous reaction phenomenon for the

awareness of the clinician involved in the therapeutic use of Zyderm.

### References

1. Bailin PL, Bailin M. Correction of depressed scars following MOHS' surgery: The role of collagen implantation. *J Dermatol Surg Oncol* 1982; **8**:845-849.
2. Stegman SJ, Tromovich TA. Implantation of collagen for depressed scars. *J Dermatol Surg Oncol* 1980; **6**:450-453.
3. Brooks N. A foreign body granuloma produced by an injectable collagen implant at test site. *J Dermatol Surg Oncol* 1982; **8**:111-114.
4. Barr RJ, King DF, McDonald RM, Bartlow GA. Necrobiotic granulomas associated with bovine collagen test site injections. *J Am Acad Dermatol* 1982; **6**:867-869.
5. Hanke CW, Bailin PL, Roenigk HH Jr. Annular elastolytic giant cell granuloma; a clinicopathologic study of five cases and a review of similar entities. *J Am Acad Dermatol* 1979; **1**:413-421.