

Mixed connective tissue disease in identical twins

A sclerodermoid variant with concurrent psoriasis¹

L. Stephen Kish, M.D.
Willard D. Steck, M.D.

Identical twin sisters were seen with sclerodermoid mixed connective tissue disease (MCTD). This is the first report to our knowledge of either scleroderma or MCTD in twins. In addition, both women had psoriasis localized to the scalp.

Index terms: Skin, diseases • Twins
Cleve Clin Q 50:205–207, Summer 1983

Mixed connective tissue disease (MCTD) is a multisystem, autoimmune disorder of unknown etiology, which may resemble rheumatoid arthritis, systemic lupus erythematosus (SLE), dermatomyositis, or progressive systemic sclerosis. Characteristically, MCTD has overlapping features of two or even three connective tissue diseases. Common presenting features include arthritis, Raynaud's phenomenon, myositis, abnormal esophageal mobility, swollen hands, and lymphadenopathy.¹ The distinguishing marker for this disease is serum antibody-specific for nuclear riboprotein, a ribonuclease-sensitive component of extractable nuclear antigen. In addition, most patients with MCTD have high serum titers of antinuclear antibody (speckled pattern), and high titers of rheumatoid factor are present in up to 50%.²

This report describes MCTD in identical twin sisters. Although multiple cases of MCTD in one family have been reported,^{3,4} this is the first

report of the disease in twins. Both women also had psoriasis of the scalp.

Case reports

Case 1. A 52-year-old white woman with a history of essential hypertension, hypothyroidism, and mild mitral regurgitation secondary to childhood rheumatic fever was relatively well while taking methyldopa, digoxin, and levothyroxine until 1975 when she noted the onset of slowly progressive dyspnea, dysphagia, fatigue, generalized arthralgia, and Raynaud's phenomenon. A treatment program of hydroxychloroquine, 100 mg, twice a day, and prednisone, 40 mg, every morning, for several months along with her previous regimen gave little relief.

The patient was first seen at the Cleveland Clinic in August 1979. Physical examination revealed a middle-aged woman with slightly drawn facial lines, shiny and taut skin over the fingers, periungual telangiectasia, and digital calcinosis cutis. The remainder of the physical findings were unremarkable (*Figs. 1 and 2*).

Results of laboratory studies including complete blood count and differential SMA-18 chemistry profile, urinalysis, and serologic test for syphilis were normal or negative. The Westergren erythrocyte sedimentation rate was 38 mm/hr (normal, <20 mm/hr), antinuclear antibody test was positive at 1:2560 with speckled pattern, rheumatoid factor was positive at 1:40, and the extractable nuclear antigen test was positive (>1:100,000). Complement levels (C₃, C₄, and CH50) were normal. The lupus erythematosus (LE) band test was negative. A cine esophagram showed decreased peristalsis, and pulmonary carbon monoxide diffusion was 12.7 (68%) of predicted.

Microscopic examination of skin taken from the dorsal aspect of the left hand showed marked thickening of the subepidermal collagen as well as replacement of subcutaneous fat with dermal connective tissue. Adnexal structures were diminished in number. Direct immunofluorescence was negative for immunoglobulins, complement, and fibrin.

Based on these results, a diagnosis of sclerodermoid

¹ Department of Dermatology, The Cleveland Clinic Foundation. Submitted for publication Feb 1983; accepted March 1983.

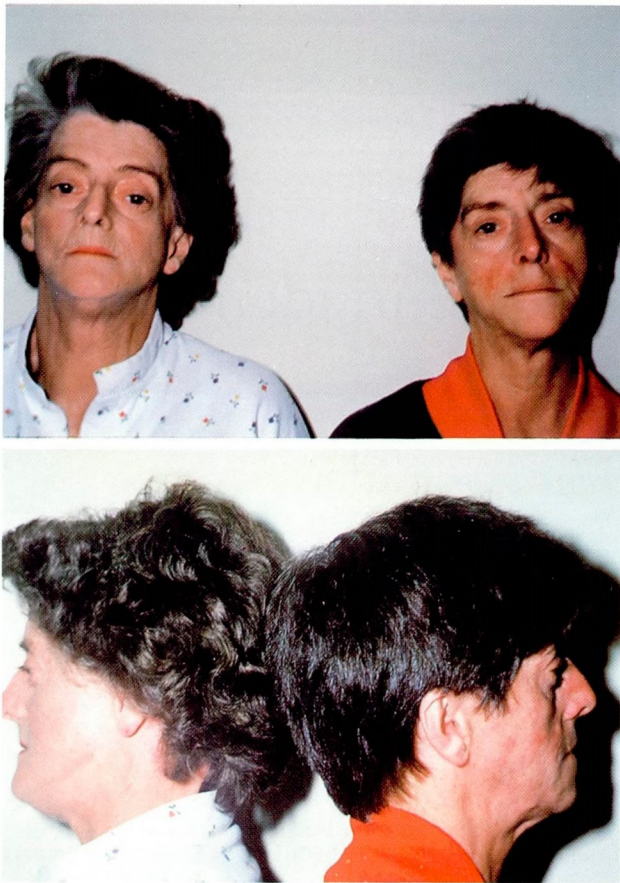

Figure 1. Identical twin sisters with sclerodermoid features of the face (patient 1, right; patient 2, left; frontal view).

Figure 2. Twin sisters in profile, patient 1 (right) has patchy telangiectasia of malar area.

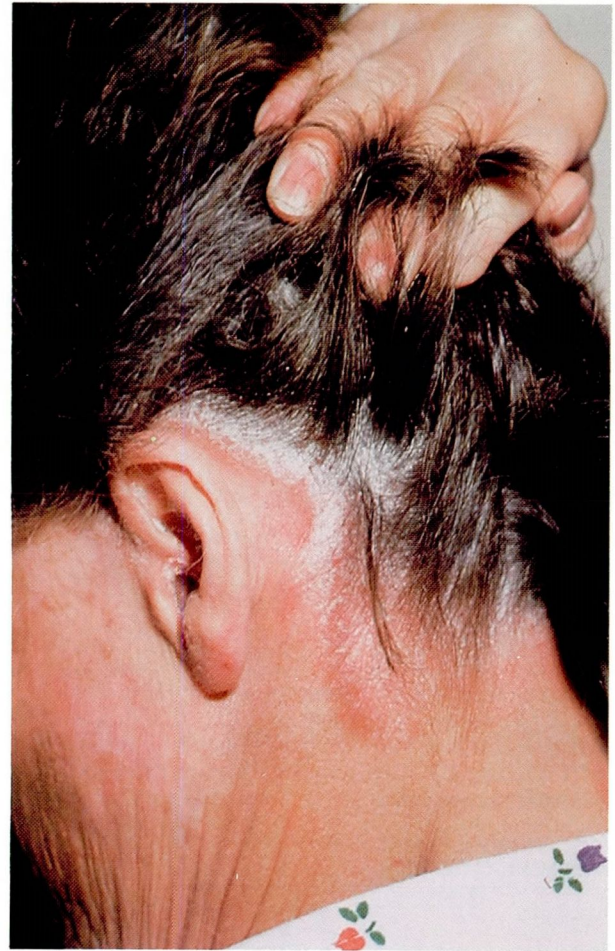


Figure 3. Scaling, erythematous plaque on occipital scalp, patient 2.

MCTD was made. The patient had been examined periodically by the Rheumatology Department of the Cleveland Clinic. The patient has had both subjective and objective improvement evidenced by softening of the skin and improved pulmonary function tests. Penicillamine, 750 mg/day, was added to the prednisone-hydroxychloroquine regimen soon after the initial evaluation. Prednisone was, thereafter, slowly tapered to the present dose of 2.5 mg/day.

In May 1981, the patient was referred to the Dermatology Department of the Cleveland Clinic for evaluation and treatment of an itchy scalp. Examination of the scalp revealed an irregular, large, scaly, erythematous plaque located occipitally and suboccipitally. The skin and nails were free of psoriasiform changes and, aside from the sclerodermoid findings previously noted, the only skin change of importance was fine telangiectasia over the nose, chin, and malar areas of the face. A biopsy specimen of the occipital scalp showed acanthosis, parakeratotic hyperkeratosis, diminution of the stratum granulosum epidermidis, and elongation of the dermal papillae. Diagnoses of psoriasis and acne rosacea were made, and the patient has had a good response to standard therapies.

Case 2. In July 1982, the identical twin sister of patient 1 accompanied her for a follow-up dermatology appointment. Psoriasiform and sclerodermoid changes nearly iden-

tical to those of her sister were noted (*Figs. 3 and 4*). Review of the medical records of patient 2 from the National Institutes of Health revealed that she had been relatively well and without medical problems (except for quiescent

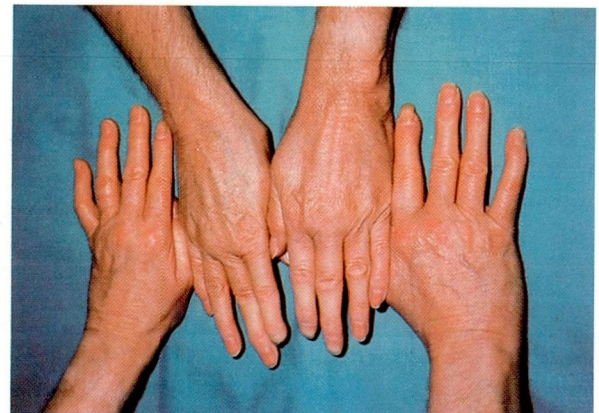


Figure 4. View of hands showing shiny and taut skin over the fingers and periungual telangiectasia (patient 1, middle; patient 2, outside).

pulmonary tuberculosis) until December 1952, when intermittent, then continuous fever, distal paresthesias and numbness, myalgia, arthralgia, and malaise developed, and she lost 26 pounds.

Physical examination at that time was unremarkable except for some mild edema of the eyelids, lower legs, and ankles. Numerous LE cell preparations were negative, but a muscle biopsy showed myositis with arteriolitis. A diagnosis of disseminated subacute LE was made, cortisone was begun, and she improved dramatically. The cortisone was tapered and finally discontinued in 1956.

In 1957, she experienced increasing difficulty swallowing food, inability to open her mouth fully, tightness of the skin of her fingers, and arthralgia. She was admitted to the National Institutes of Health. Physical examination revealed "bound-down" skin of the face and fingers, slight telangiectasia over the nose, limitation on opening the mouth, and bilateral Dupuytren's contractures. Laboratory data were remarkable for a Westergren erythrocyte sedimentation rate of 50 mm/hr and white blood cell count of 3,600,000/mm³. An upper gastrointestinal roentgenogram showed "stenosing esophagitis compatible with scleroderma." A roentgenogram of the hands showed multiple calcific deposits especially around the proximal interphalangeal joints as well as slight destruction of bone over the distal shafts. The diagnosis of scleroderma was made, and the patient was again treated with systemic corticosteroids.

During the following 10 years, in spite of intermittent treatment with corticosteroids, the patient's symptoms progressed to include morning stiffness, Raynaud's phenomenon, parotid swelling, and dry mouth. She was readmitted to the National Institutes of Health in 1962, when a diagnosis of Sjogren's syndrome was made and, again in 1964, for a sclerodermatous ulcer of the finger.

The patient has been maintained with intermittent corticosteroids as the principal therapy for the last 20 years. Recurrent digital ulceration has not been a problem since 1978 when colchicine, 0.6 mg, twice a day, was added to her regimen of prednisone, 5 mg/day.

Comment

This is the first report of MCTD in identical twins. The signs, symptoms, and serologic findings in patient 1 are characteristic of MCTD, and although serology was not obtained in patient 2, her history is also diagnostic with features of several connective tissue diseases, those of systemic scleroderma predominating.

Familial aggregations of autoimmune disease are common in the medical literature. The strong genetic component in the pathogenesis of SLE is emphasized by the review by Block et al⁵ of 29 cases of SLE in twins. Case reports of familial scleroderma (localized and systemic) have been

recently reported⁶⁻¹²; however, neither localized scleroderma nor progressive systemic sclerosis has ever been reported in twins. Only a few kindreds of two or more members having MCTD have been reported, and no twins have been affected.^{3,4} Thus, the twin sisters described in this paper are unique in the literature. Although, the occurrence of both morphea and progressive systemic sclerosis with psoriasis has been described previously,^{13,14} the coexistence of MCTD and psoriasis has not been reported.

References

1. Sharp GC, Irvin WS, Tan EM, Gould RG, Holman HR. Mixed connective tissue disease—an apparently distinct rheumatic disease syndrome associated with a specific antibody to an extractable nuclear antigen (ENA). *Am J Med* 1972; **52**:148-159.
2. Black C. Mixed connective tissue disease. *Br J Dermatol* 1981; **104**:713-719.
3. Horn JR, Kapur JJ, Walker SE. Mixed connective tissue disease in siblings. *Arthritis Rheum* 1978; **21**:709-714.
4. Ramos-Niembro F, Alarcon-Segovia D. Familial aspects of mixed connective tissue disease (MCTD). I. Occurrence of systemic lupus erythematosus in another member in two families and aggregation of MCTD in another family. *J Rheumatol* 1978; **5**:433-440.
5. Block SR, Winfield JB, Lockshin MD, D'Angelo WA, Christian CL. Studies of twins with systemic lupus erythematosus; a review of the literature and presentation of 12 additional sets. *Am J Med* 1975; **59**:533-552.
6. Wuthrich RC, Roenigk HH Jr, Steck WD. Localized scleroderma. *Arch Dermatol* 1975; **111**:98-100.
7. Sheldon WB, Lurie DP, Maricq HR, et al. Three siblings with scleroderma (systemic sclerosis) and two with Raynaud's phenomenon from a single kindred. *Arthritis Rheum* 1981; **24**:668-676.
8. Gray RG, Altman RD. Progressive systemic sclerosis in a family. *Arthritis Rheum* 1977; **20**:35-41.
9. Rendall JR, McKenzie AW. Familial scleroderma. *Br J Dermatol* 1974; **91**:517-522.
10. Greger RE. Familial progressive systemic scleroderma. *Arch Dermatol* 1975; **111**:81-85.
11. Strosberg JM, Peck B, Harris ED Jr. Scleroderma with intestinal involvement; fatal in two of a kindred. *J Rheumatol* 1977; **4**:46-52.
12. Mund DJ, Greenwald RA. The CREST syndrome variant of scleroderma in a mother-daughter pair. *J Rheumatol* 1978; **5**:307-310.
13. Burns DA, Sarkany I. Generalized morphea with bullous lesions and psoriasis. *Br J Dermatol* 1976; **95**(Suppl 14):33-34.
14. Sauter LS. Systemic scleroderma (progressive systemic sclerosis), chemical diabetes mellitus, psoriasis. *Arch Dermatol* 1971; **103**:682-685.