

(Cleve Clin Q 17:34-37, 1950)

BERYLLIUM SKIN GRANULOMAS FROM A BROKEN FLUORESCENT TUBE

Report of a Case

H. S. VAN ORDSTRAND, M.D., E. W. NETHERTON, M.D.
JOSEPH M. DE NARDI, M.D.* and MORRIS G. CARMODY, M.D.**

Departments of Cardiorespiratory Disease and Dermatology

AS there are a large number of beryllium phosphor fluorescent lamp tubes still in use it is important to recognize and, if possible, prevent the specific chronic skin granuloma which can result from lacerations sustained in breaking these tubes. As in the previously reported cases of Grier,¹ Coakley,² Nichol,³ and their co-workers, the following instance resulted from cuts inflicted by a fluorescent lamp tube in which the phosphor was a compound of zinc beryllium silicate, manganese and small amounts of finely divided and dispersed mercury. We have been informed that the fluorescent industry has ceased production of the beryllium containing phosphor.

Van Ordstrand et al.^{4,5} have reported a rather extensive series of dermal lesions of different character occurring in workers extracting beryllium compounds from the ore. We are impressed in this case with the similarity of the microscopic picture of granuloma following fluorescent tube cuts to that observed at necropsy in our cases of chronic pulmonary granulomatosis⁶ in persons exposed to beryllium and/or its compounds.

Case Report

A white man, aged 29, was seen on May 13, 1948, because of relatively painless lesions on the thumb, index and middle finger of his left hand. He stated that these were the sequelae of lacerations from a fluorescent tube which had exploded in his hand without apparent cause 6 months previously. He described the original wounds as having healed by primary intention without sutures. However, they were followed in several weeks by the local unsightly "overgrowth" of tissue resembling small tumors at the site of previous injury. The size of the lesions had attained a static level when seen. He had obtained several professional opinions on keloid reaction and had received a course of x-ray treatment without alteration in the lesions.

The physical examination proved essentially normal except for the skin lesions on his fingers as shown in the photograph (fig. 1a). The attendant laboratory studies (which included blood counts, urinalysis, blood sugar, sedimentation rate and blood serology) were all negative or within normal limits as was an x-ray examination of his chest.

Particularly because of this history of antecedent fluorescent tube injury a tentative

* Lorain, Ohio

**Painesville, Ohio

BERYLLIUM SKIN GRANULOMAS

diagnosis of chronic beryllium skin granuloma was made. The lesions on the dorsum of the middle finger and on the index finger were excised on May 18, 1948.

The third lesion (on thumb) has not been excised as the patient desires to observe the ultimate scientific outcome. In nearly 1½ years' observation by us the lesion has remained unchanged. Neither of the two excised areas has shown signs of recurrence after a similar lapse of time (fig. 1b).

Pathology

In the opinion of the pathologist,⁷ the granulomatous reaction was identical to that observed in chronic pulmonary granulomatosis in beryllium workers, and compatible with the effects of beryllium phosphor. Two other authorities^{8,9} reviewed the histopathology and concurred in this opinion.

The pathologic diagnosis was interpreted as follows:

GRANULOMA, SKIN. Consistent with beryllium granuloma (fig. 2).

Gross: The specimen consists of an ellipse of skin, 2.5 x 1.0 x 0.5 cm., the central portion of which is slightly and irregularly raised and finely nodular. The surrounding skin is unusually hard. On section, the corium beneath the altered epithelium is replaced by firm, almost homogeneous gray tissue.

Microscopic: The corium throughout the thin lining of the specimen reveals frequent focal accumulations of histiocytes, of epithelioid type and in

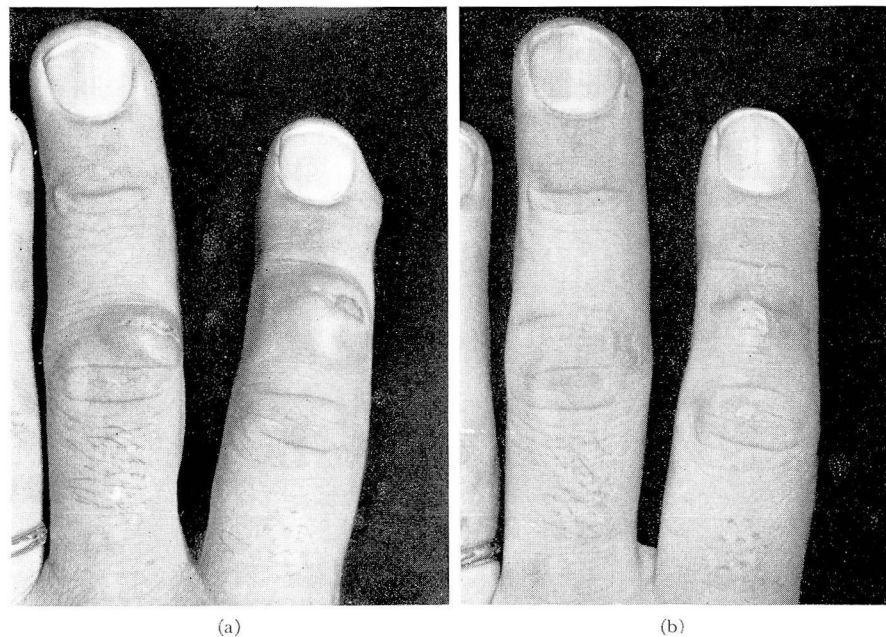


Fig. 1. (a) Gross appearance of granulomata prior to surgical excision. (b) Fingers of patient showing no granulomatous recurrence 1½ years after excision of lesions. The third and unremoved granuloma exhibits no change.

(Cleve Clin Q 17:34-37, 1950)

H. S. VAN ORDSTRAND ET AL.

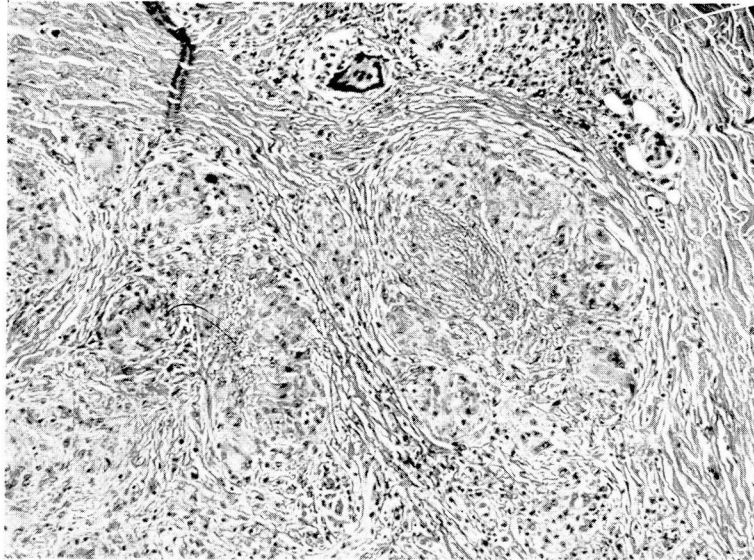


FIG. 2. Histopathology of one of excised skin lesions showing typical granulomatous changes in the corium.

these foci occasional rather large giant cells of foreign body type. In addition to these tubercle-like lesions there are several broad patches of necrosis with fibrinoid material present. A moderate number of lymphocytes are present about some tubercles.

Comment

In a patient presenting “keloid-like” lesions following old fluorescent lamp tube cuts the possibility of beryllium granuloma should be considered. These lesions might possibly be circumvented with early and complete debridement of the accompanying lacerations. Of utmost importance is the prevention of lacerations from careless handling of old fluorescent lamp tubes, inasmuch as a considerable number of tubes manufactured with beryllium phosphor remain in use or in stock.

Summary

1. Chronic beryllium skin granuloma can follow laceration from a fluorescent lamp tube manufactured with beryllium phosphor.
2. The histopathologic diagnosis of lesions in the case presented is similar to that of chronic pulmonary granulomatosis observed in persons exposed to beryllium and/or its compounds.
3. Observations on this specific traumatic beryllium granuloma indicate that it does not have migratory properties and is cured by local surgical excision.

(Cleve Clin Q 17:34-37, 1950)

BERYLLIUM SKIN GRANULOMAS

4. It is possible that similar lesions might be prevented by thorough cleansing and debridement at the time of the laceration.

5. Prevention of fluorescent lamp tube cuts is extremely important as old tubes containing beryllium phosphor are still in use and considerable stock remains. We are informed that the fluorescent industry has discontinued the manufacture of tubes with beryllium phosphor.

References

1. Grier, R. S., Nash, P., and Freiman, D. G.: Skin lesions in persons exposed to beryllium compounds. *J. Indust. Hyg. and Toxicol.* **30**:228 (July) 1948.
2. Coakley, W. A., Shapiro, R. N., and Robertson, G. W.: Granuloma at site of injury by fluorescent bulb. *J.A.M.A.* **139**:1147 (April 23) 1949.
3. Nichol, A. D., and Dominguez, R.: Cutaneous granuloma from accidental contamination with beryllium phosphors. *J.A.M.A.* **140**:855 (July 9) 1949.
4. Van Ordstrand, H. S., Hughes, C. R., De Nardi, J. M., and Carmody, M. G.: Beryllium poisoning. *J.A.M.A.* **129**:1084 (Dec. 15) 1945.
5. De Nardi, J. M., Van Ordstrand, H. S., and Carmody, M. G.: Acute dermatitis and pneumonitis in beryllium workers. *Ohio State M. J.* **45**:567 (June) 1949.
6. De Nardi, J. M., Van Ordstrand, H. S., and Carmody, M. G.: Chronic pulmonary granulomatosis. *Am. J. Med.* **7**:345 (Sept.) 1949.

Acknowledgments

7. Dr. John B. Hazard, Pathologist, Cleveland Clinic Foundation.
8. Dr. Frank Dutra, Kettering Laboratories, University of Cincinnati, personal communication to the authors.
9. Dr. Arthur J. Vorwald, Director, The Edward L. Trudeau Foundation, Saranac Lake, New York.

(Cleve Clin Q 17:34-37, 1950)