

# Hypoplastic left heart syndrome: medical management and practical surgical palliation<sup>1</sup>

Carl C. Gill, M.D.  
Douglas S. Moodie, M.D.  
Richard Sterba, M.D.

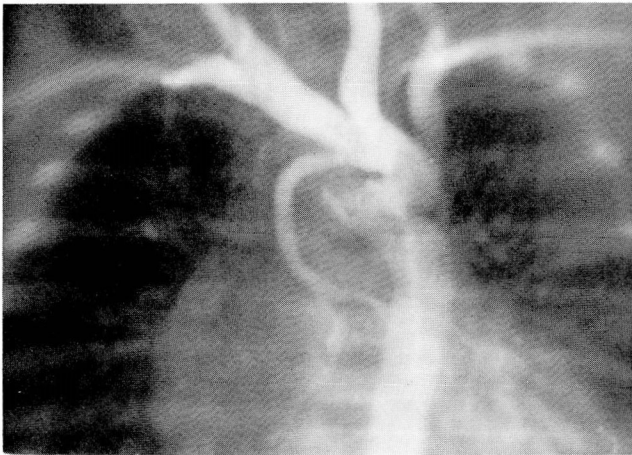
**A new surgical procedure has allowed successful palliation of hypoplastic left heart syndrome in 2 full-term infants. This procedure establishes continuity between the proximal pulmonary artery and the descending aorta. Pulmonary flow is controlled by an aortopulmonary shunt to the isolated confluence of the pulmonary arteries. The technique obviates the need for manipulation of the diminutive ascending aorta and, in addition, corrects coarctation of the aorta which is present in 70% of patients with hypoplastic left heart syndrome. The wide availability of prostaglandin E<sub>1</sub> offers a means of medical resuscitation for these moribund infants and makes surgical palliation a viable option for many infants whose condition had previously been considered hopeless.**

**Index terms:** Aortic valve, atresia • Heart, abnormalities • Heart, surgery

**Cleve Clin Q 50:269-274, Fall 1983**

Atresia of the aortic valve is the primary lesion in infants born with the congenital complex of cardiac anomalies termed "hypoplastic left heart syndrome."<sup>1</sup> There is no direct communication between the heart and the ascending aorta; consequently, both the systemic and pulmonary circulations are supported by the right ventricle. The left ventricle and mitral valve are diminutive or absent, and the systemic circulation is maintained through the ductus arteriosus. Intrauterine development is unimpaired, the pulmonary circulation is restricted by the normally high pulmonary vascular resistance, and the ascending aorta serves as a common coronary artery supplying both the

<sup>1</sup> Departments of Thoracic and Cardiovascular Surgery (C.C.G.), Pediatric and Adolescent Medicine (D.S.M.), and Cardiology (D.S.M., R.S.), The Cleveland Clinic Foundation. Submitted for publication May 1983; accepted June 1983.



**Fig. 1.** Case 2. Preoperative aortogram showing hypoplastic ascending aorta, ductus arteriosus, and coarctation of aorta.

right and left coronary circulations. The coronary circulation apparently is unrestricted since cardiac function allows the fetus to develop normally and maintains cardiac function effectively for the first few hours to days of life. After birth, the ductus arteriosus begins to constrict and reduce systemic blood flow, which, clinically, is observed as progressive tachypnea, cyanosis, diminished peripheral pulses, severe metabolic acidosis, and death. A small number of children with aortic atresia fortuitously maintain patency of the ductus arteriosus but later die of congestive heart failure as pulmonary vascular resistance diminishes. If pulmonary vascular resistance remains high, the patient may live longer, only to die of progressive pulmonary vascular obstructive disease.

Aortic atresia, a common cardiac defect accounting for 7% of all congenital cardiac anomalies, is the leading cause of cardiac death in the first week of life. Despite its prevalence, little success has been achieved with surgical palliation. The failure of surgery is even more remarkable since the essentials for successful palliation,<sup>2-4</sup> a permanent aortopulmonary communication and restriction of pulmonary blood flow, were among the first advances in the treatment of congenital heart disease. Isolated reports of successful palliation for the hypoplastic left heart syndrome have emerged over the years;<sup>5-11</sup> however, the virulent clinical course and almost uniform failure of surgical palliation have been extremely discouraging and provoked the widely accepted practice of benign neglect for these patients once the diagnosis has been established.

The recent availability of prostaglandin E<sub>1</sub>,

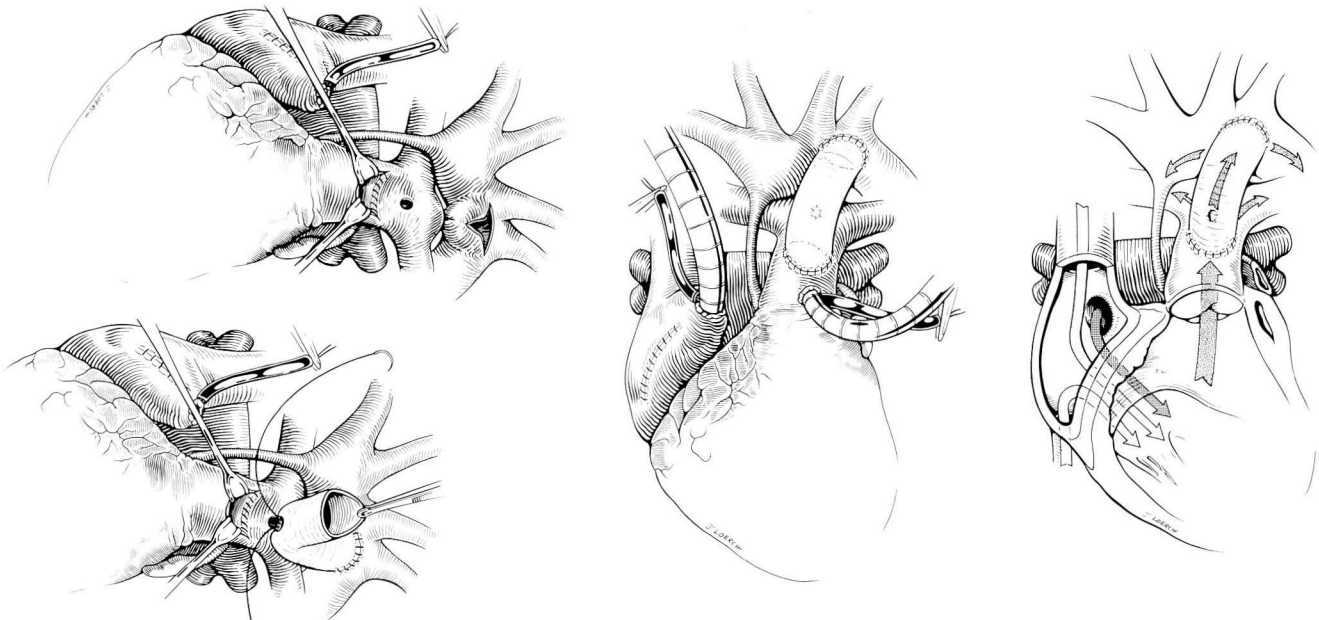
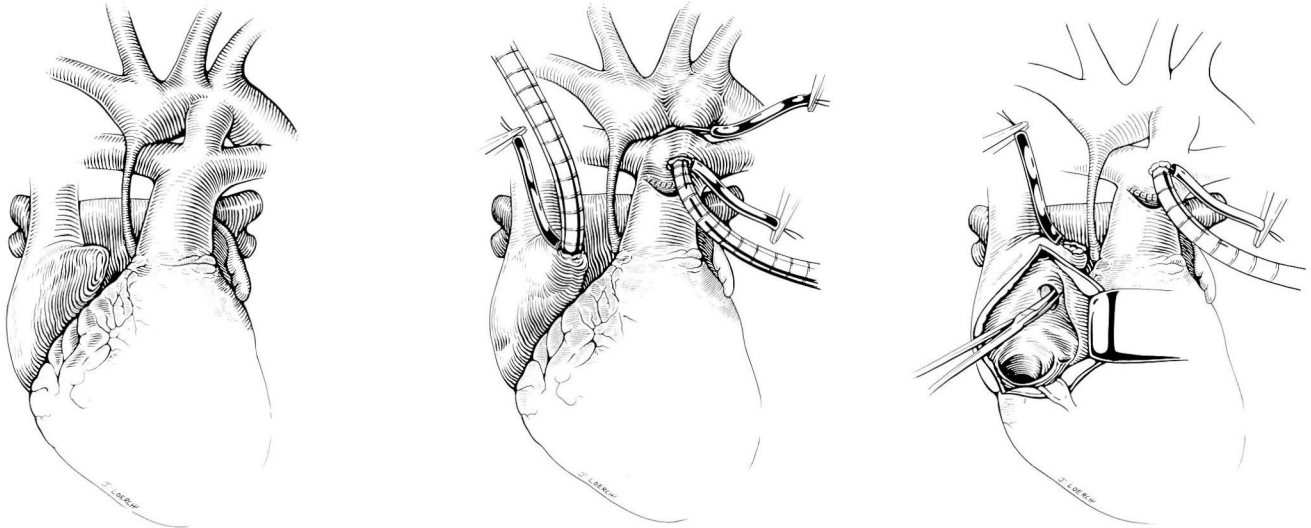
which chemically sustains patency of the ductus arteriosus, has dramatically altered the early clinical course of these children. The ability to maintain the infant in a stable hemodynamic and metabolic condition has made surgical palliation a realistic option for this otherwise fatal anomaly. We describe results in 2 infants successfully palliated with this new operative approach.

### Case report

Two critically ill, full-term infants, one female and one male, were brought to the neonatal intensive care unit. Peripheral pulses were depressed, and the systemic pH was below 7.0 in both. Each patient was resuscitated with intravenous prostaglandin E<sub>1</sub> and sodium bicarbonate. Hypoplastic left heart syndrome was diagnosed by echocardiography and confirmed by cardiac catheterization (*Fig. 1*). No other congenital anomalies were found. Both infants responded well to intravenous prostaglandin E<sub>1</sub>, and arterial pH and renal function returned to normal. The babies underwent surgical palliation at three and five days of age, respectively. The surgical procedures are described below (*Fig. 2*). The postoperative course for the first infant was complicated only by mild congestive heart failure managed with dobutamine, digoxin, and diuretics. She was extubated on the third postoperative day and discharged from the hospital 18 days after surgery (*Fig. 3*). The second baby had a similar perioperative course with mild congestive heart failure managed with intravenous dobutamine, digoxin, and diuretics. Ventilatory support was necessary for eight days. He subsequently had prolonged feeding problems and was discharged from the hospital 40 days after surgery. Both infants have continued to grow and develop normally since discharge.

### Operative technique

The heart was exposed through a median sternotomy while a continuous infusion of prostaglandin E<sub>1</sub> was maintained. The patent ductus arteriosus (PDA) was dissected free and encircled with a large silk ligature. Cardiopulmonary bypass was established with the aortic line placed via the PDA and a single cannula inserted into the right atrial appendage for venous drainage. The pump was primed with packed red blood cells and fresh frozen plasma to produce an initial hematocrit of 30% to 35%. Once bypass was begun, the PDA was snared around the aortic cannula, and the heart was emptied by gravity into the venous reservoir. Systemic cooling was begun, and the aorta was dissected free above and below the site of ductal insertion. A distally based, U-shaped incision was made at the junction of the main pulmonary artery with the confluence of the right and left pulmonary arteries. The created pedicle of pulmonary artery was sutured to the inside of the distal main pulmonary artery, isolating the confluence of the two pul-



**Fig. 2.** Operative procedure.

**A.** Hypoplastic left heart syndrome. The lungs and body are perfused by the right ventricle via the pulmonary artery. The large ductus arteriosus allows flow from the pulmonary artery to the aorta.

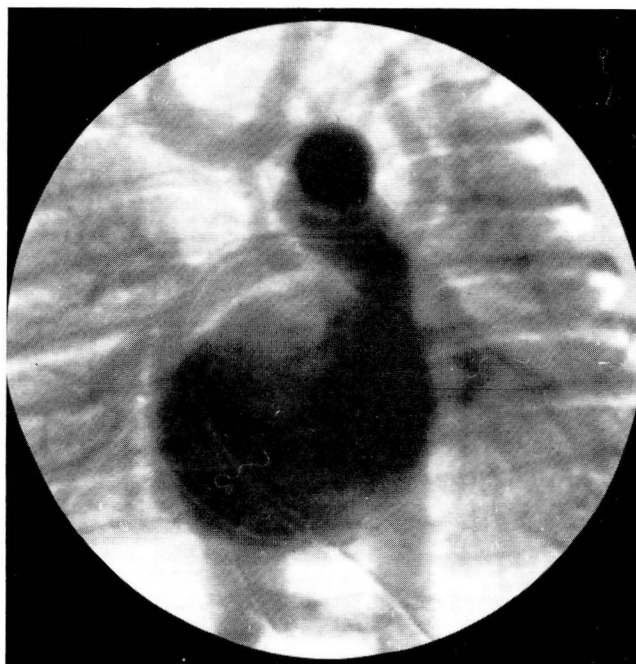
**B.** The aorta is cannulated through the ductus arteriosus. A single venous cannula is placed in the right atrium. The patient is cooled to 16° C. During cooling, the confluence of the pulmonary arteries is isolated from the main pulmonary artery by suturing a distally based pedicle of the anterior wall of the pulmonary artery to the back wall of the pulmonary artery.

**C.** When cardiopulmonary bypass has been discontinued, the patent foramen ovale is enlarged.

**D.** A T-shaped incision is made over the ductus arteriosus and adjacent aorta. The endocardial ridge of coarctation is removed if present. A 4mm fenestration is made in the anterior wall of the confluence of the pulmonary artery. A 10mm Gore-Tex graft is then sutured to the aorta distally. A 4mm fenestration is made at the appropriate level of the graft and sutured to the confluence of the pulmonary arteries.

**E.** The proximal end of the graft has been sutured to the opening in the main pulmonary artery. Cardiopulmonary bypass has been established for warming the patient.

**F.** Schematic drawing shows blood flow from the left and right atrium passing through the right ventricle into the pulmonary artery and out through the graft to the aorta. Pulmonary blood flow is limited by the 4mm window between the graft and the confluence of the right and left pulmonary arteries.



**Fig. 3.** Case 1. Digital subtraction angiogram two weeks after surgery.

monary radicles from the main pulmonary artery. When systemic temperature (rectal and nasopharyngeal) reached  $16^{\circ}\text{C}$ , cardiopulmonary bypass was discontinued. The upper descending aorta adjacent to the ductal junction was isolated with a J-shaped vascular clamp to prevent air from entering the aortic arch or vessels serving the brain. The aortic and venous cannulae were removed. The PDA was ligated proximally. A T-shaped incision was made in the aorta and adjacent ductus, and the endothelial ridge of coarctation in the aorta was excised. A 10mm polytetrafluoroethylene (Gore-Tex) prosthesis was anastomosed to the aortotomy. In the first patient, the previous site of aortic cannulation, now in the isolated confluence of the right and left pulmonary arteries, was enlarged to 4 mm with an aortic punch. A similar opening was made in the wall of the Gore-Tex graft, and the two openings were sutured together to create a 4mm aortopulmonary window. In the second case, a 4mm opening was made in the pulmonary artery flap after closing the previous cannulation site. The remaining free end of the Gore-Tex graft was then sutured to the opening in the anterior wall of the proximal main pulmonary artery. In the second case, the 4mm opening in the pulmonary artery flap was incorporated inside the suture line to provide aortopulmonary communication. The atrial septum was partially excised

through the atrial cannulation site or a small right atriotomy. Cardiopulmonary bypass to the proximal pulmonary artery was then reestablished and rewarming begun. When the systemic temperature returned to  $37^{\circ}\text{C}$ , cardiopulmonary bypass was discontinued. In the patient with the 4mm fenestration in the pulmonary artery flap, poor systemic oxygenation was evident soon after bypass was discontinued. Bypass was reinstated, and the fenestration was inspected. The Gore-Tex graft was thought to compromise the opening during systemic pressures, and the opening was oversewn. A 5mm Gore-Tex graft was then anastomosed from the proximal pulmonary artery to the right pulmonary artery, and cardiopulmonary bypass was again discontinued. Decannulation was accomplished; hemostasis was achieved with some difficulty because of bleeding through suture holes in the Gore-Tex. Routine closure was completed.

### Discussion

Anatomic configuration of the cardiovascular structures in patients with aortic atresia varies only slightly. Moodie et al,<sup>12</sup> Roberts et al,<sup>13</sup> and Von Rueden et al<sup>14</sup> have analyzed the intracardiac abnormalities and reported a 32% cumulative incidence of mitral atresia, with the remaining 68% of patients having a form of mitral valve apparatus and a small left ventricle. Five to 7% percent of patients with aortic atresia have one or more ventricular septal defects and a more nearly normal left ventricular cavity and mitral valve. Regardless of the intracardiac variables, aortic valve atresia and abnormalities of the aorta dominate the syndrome and determine the surgical approach. The ascending aorta in all patients is hypoplastic (1–4 mm), while the main pulmonary artery is enlarged. The arch of the aorta, although sometimes smaller than normal, appears in all cases to be of adequate size to serve the subclavian, carotid, and coronary vessels. Similarly, the ascending aorta, although diminutive by normal standards, appears adequate to supply blood for the myocardium.

Von Rueden et al<sup>14</sup> have emphasized one potentially important anatomic variable in these patients. In a careful review of aortic anatomy in 41 cases of aortic atresia, they found 31 (75%) with coarctation of the aorta and 7 (17%) with what Von Rueden described as "significant aortic obstruction." Both of our patients had some degree of coarctation of the aorta in the typical position adjacent to the ductus arteriosus. A sig-

nificant coarctation could well have influenced the outcome of surgical palliation if it had not been appreciated and corrected at the time of initial surgery.

The pathophysiology of patients with the hypoplastic left heart syndrome appears to be equally homogeneous. Early survival is dependent on the PDA; when closure begins, death is imminent unless ductal closure is prevented chemically. Even though patients may become moribund with severe acidosis, infusion of prostaglandin E<sub>1</sub> provides effective resuscitation.<sup>9</sup> Potentially, an atrial septal defect (ASD) could restrict pulmonary blood flow enough to cause hypoxia. This appears to be a rare occurrence even though atrial communication in these patients is usually a dilated patent foramen ovale. However, the true incidence of this problem will not be known until large numbers of babies with aortic atresia have been treated with prostaglandin. A restrictive ASD may be remedied quickly by transvenous balloon atrial septostomy.

The essentials for surgical palliation have been outlined in several previous publications.<sup>5-11,15-16</sup> They consist of: (1) a large interatrial communication; (2) free communication between the proximal pulmonary artery and the aorta; and (3) restricted pulmonary blood flow. Free interatrial communication allows egress of pulmonary venous blood that otherwise might be trapped by a small atrial septal defect and the obstructed left ventricle. Free communication between the proximal pulmonary artery and the aorta allows the already hypertrophied right ventricle to provide systemic circulation, a function it performs well in both surgically and congenitally corrected transposition of the great vessels. A small aortopulmonary shunt allows oxygenation without cardiac failure or development of pulmonary vascular obstructive disease. If these criteria are met, the patients should grow and develop through the early years and be amenable to subsequent palliative operations that create a more nearly normal circulatory pattern and further reduce cardiac work.

Cayler et al<sup>5</sup> reported the first successful palliation for aortic atresia in 1970. The operative procedure included banding the two pulmonary arteries and creating a large ascending aorta-to-pulmonary artery shunt. The patient fortunately had a relatively large ascending aorta and a non-restrictive atrial septal defect. Mohri et al<sup>6</sup> and subsequently Levitsky et al<sup>7</sup> reported palliation consisting of atrial septectomy, banding of the

distal main pulmonary artery, and insertion of a prosthetic graft between the proximal main pulmonary artery and the descending aorta. In 1980, Norwood et al<sup>8</sup> reported two successful palliative procedures for aortic atresia using cardiopulmonary bypass in circulatory arrest. Both operations involved banding the main pulmonary artery and inserting a synthetic graft from either the main pulmonary artery to the descending aorta or from the right ventricle to the descending aorta. Later the same year, Doty et al<sup>9</sup> reported successful palliation by placing a prosthetic graft from the proximal pulmonary artery to the aortic arch, creating an aortopulmonary window, and performing atrial septectomy. Behrendt and Rocchini<sup>10</sup> in 1981 reported successful palliation using direct anastomosis to the proximal pulmonary artery from the aorta with creation of a 3mm aortopulmonary window and atrial septectomy. Soon after, Norwood et al<sup>11</sup> reported his experience with 16 infants using variations of the techniques described above. He advocated direct anastomosis of the proximal pulmonary artery to the hypoplastic ascending aorta and aortic arch, atrial septectomy, and creation of an aortopulmonary shunt with a 4mm Gore-Tex graft from the proximal portion of the pulmonary artery to the isolated confluence of the right and left pulmonary arteries.

In 1980, we operated on a four-week-old boy with hypoplastic left heart syndrome. A 10mm Gore-Tex graft was inserted between the proximal pulmonary artery in the base of the aortic arch, the distal main pulmonary artery was banded, and the atrial septum excised. Although the patient could be separated from cardiopulmonary bypass for short periods of up to 20 minutes, each time he demonstrated marked electrocardiographic abnormalities compatible with myocardial ischemia and developed severe cardiac failure despite satisfactory systemic oxygen saturation. Although the orifice of the hypoplastic aorta was not directly compromised by the anastomosis, retrospectively it seemed that distortion of the aorta by the stiffer conduit compromised coronary blood flow. This experience provoked us to adopt our current technique that completely avoids any manipulation of the small, fragile ascending aorta or the aortic arch. Furthermore, exploring the juxtaductal aorta for reconstruction of cardioaortic continuity obviates concern about coarctation of the aorta since the procedure patches this area. Dissection is limited to the ductus arteriosus and adjacent aorta and

should make subsequent surgery less complicated.

The aortopulmonary shunt we have chosen has been larger than that previously described. The resultant mild congestive heart failure has been easily managed medically, and we prefer to delay further surgery, if possible, until at least four years of age. The experience of Norwood et al,<sup>11</sup> by far the largest series reported, tends to support our thesis. Of the 16 patients reported in 1981, the ascending aorta was avoided completely in 4, and continuity was established between the heart and descending aorta. No hospital deaths occurred in this group. The remaining patients had main pulmonary artery to aortic anastomosis in association with some form of central shunt. In these 12 patients 8 hospital deaths occurred, an operative mortality of 75%.

Recently, Norwood et al<sup>16</sup> have reported a successful second stage operation on an 18-month-old boy who had previously undergone direct anastomosis between the proximal pulmonary artery and the aorta. This demonstrates conclusively and dramatically the feasibility of a staged approach for the hypoplastic left heart syndrome. The second stage operation, a modification of the Fontan procedure, consisted of obliteration of the shunt to the pulmonary arteries, septation of the atria to isolate the systemic venous return from the right ventricle, and direct anastomosis of the right atrium to the pulmonary artery.

Widespread availability of prostaglandin E<sub>1</sub> and its use in patients with suspected cardiac disease will dramatically alter the early clinical course of patients with the hypoplastic left heart syndrome. Diagnosis can be readily established with echocardiography. The essential anatomy is so consistent that cardiac catheterization will not be necessary unless the patient fails to respond to infusion of prostaglandin E<sub>1</sub>. Should that occasion arise, right heart catheterization could be accomplished and the cardiac anatomy delineated and transvenous atrial septectomy achieved, if necessary. Surgical palliation can then be performed on a semiselective basis as dictated by the patient's clinical course.

Although evolution of a simple, effective surgical palliation for these patients is desirable, it is

the widespread use of prostaglandin, which allows these infants to come to surgery in good metabolic condition, that will ultimately prove the key to this previously insoluble problem.

## References

1. Noonan JA, Nadas AS. The hypoplastic left heart syndrome. An analysis of 101 cases. *Pediatr Clin North Am* 1958; **5**:1029-1056.
2. Blalock A, Taussig HB. The surgical treatment of malformations of the heart in which there is pulmonary stenosis or pulmonary atresia. *JAMA* 1945; **128**:189-202.
3. Blalock A, Hanlon CR. The surgical treatment of complete transposition of the aorta and the pulmonary artery. *Surg Gynecol Obstet* 1950; **90**:1-15.
4. Muller WH Jr, Dammann JF. The treatment of certain congenital malformations of the heart by the creation of pulmonary stenosis to reduce pulmonary hypertension and excessive blood flow. A preliminary report. *Surg Gynecol Obstet* 1952; **95**:213-219.
5. Cayler GG, Smeloff EA, Miller GE Jr. Surgical palliation of hypoplastic left side of the heart. *N Engl J Med* 1970; **282**:780-783.
6. Mohri H, Horiuchi T, Haneda K, et al. Surgical treatment for hypoplastic left heart syndrome. Case reports. *J Thorac Cardiovasc Surg* 1979; **78**:223-228.
7. Levitsky S, van der Horst RL, Hastreiter AR, Eckner FA, Bennett EJ. Surgical palliation in aortic atresia. *J Thorac Cardiovasc Surg* 1980; **79**:456-461.
8. Norwood WI, Kirklin JK, Sanders SP. Hypoplastic left heart syndrome. Experience with palliative surgery. *Am J Cardiol* 1980; **45**:87-91.
9. Doty DB, Marvin WJ Jr, Schieken RM, Lauer RM. Hypoplastic left heart syndrome. Successful palliation with a new operation. *J Thorac Cardiovasc Surg* 1980; **80**:148-152.
10. Behrendt DM, Rocchini A. An operation for the hypoplastic left heart syndrome: preliminary report. *Ann Thorac Surg* 1981; **32**:284-288.
11. Norwood WI, Lang P, Castaneda AR, Campbell DN. Experience with operations for hypoplastic left heart syndrome. *J Thorac Cardiovasc Surg* 1981; **82**:511-519.
12. Moodie DS, Gallen WJ, Friedberg DZ. Congenital aortic atresia. Report of long survival and some speculations about surgical approaches. *J Thorac Cardiovasc Surg* 1972; **63**:726-731.
13. Roberts WC, Perry LW, Chandra RS, Myers GE, Shapiro SR, Scott LP. Aortic valve atresia: a new classification based on necropsy study of 73 cases. *Am J Cardiol* 1976; **37**:753-756.
14. Von Rueden TJ, Knight L, Moler JH, Edwards JE. Coarctation of the aorta associated with aortic valvular atresia. *Circulation* 1975; **52**:951-954.
15. Doty DB. Aortic atresia (editorial). *J Thorac Cardiovasc Surg* 1980; **79**:462-463.
16. Norwood WI, Lang P, Hansen DD. Physiologic repair of aortic atresia—hypoplastic left heart syndrome. *N Engl J Med* 1983; **308**:23-26.