

Morbidity of rotational abnormalities of the gut beyond infancy¹

Hugh V. Firor, M.D.
Ezra Steiger, M.D.

Nine cases of rotational abnormalities of the gut diagnosed after infancy are presented. Eight of the 9 patients had chronic episodic symptoms and 2 patients with life-long symptoms were diagnosed only when acute midgut volvulus with infarction occurred. Rotational abnormalities of the gut in older children, although uncommon, may be associated with morbidity of long duration, and occasionally mortality. Surgical correction is indicated when a rotational abnormality is identified that is symptomatic or prone to the complication of midgut volvulus because of its anatomic characteristics.

Index terms: Intestines, abnormalities • Volvulus
Cleve Clin Q 50:303-309, Fall 1983

Abnormal rotation of the gut most frequently produces symptoms in infancy.¹ Cases first diagnosed after infancy are characterized by a wider and more obscure spectrum of symptoms than those presenting in patients under one year of age. Symptoms are more commonly chronic than acute, and delay in diagnosis is the rule. Failure to thrive,² recurrent abdominal pain and/or vomiting, or a celiaclike syndrome may occur.³ Acute midgut volvulus is less likely in the older child or young adult, but when it does occur, it regularly causes severe morbidity.⁴

Nine older patients are presented. Eight of the 9 had prior symptoms, usually of long duration. The intensity and persistence of their symptoms suggest that an earlier diagnosis was possible. In 2 patients with lifelong symptoms, diagnosis was made only when acute midgut volvulus with infarction occurred.

¹ Department of Pediatric and Adolescent Medicine and Section on Pediatric Surgery (H. V. F.) and Department of General Surgery (E. S.), The Cleveland Clinic Foundation. Submitted for publication April 1983; accepted May 1983.

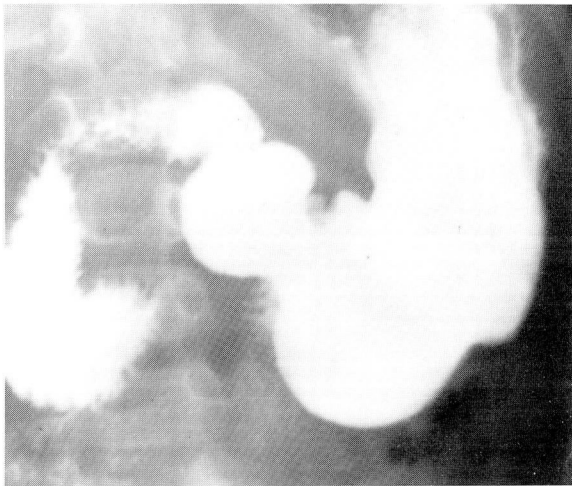


Fig. 1. Case 1. The first, second, and third portion of the duodenum with "cut-off" at the vertebral column. Barium next appeared on the right side of the midline.

Review of these cases emphasizes that rotational abnormalities in the older patient, although uncommon, cause morbidity and, on occasion, mortality.

Case reports

Case 1. A 3-year-old boy was transferred from an infectious disease hospital because of vomiting of one week's duration. He had been hospitalized for chickenpox; when vomiting became persistent, Reye's syndrome was sus-

pected. The child showed clinical evidence of fluid and electrolyte depletion and healing chickenpox but was not impressively ill. He was alert and had no findings suggestive of Reye's syndrome. His abdomen was flat with vague tenderness. Vomiting persisted. An upper gastrointestinal study showed a right-sided dilated duodenum with a small proximal jejunum (*Fig. 1*). Following appropriate fluid repletion, surgical exploration identified an incompletely rotated, partially obstructed duodenum. Following Ladd's procedure, vomiting disappeared, and recovery was prompt.

Comment: History from this child's family was vague and definite evidence of prior vomiting not clearly present. The factors associated with a childhood illness that precipitated intractable vomiting remain conjectural.

Case 2. A 4-year-old boy was referred for psychiatric evaluation of functional abdominal pain. The psychiatrist reviewed his history, discounted this diagnosis, and asked for surgical consultation. Episodic abdominal pain with vomiting and "passing out" had been occurring for three years, recently becoming more frequent and severe. A packet of radiographs accompanied the child, and a radiologist's report stated that no abnormality had been seen. Results of physical examination were within normal limits. Review of the films showed a gross rotational abnormality of the duodenojejunal segment and a displaced right colon (*Fig. 2*). At operation, abnormal rotation of the duodenum was confirmed. The jejunum and ileum were entrapped in an internal hernia behind the mesentery of the right colon. Following Ladd's procedure with excision of the redundant portion of the hernial sac, the boy remains asymptomatic.

2A, B

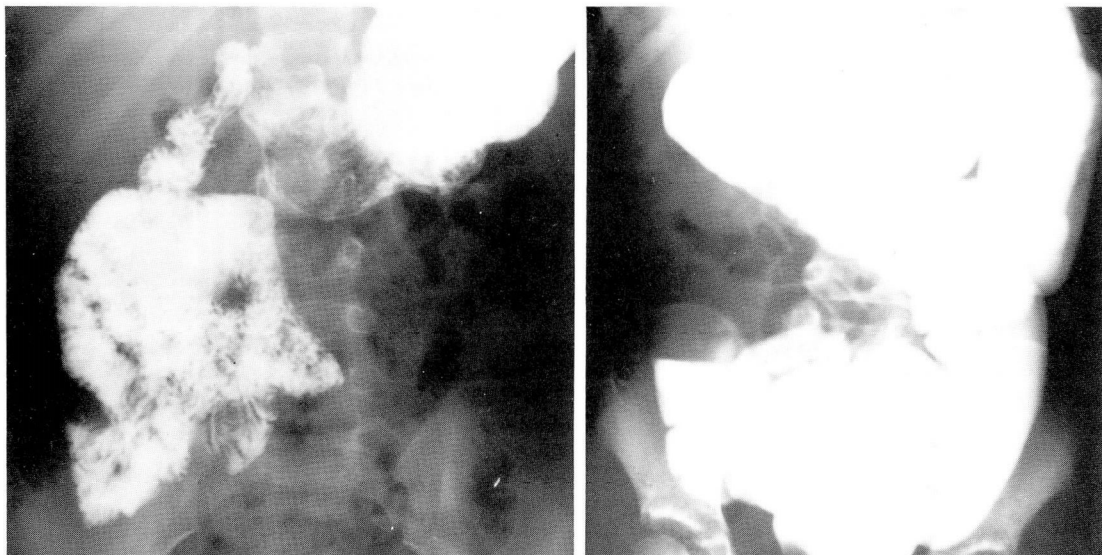


Fig. 2. Case 2. **A.** Contrast study reveals absent duodenal loop. The proximal small bowel is seen in the right side of the abdomen along with right-sided proximal jejunum. Note "clustering" of much of the jejunum on the right side.

B. Area of colon displacement coincides with right-sided jejunum seen in A. This was found to be a portion of jejunum trapped in internal hernia.

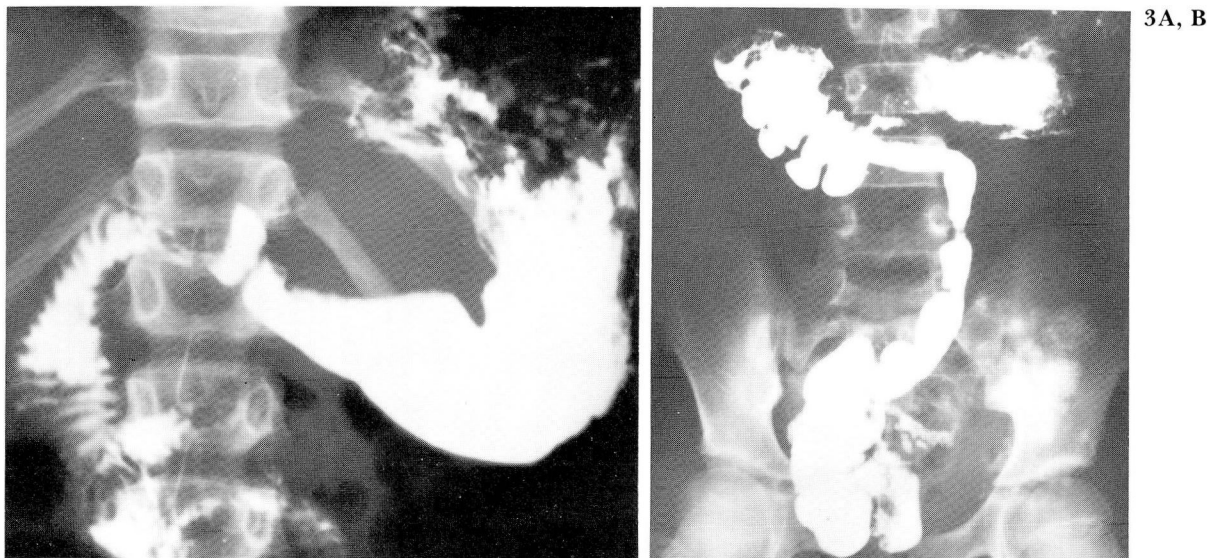


Fig. 3. Case 3. **A.** Duodenal loop is wide. Ligament of Treitz is absent resulting in downward, right-sided displacement of the proximal jejunum.
B. Follow-through film shows high cecum displaced medially.

Comment: Internal hernias are part of the spectrum of anatomic variations associated with defects of rotation and fixation.⁵

Case 3. A 7-year-old girl had been treated for a duodenal ulcer for two years without improvement. Questioning disclosed that her "ulcer" pain was episodic, cramping, and lasted from one to three hours. Intervals between these episodes varied from days to weeks. Her prior contrast study was obtained. There was no ulcer crater; the duodenum was incompletely rotated, and the cecum was high and medially displaced (*Fig. 3*). At elective operation several days later, incomplete rotation with a 360° chronic midgut volvulus without necrotic bowel was seen. She recovered promptly, and symptoms were relieved.

Comment: All instances of midgut volvulus do not produce infarction as illustrated by this case, but the possibility of bowel infarction makes this a high-risk condition.

Case 4. A 12-year-old boy, previously well, experienced mild abdominal pain occasionally followed by vomiting. Symptoms increased in severity over six months. When first seen, he had lost more than 20 pounds and was constantly symptomatic. Contrast study showed a huge right-sided duodenum obstructed at the vertebral column; the colon was normally disposed (*Fig. 4*). Surgical correction relieved all symptoms and he gained 22 pounds in the first six weeks after discharge from the hospital.

Comment: The onset of symptoms at age 12 without prior positive history is puzzling. To

relate the onset of symptoms to his adolescent growth spurt is attractive but speculative.

Case 5. A 13-year-old boy arrived with a folder of radiographs. He had had vague, poorly localized abdominal pain for ten to 12 years. Occasionally, he had to be brought home from school; vomiting was not prominent. Nutrition was good, and physical findings were normal. Contrast studies showed a right-sided duodenum and jejunum and a left-sided colon with no obvious areas of obstruction (*Fig. 5*). Two surgeons had been consulted; both advised that his symptoms and his rotational abnormality were not related. Psychiatric therapy had been recommended. At operation, several areas of low-grade obstruction were identified but no area of high-degree obstruction. A complete Ladd's procedure and search for intrinsic duodenal obstruction were done. He is symptom-free three years postoperatively.

Comment: Nonrotation of the duodenojejunal segment and of the colon commonly produces vague, poorly localized pain, as in this boy. The areas of partial obstruction seen at surgical exploration are not impressive; however, a Ladd's procedure frequently relieves symptoms.

Case 6. A 14-year-old girl was referred because of abdominal pain of several years' duration with recent increase in severity. Nutrition was good and physical findings limited to vague abdominal tenderness. Contrast studies showed exaggerated mobility of the right colon, which became largely left-sided with change of position. At operation the right colon was suspended on a mesentery; in addition, the duodenum was large and kinked upon itself with tense

4A, B

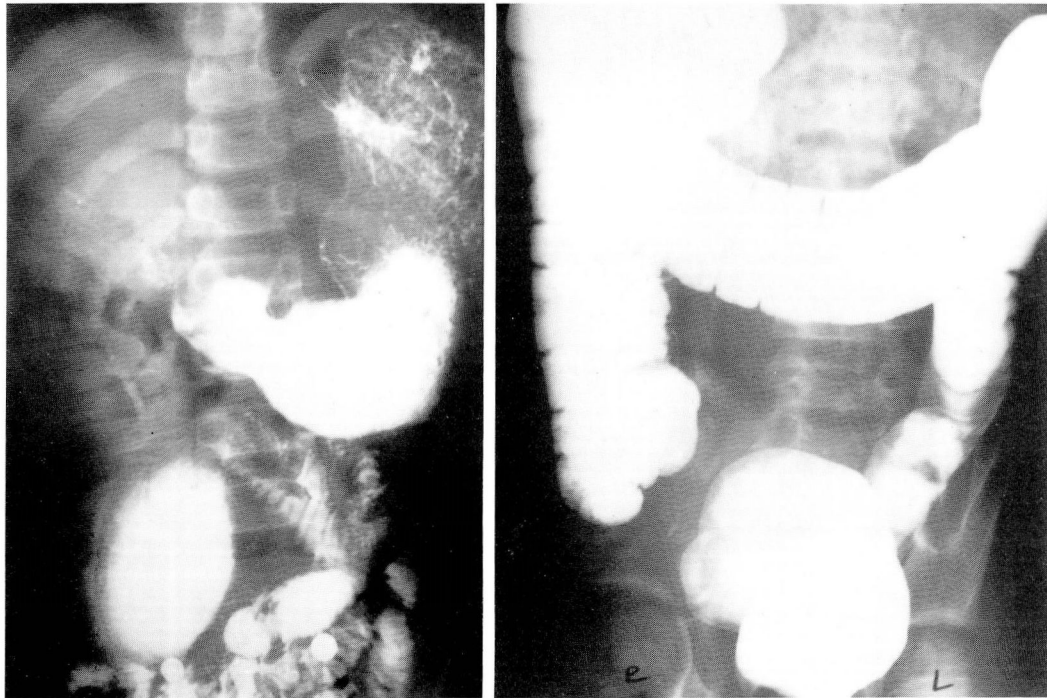


Fig. 4. Case 4. **A.** Barium outlines huge duodenum with abrupt change of lumen to normal-sized proximal jejunum.
B. Colon is normal.

membranous bands partially obstructing the duodenojejunal junction. The duodenum was freed and moved into the right side while the colon was dissected into a left-sided position. There was no intrinsic duodenal obstruction. She remains asymptomatic 18 months later.

Comment: Exaggerated mobility of the right colon has been cited as a cause of symptoms.⁶ This is difficult to document; associated duodenal and/or jejunal rotational abnormalities may also be present, as in this patient.

Case 7. A 16-year-old boy was seen because of abdominal pain, which was intermittent, severe, increased after meals, and had been present, "as long as I can remember." Positive physical findings were limited to an impressive lack of subcutaneous fat. Two prior contrast studies showed gross rotational abnormalities with a chronic midgut volvulus, findings that had not been considered of note in two separate radiology departments (*Fig. 6*). At exploration, he had incomplete rotation of the duodenum, jejunum, and colon with a 540° chronic fixed volvulus. Division of secondary adhesive bands was necessary to untwist the volvulus. A Ladd's procedure was done and intrinsic duodenal obstruction ruled out. He gained 30 pounds within the first three months postoperatively and remains pain-free seven years later.

Comment: Severe postprandial pain and impaired nutrition commonly accompany a chronic

midgut volvulus. A change in symptomatology to that of an acute abdomen with infarction of the midgut may occur without warning.

Case 8. A 15-year-old boy was seen whose history included hospitalization at six weeks of age for evaluation of vomiting, with discharge after 30 hours. He was readmitted a week later because of vomiting; the upper GI roentgenographic series was said to be normal; he was discharged after eight days. At ten weeks of age, he was hospitalized for a month for recurrent vomiting—"partial duodenal obstruction suspected but responded to dietary management." No further hospitalization was documented, but recurring abdominal pain persisted. At age 15 years, he was hospitalized because of acute abdominal pain and tenderness. Judged not to have peritoneal irritation, he was discharged after 24 hours. At a second hospital several hours later he was found to be acutely ill with a distended tender abdomen, tachycardia, and hypotension. Abdominal films showed bowel obstruction. Emergency surgery disclosed a midgut volvulus secondary to a rotational abnormality. A necrotic right colon and ileum were removed. He was transferred the following day to a medical center for reexploration. The remaining jejunum and right transverse colon required resection, and a duodenal transverse colostomy was done. Two months later, he was placed on home intravenous alimentation. After more than two years, his adaptation to oral feeding is minimal, and with current options he is committed to intravenous alimentation indefinitely.

Case 9. A 20-year-old man was seen on February 1, 1975, with onset of midabdominal pain, which rapidly wors-

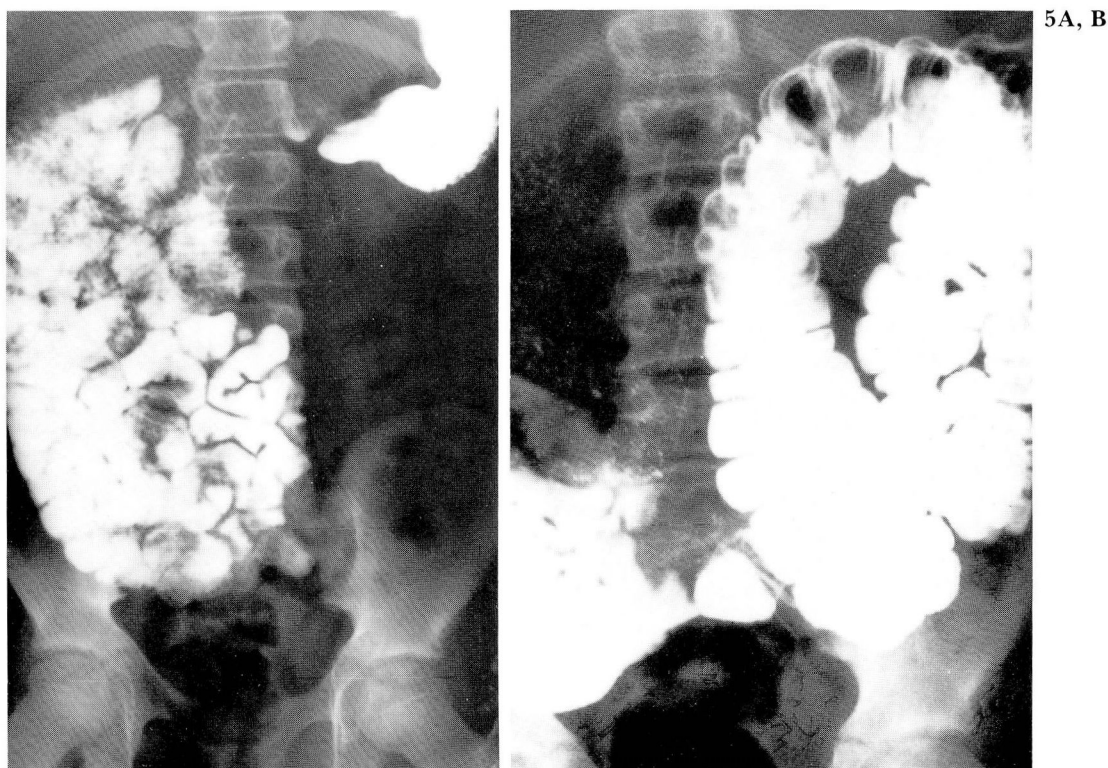

Fig. 5. Case 5. **A.** Contrast agent fills duodenum and small bowel, both in the right side of the abdomen. **B.** Entire colon is to the left of the midline in "nonrotated position."

ened. At a university health service, he was observed a few hours, and then transferred to a hospital for observation, but no diagnosis was made. The abdomen was tender and tympanic and he was treated for "pylorospasm." Thirty hours after admission he got out of bed and fainted. Blood pressure was 86/70 mm Hg; pulse 140/min; and the abdomen was distended. Exploratory operation revealed a midgut volvulus with gangrenous bowel. Excision included the small bowel except for 12 inches of proximal jejunum and two inches of terminal ileum. On subsequent home total parenteral nutrition (TPN), there were episodes of confusion and slurred speech, the result of excess NaHCO_3 loss with metabolic acidosis. He responded to NaHCO_3 supplements. He is being slowly weaned from TPN after five years, but his nutritional status is tenuous.

History review: The parents recounted that he was constantly irritable as an infant and had vomited periodically all of his life. The patient recalled having episodes of crampy abdominal pain since six years of age. Gastrointestinal series at six years of age and again at 14 years had *all been interpreted as negative.*

Comment: Cases 8 and 9 graphically illustrate the "time bomb" characteristics that a rotational abnormality may carry. The histories of these two young men indicate that numerous opportunities to make a definitive diagnosis and avert the resulting catastrophic events were missed.

Discussion

Our presentation challenges the view that in the older patient, rotational abnormalities are of little concern. Comments abound that this abnormality is generally asymptomatic in the older patient.^{7,8} Observation is repeatedly made that the presence of a rotational abnormality in the older patient is not an indication for surgical treatment.⁹ Standard gastroenterology texts caution that one must not attribute symptoms to "incidental" rotational abnormalities, thus overlooking other "significant" conditions.⁸ A surgical review of this subject states that, "If a rotational abnormality is found incidentally while operating for another surgical lesion, the latter should be treated and the rotational abnormality [should] be left and treated later, if it should produce trouble."⁴

The patients reviewed here illustrate years of undiagnosed abdominal pain and severe morbidity when an acute midgut volvulus finally occurred. Our findings parallel those recorded in numerous descriptions of rotational abnormalities in the adult.^{7,10,11}

6A, B

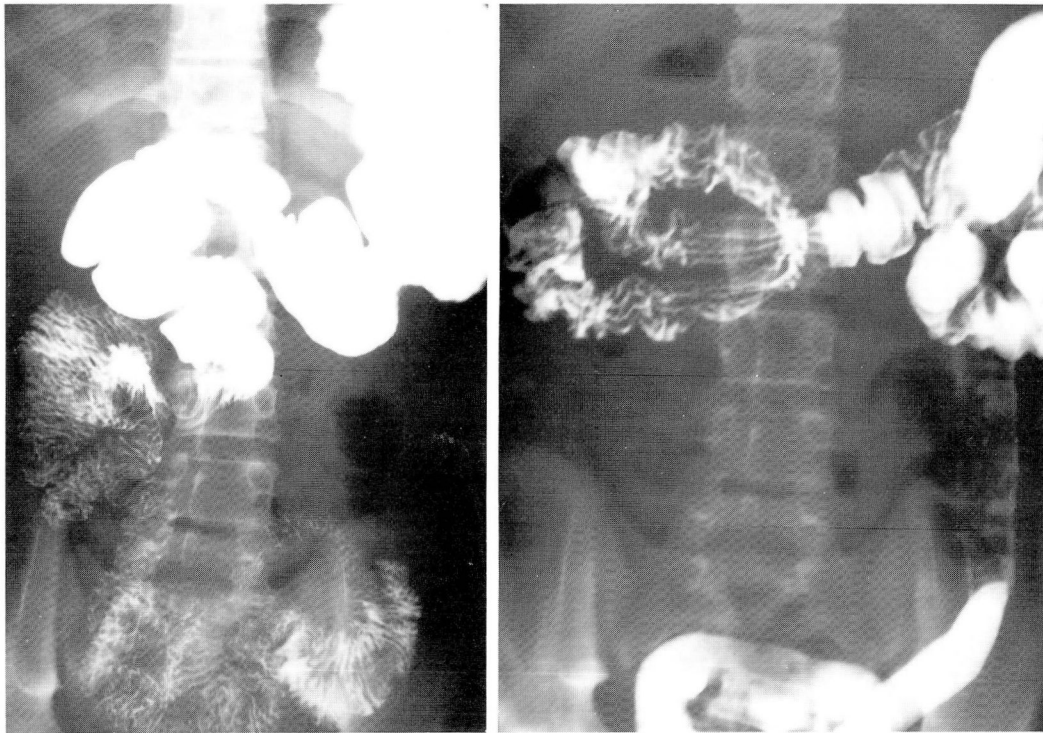


Fig. 6. Case 7. **A.** Barium outlines a "corkscrew" duodenum and proximal jejunum diagnostic of a midgut twist.
B. Displacement of right side of colon and cecum into the right upper quadrant is seen, with redundancy of the large bowel.

To summarize the observations from our series and from the literature:

Rotational abnormalities of the gut commonly are symptomatic in older patients. Repeated statements to the contrary in the literature have allowed clinicians to overlook their potential for producing chronic abdominal symptoms and/or acute abdominal crises.

Symptoms may fall into several complexes. Vomiting, which varies in frequency and severity, frequently is a clue that the abnormality is primarily an incompletely rotated duodenum.^{12,13} Severe episodic cramping, which may be followed by diarrhea, often indicates an intermittent volvulus. Chronic volvulus may also produce a spruelike malabsorption pattern with nutritional deficits.³ Complete nonrotation tends to present as poorly localized, variable but recurrent pain.⁷ A number of reports describe older patients whose long-standing chronic symptoms abruptly became acute, signaling occurrence of a volvulus.

Diagnosis was regularly delayed in our patients. Almost all had had contrast studies of the gut,

but commonly the abnormality was not appreciated by the radiologist. In other cases the abnormality was identified but not accepted as etiologically important. In common with other reports, most of our patients were misdiagnosed or labeled as having functional problems: at least 3 of the 9 patients had been referred for psychiatric care.

The patients we have studied regularly have had pain of long duration, often severe and episodic and frequently accompanied by significant associated symptoms, i.e., vomiting, fainting, bloody diarrhea, and nutritional impairment. Symptoms of this type do not support the diagnosis of a functional problem.

Abdominal symptoms possibly due to this group of abnormalities indicate contrast study of the GI tract. An upper GI contrast study with continued observation through the upper jejunum will identify all but a minute percentage of these lesions. Abnormalities limited to the distal small bowel and colon are very rarely seen and require study of the colon for identification.

Surgical correction is indicated when rotational abnormalities are identified in symptomatic patients.

Some question whether surgery is indicated in the "asymptomatic" patient. Two comments are pertinent. Such patients are rarely asymptomatic as the studies that identified the abnormality were prompted by symptoms. Second, liability to sudden onset of midgut volvulus at any age is well documented.^{4,14} Patients with a demonstrated rotational abnormality should be approached with these observations in mind. We believe operative correction is indicated in all cases in which the rotational abnormality can be complicated by a midgut volvulus. We correct the nonrotated variety if chronic abdominal symptoms are present.

A complete Ladd's procedure regularly relieves symptoms. To be effective, the following technical points are important: The bowel is eviscerated for examination and manipulation; a volvulus, if present, is untwisted in a counterclockwise direction.

Bands attaching the cecum to the right parietal peritoneum (or the ascending colon to the duodenum) are divided with appreciation that the mesenteric vessels will be threatened if this procedure is done carelessly.

The colon is dissected as extensively as possible without dividing significant vascular structures until it lies in the left abdomen.

The duodenum is freed of adhesive bands until it is right-sided and without kinks or twists.

The appendix is either removed or, more commonly in our hands, disposed of by total appendiceal inversion, which avoids opening an area of colonic flora.

A small gastrotomy opening is made in the antrum and a Foley catheter passed distally well into the jejunum. The catheter is inflated to approximately two-thirds the diameter of the bowel and withdrawn slowly to the pylorus. A partially obstructing duodenal web is reported in 8% to 12% of cases of rotational abnormalities. This maneuver will avoid overlooking such a lesion.

The duodenum is placed in the right gutter and the colon reflected into the left. The small bowel is returned to the mid-abdomen.

The technique of fixation of the duodenum and colon in their new location was described in 1966¹⁵ and has been discussed repeatedly. Currently, little data supports its use, and the original author has concluded upon follow-up that this additional step is unnecessary (personal communication, Bill AH Jr, 1982).

Other procedures for correction of rotational abnormalities have been described; we have no experience to comment on their effectiveness.

References

1. Snyder WH Jr., Chaffin L. Embryology and pathology of the intestinal tract: Presentation of 40 cases of malrotation. *Ann Surg* 1954; **140**:368-379.
2. Leslie JWM, Matheson WJ. Failure to thrive in early infancy due to abnormalities of rotation of the mid-gut. *Clin Pediatr* 1965; **4**:681-684.
3. Louw JH, Sender B, Shandling B. A rational approach to the surgical treatment of duodenal ileus. *S Afr J Lab Clin Med* 1957; **3**:249-267.
4. Berardi RS. Anomalies of midgut rotation in the adult. *Surg Gynecol Obstet* 1980; **151**:113-124.
5. Zimmerman LM, Laufman H. Intra-abdominal hernias due to developmental and rotational anomalies. *Ann Surg* 1953; **138**:82-91.
6. Janik JS, Ein SH. Normal intestinal rotation with non-fixation: A cause of chronic abdominal pain. *J Pediatr Surg* 1979; **14**:670-674.
7. Gohl ML, DeMeester TR. Midgut nonrotation in adults: An aggressive approach. *Am J Surg* 1975; **129**:319-323.
8. Spiro HM. *Clinical Gastroenterology*. 2nd ed. New York: MacMillan, 1977, p. 417.
9. Roy CC, Silverman A, Cozzetto FJ. *Pediatric Clinical Gastroenterology*. St. Louis: C.V. Mosby, 1975, pp 62-66.
10. Devlin HB, Williams RSM, Pierce JW. Presentation of midgut malrotation in adults. *Br Med J* 1968; **1**:803-807.
11. Gardner CE, Hart D. Anomalies of intestinal rotation as a cause of intestinal obstruction: Report of two personal observations: Review of 103 reported cases. *Arch Surg* 1934; **29**:942-981.
12. Firor HV, Harris VJ. Rotational abnormalities of the gut: Reemphasis of a neglected facet, isolated incomplete rotation of the duodenum. *AJR* 1974; **120**:315-321.
13. Lewis J Jr. Partial duodenal obstruction with incomplete duodenal rotation. *J Pediatr Surg* 1966; **1**:47-53.
14. Rao PL, Katariya RN, Rao PG, Sood S. Malrotation of midgut causing intestinal obstruction in adults. *J Assoc Physicians India* 1977; **25**:493-497.
15. Bill AH Jr., Grauman D. Rationale and technic for stabilization of the mesentery in cases of nonrotation of the midgut. *J Pediatr Surg* 1966; **1**:127-136.