

Evaluation of focal abnormality of the liver in a patient with known primary carcinoma of the colon¹

William Chilcote, M.D.
Edward Buonocore, M.D.

A 63-year-old white woman was admitted to the Cleveland Clinic Hospital for evaluation of an abnormal radionuclear liver-spleen scan, confirmed by ultrasound. She had had an anal carcinoma for which an abdominoperitoneal resection had been performed five years earlier. In the last month, the patient had experienced a 7-pound weight loss. Ten days before admission, a focal area of decreased activity in the posterior portion of the right lobe of the liver was detected on the liver-spleen scan. On ultrasound, a highly echogenic focal density was found in the same anatomic site (*Fig. 1*).

On admission, the abdomen was soft with questionable fullness in the right lower quadrant. Results of complete blood count (CBC) SMA-18 and urinalysis were normal. The carcinoembryonic antigen level was less than 3 ng/ml, and liver function test results were normal.

Questions

(1) In further care of this patient, what would you recommend?

(2) Does the abnormality of the liver represent a metastatic lesion?

After consultation with the Abdominal Imaging Section in the Department of Radiology, a dynamic CT scan was made. This involves taking multiple sequential scans through the same level of the liver after a bolus injection of 50 ml of contrast medium administered intravenously. Be-

fore injection of contrast medium, the mass was identified as a low attenuation area in the posterior right lobe of the liver (*Fig. 2, A*). At 20 and 40 seconds after injection of contrast material, the lesion became smaller, with irregular margins as the peripheral portion of the lesion became isodense with the surrounding normal liver (*Fig. 2, B*). At ten minutes, the lesion could no longer be identified (*Fig. 2, C*). This pattern of CT images after bolus injection of contrast medium is highly characteristic of hemangioma of the liver. For further confirmation, a CT-guided 22-gauge needle was positioned within the lesion, and only blood was aspirated. The radiologic consultant considered these findings to be diagnostic of hemangioma, and no further examinations were made. The patient has remained asymptomatic for four years with no evidence of metastatic disease.

Discussion

The availability of newer, more sensitive imaging techniques has led to the discovery of incidental findings that may add some confusion in medical diagnosis and care. The further evaluation and management of single liver defects in patients with known primary neoplasms is important so that proper care can be instituted for metastatic lesions and unnecessary procedures avoided in incidental findings.

A common problem in imaging techniques of the liver is the frequent detection of cavernous hemangiomas. The most common tumor of the

¹ Department of Diagnostic Radiology, The Cleveland Clinic Foundation. Submitted for publication April 1983; accepted June 1983.

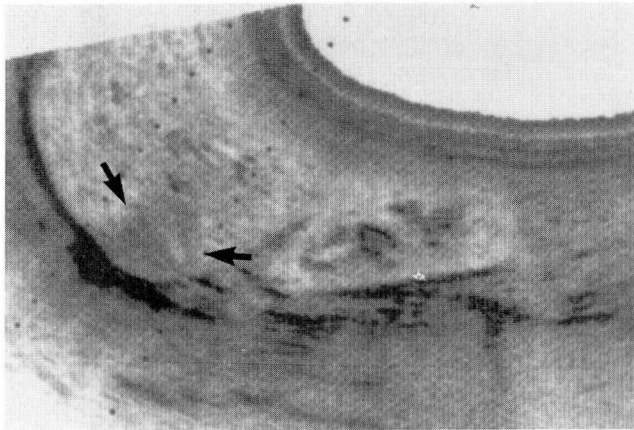
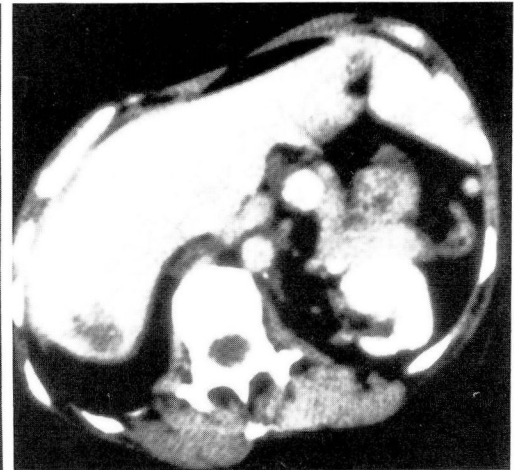
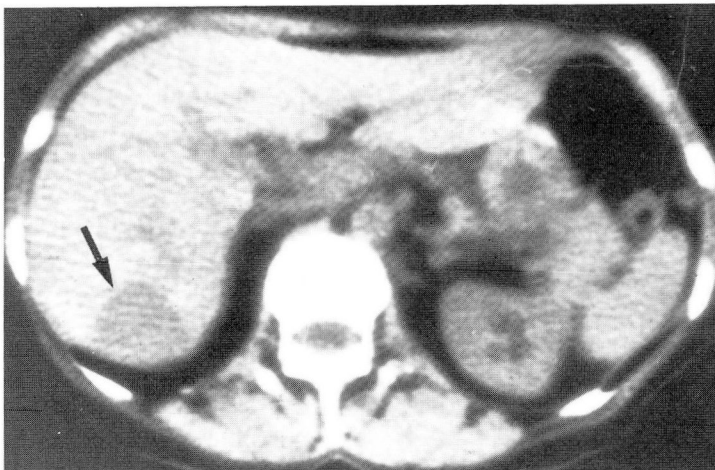
Fig. 1. Longitudinal ultrasonogram of the right lobe of the liver. Note circumscribed echogenic mass posteriorly (*arrows*).

liver, this benign neoplasm is often an incidental finding and requires an accurate means of diagnosis to avoid unnecessary and costly procedures. Various autopsy series estimate the prevalence at anywhere from 1% to 7%.^{1,2} These tumors are usually subcapsular in location, multiple in 10% of instances, and are more common in women. The ultrasound appearance of these tumors, although somewhat variable, usually has a characteristic pattern, and the tumor is diagnosed to a fairly high degree of accuracy by the experienced imager.³ On ultrasonography, hemangiomas are well-defined, dense, hyperechoic masses. Frequently, a lucent rim surrounds the echogenic area, and in approximately 30% to 35%, an echogenic line or septum can be identi-

2A, B



2C

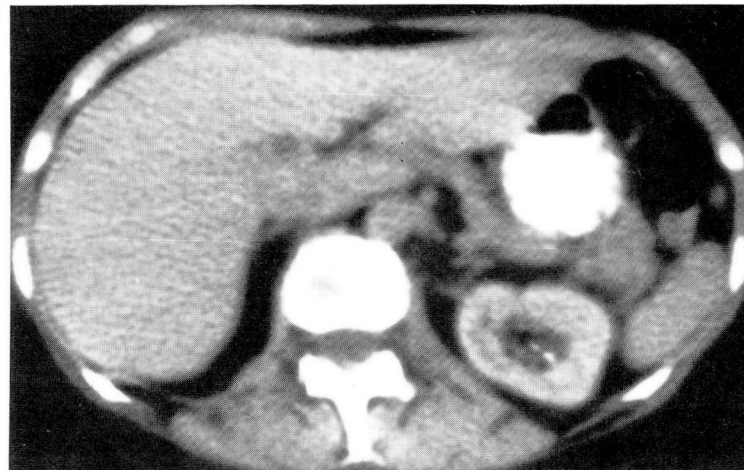


Fig. 2. Serial CT scans of the same section of the liver.

- A.** A low attenuation mass is identified posteriorly before injection of contrast medium (*arrow*).
B. Forty seconds after a 50-ml bolus intravenous injection of contrast medium, the lesion is smaller with enhanced irregular margins.
C. Ten minutes later, the mass has become isodense to the surrounding tissue and is no longer identifiable. If the examination had been isolated to this time, as is usually done in routine CT, the lesion would have been missed entirely.

fied within the central portion of the lesion (Fig. 3). This echogenic line is thought to represent a dilated vascular channel.

On occasion, cavernous hemangiomas may be confused with malignant lesions.³ In these cases, a CT scan is employed for further evaluation. If the CT study is made in the conventional manner, the results will be incomplete or may miss the lesion entirely. A dynamic technique is necessary to evaluate the flow of medium as it traverses the lesion and the surrounding tissue. In 70% of cases, cavernous hemangiomas will fill in from the periphery, often with densely enhancing

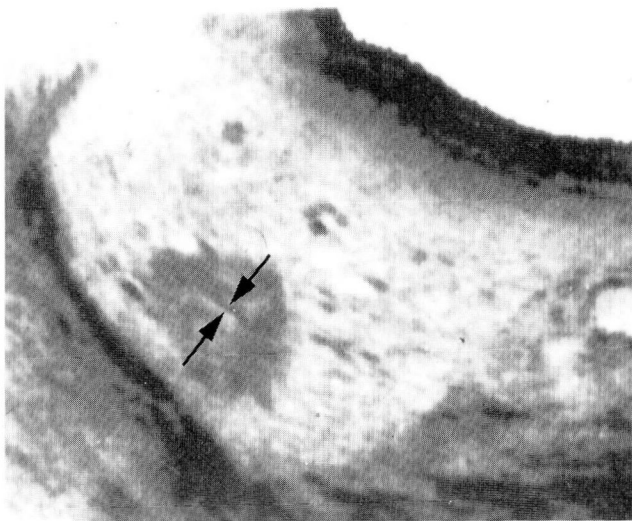


Fig. 3. Longitudinal ultrasound of the right lobe of the liver in a different patient. A well-circumscribed echogenic mass with a septum in its central portion is seen (arrows). Combination of these findings is diagnostic of a cavernous hemangioma. No further examinations were required in this asymptomatic patient.

margins.^{4,5} The CT findings are virtually diagnostic of a cavernous hemangioma. A CT-guided 22-gauge needle aspiration may be used if results are still doubtful. Experience in multiple centers indicates that there is little danger of hemorrhage when a narrow-gauge, noncutting needle is carefully directed under CT guidance.^{5,6} A question arises as to the possibility of laceration and bleeding if the patient moves or breathes during CT-guided needle aspiration of hemangiomas. No serious sequelae have been encountered at the Cleveland Clinic, and we are unaware of any controlled study or volume experience documenting lacerations or bleeding during this procedure.

Cavernous hemangiomas should always be considered in single or multiple well-circumscribed hepatic focal lesions despite the patient's history, and particularly in asymptomatic individuals. The results of dynamic CT are usually diagnostic, and no further examinations will be necessary.

References

1. Feldman M. Hemangioma of the liver. *Am J Clin Pathol* 1958; **29**: 160-162.
2. Taylor CRT, Taylor KJW. An incidental hemangioma of the liver: the dilemma of patient management. *J Clin Gastroenterol* 1981; **3**: 93-97.
3. Wiener SN, Parulekar SG. Scintigraphy and ultrasonography of hepatic hemangioma. *Radiology* 1979; **132**: 149-153.
4. Itai Y, Furui S, Araki T, Yashiro N, Tasaka A. Computed tomography of cavernous hemangioma of the liver. *Radiology* 1980; **137**: 149-155.
5. Barnett PH, Zerhouni EA, White RI Jr, Siegleman SS. Computed tomography in the diagnosis of cavernous hemangioma of the liver. *AJR* 1980; **134**: 439-447.
6. Bree RL, Schwab RE, Neiman HL. Solitary echogenic spot in the liver: is it diagnostic of a hemangioma? *AJR* 1983; **140**: 41-45.