

Percutaneous transluminal angioplasty: review of iliac and femoral dilatations at the Cleveland Clinic¹

Robert A. Graor, M.D.
Jess R. Young, M.D.
Marian McCandless, R.N.
Claudia Swift, R.N.
James A.M. Smith, D.O.
William F. Ruschaupt, M.D.
Barbara Risius, M.D.
Margaret G. Zelch, M.D.

Thirty-five iliac and 25 femoropopliteal percutaneous transluminal angioplasties (PTA) were performed at the Cleveland Clinic between February 1979 and April 1983. Patients were considered for PTA if they had disabling claudication, ischemic rest pain, ischemic ulceration or gangrene, or an arterial stenosis or occlusion that met the necessary radiographic criteria. Overall, 87% of the PTAs were an early success, and 63% remained successful at an average follow-up of eight months. The success rate for iliac PTA was 89%, with a late success rate of 74% if both the femoral and profunda femoris arteries were patent. These success rates decreased to 50% early and 25% late if only one femoral artery was patent. The femoropopliteal PTA group had an incidence of 80% early success and 56% late success. If three tibial outflow vessels were patent, the late success rate was 75%. When one or two of the tibial vessels were patent, the late success rates were 45% and 63%, respectively. The follow-up period in both groups was 9 to 11 months. The success rate for PTA is generally lower than that for surgical revascularization in patients with similar clinical symptoms and arterial pathology. However, PTA poses several advantages over surgical revascularization and should be considered, especially in the poor-risk patient.

Index terms: Angioplasty, transluminal • Arterial occlusive diseases • Catheterization • Extremities

Cleve Clin Q 51:149-154, Spring 1984

¹ Departments of Peripheral Vascular Disease (R.A.G., J.R.Y., M.M., C.S., J.A.M.S., W.F.R.) and Diagnostic Radiology (B.R., M.G.Z.), The Cleveland Clinic Foundation. Submitted for publication July 1983; revision accepted Sept 1983.

Percutaneous transluminal angioplasty (PTA) was introduced by Dotter and Judkins¹ in 1964 as a method of dilating stenotic or occluded vessels by the serial passage of graduated coaxial catheters. The complication rate was believed to be high, and this method never achieved wide use in North America. In 1974, Grüntzig and Hopff²

described PTA employing a balloon catheter, which avoided many of the theoretical and practical disadvantages of the Dotter catheters. Grüntzig's catheters came in a variety of shapes and sizes with an inflatable balloon which provided centrifugal force but no shearing stress. The Grüntzig catheter, comparable in size and flexibility to standard angiographic catheters, could be used in many situations previously untreatable by PTA. In the past, many physicians have avoided using PTA because of the high risk of dissection, embolization, thrombosis, and the inability to recanalize arterial occlusions. Recent studies^{2-8,10,13,14,17} have proved these concerns to be unfounded. We report our experience with PTA and compare it with the experience of others.

Patients and methods

From February 1979 through April 1983, 58 patients, randomly selected, underwent 60 iliac or femoropopliteal PTAs in the Department of Diagnostic Radiology at the Cleveland Clinic. One patient required two PTAs, and one patient required redilatation of a stenosed, previously dilated artery.

Patients were considered for PTA if they had disabling claudication, ischemic rest pain, ischemic ulceration, or gangrene. Hemodynamically significant arterial stenosis was localized to 20 cm or less in length. The disabling claudication category included patients with 50% block claudication who were unable to conduct their daily activities with this restriction. The clinical characteristics of the patients in this series are presented in *Table 1*.

The details of PTA technique are similar to those previously described by Grüntzig.^{2,3,10} In our series, early and long-term results were evaluated by a combination of clinical and noninva-

sive criteria. Noninvasive testing included segmental Doppler pressures and arterial plethysmography before and after exercise on a treadmill with a 10% grade at 1.5 miles per hour. A PTA procedure was considered successful if both the patient's symptoms and results of tests judged by noninvasive criteria improved. Clinical improvement was judged by reduction of claudication, relief of rest pain, or healing of ulceration. In noninvasive testing, results were considered improved if one of these criteria were present: 1) the ankle-brachial systolic blood pressure ratio was improved by more than 0.10; 2) a monophasic Doppler signal became biphasic or triphasic; or 3) the maximal treadmill walking time either doubled or increased to 5 minutes. Although somewhat stricter, these criteria for success are similar to those used in other reports.

We have adopted a grading system for the number of patent arteries distal to the arterial lesion to be dilated (*Table 2*). For the iliac vessels, two grades were utilized. Grade 1 included patients with a single outflow vessel, either profunda femoris or superficial femoral artery. Grade 2 consisted of patients with both arteries patent. Among patients having PTA distal to the inguinal ligament, grade 1 included patients with a single tibial artery patent, whereas grades 2 and 3 consisted of patients with two and three tibial arteries patent, respectively.

Results

Thirty-four patients with iliac disease had 35 dilatations, and 24 patients with femoropopliteal disease had 25 dilatations. These dilatations were classified as a success or failure, both immediately (within three days after angioplasty) and during a follow-up period of three to 37 months. Eighty seven percent of the entire group experienced early success, and 63% remained successful at an average follow-up period of eight months.

Table 1. Clinical data at the time of PTA

Clinical data	All dilatations (N = 60)	Iliac (N = 35)	Femoropopliteal (N = 25)
Male:female	41:19	26:9	15:10
Average age (yr)	62	60.8	63.9
Age range (yr)	36-85	36-85	42-77
Diabetes mellitus	14 (23%)	7 (20%)	7 (28%)
Hypertension	35 (58%)	14 (40%)	21 (84%)
Smoking	34 (57%)	21 (60%)	13 (52%)
Claudication	40 (67%)	27 (77%)	13 (52%)
Ischemic rest pain	17 (28%)	6 (17%)	11 (44%)
Ischemic ulceration	3 (5%)	2 (6%)	1 (4%)

Table 2. Angiographic data at time of PTA

Angiographic data	Iliac (n = 35)		Femoropopliteal (n = 25)	
	No.	(Percent)	No.	(Percent)
Grade 1	8	(23)	12	(48)
Grade 2	27	(77)	9	(36)
Grade 3	4	(16)
Length of stenosis (cm)				
0.5-5.0	22	(63)	21	(84)
6.0-10	12	(34)	2	(4)
11-20	1	(3)	2	(4)
Calcified	2	(6)	4	(16)

If the patients are divided into subsets with regard to number of distal arteries patent, the results are substantially different. For patients having iliac PTA with patent superficial femoral and profunda femoris arteries (grade 2), the early success rate was 89%, and the late success rate was 74%. Patients who had only a single patent vessel below the iliac dilatation (grade 1), showed an early success rate of 50% and a late rate of 25%. The average follow-up in this group was 8.9 months. Although the number of patients in the groups is small, the differences achieved statistical significance ($P = 0.005$).

The 24 patients having femoropopliteal PTA had an 80% incidence of immediate success and a 56% late success rate. From the perspective of distal arterial disease, patients with three patent tibial vessels (grade 3) had a 75% late success rate. When one (grade 1) or two (grade 2) of the tibial vessels were patent, the late success rates were 45% and 63%, respectively. The mean follow-up period in this group was 11.2 months. Six patients with total occlusions in the femoropopliteal system had an initial success rate of 89% and a late rate of 56%. In each of these patients, three tibial vessels were patent.

The severity of the patient's symptoms inversely correlated with success. In the iliac dilatation group, 27 patients with claudication had an 89% early and a 70% late success rate. Six patients with ischemic rest pain had a 50% early and a 33% late success rate. In one patient with an ischemic ulceration, the ulcer healed and remained healed for 12 months of follow-up. The second patient with an ischemic ulcer had an unsuccessful dilatation, and his ulcer failed to heal. In the femoropopliteal group, 13 patients who presented with claudication had an 85% early and a 69% late success rate. Of 11 patients with ischemic rest pain, 72% had early success, and 36% had late success. In one patient with ischemic ulceration, the ulcer healed and remained healed for 12 months.

Of the patients with successful PTA, 69% were asymptomatic and 26% had mild claudication. Five percent of the patients continued to have severe claudication but had sufficient improvement for their ulcerations to heal and gained relief from rest pain.

In general, diabetics had slightly less success than nondiabetics in both the iliac and femoropopliteal groups. Age seemed to have no influence on the success of dilatation. In neither group were results statistically significant.

Significant complications occurred in 4 of our 60 dilatations (7%). Only one of the 4 patients required surgical intervention, a surgical closure of the femoral artery after the catheter was withdrawn. Two patients required intra-arterial low-dose streptokinase infusions to lyse an arterial thrombus or distal embolus. The fourth complication was a brachial plexus injury from an axillary approach to a distal dilatation. This complication persisted at 16 months after dilatation.

Discussion

Atherosclerotic plaques vary greatly in structure. Some are ulcerated and filled with friable material, whereas others are subintimal, completely covered with endothelium. Some lie entirely in the media; still others are located within the media and intima. Most plaques are calcified, although some are semi-fluid, with the consistency of toothpaste. Other arterial lesions consist of hyperplastic thickening of the intima itself and do not lend themselves to dilatation easily. Firm plaques usually split longitudinally on dilatation, and on postdilatation arteriograms, linear cracks will be seen in the walls of the vessel (*Fig. 1*).

We analyzed the results of PTA in 60 dilatations and found that the procedure was successful in certain patients. Careful comparison with other reports is difficult, because only a few authors have used objective methods to determine their success rates and to analyze their results. Data obtained from purely clinical follow-up can be misleading. Noninvasive laboratory evaluation or arteriography will yield more reliable and comparable data.

Review of the literature reveals that the highest success rates with PTA involve lesions of the common iliac artery. Results are progressively less successful for dilatation of the external iliac artery, superficial femoral artery, popliteal artery above the knee, and popliteal artery below the knee. Successful dilatations in the iliac arteries varied from 84% to 90% after one year, with cumulative patency rates at two years ranging between 70% and 90%.¹⁻⁹ For dilatations in the femoropopliteal segment, several authors⁴⁻⁹ have reported success rates of 70%–80% in patients followed for two years. Similar results were reported by Freiman et al¹³ and Spence et al,¹⁴ although their patients were followed for shorter periods.

In our series, we found that several factors were responsible for determining the outcome of transluminal dilatation. Success was greatest

1A,B

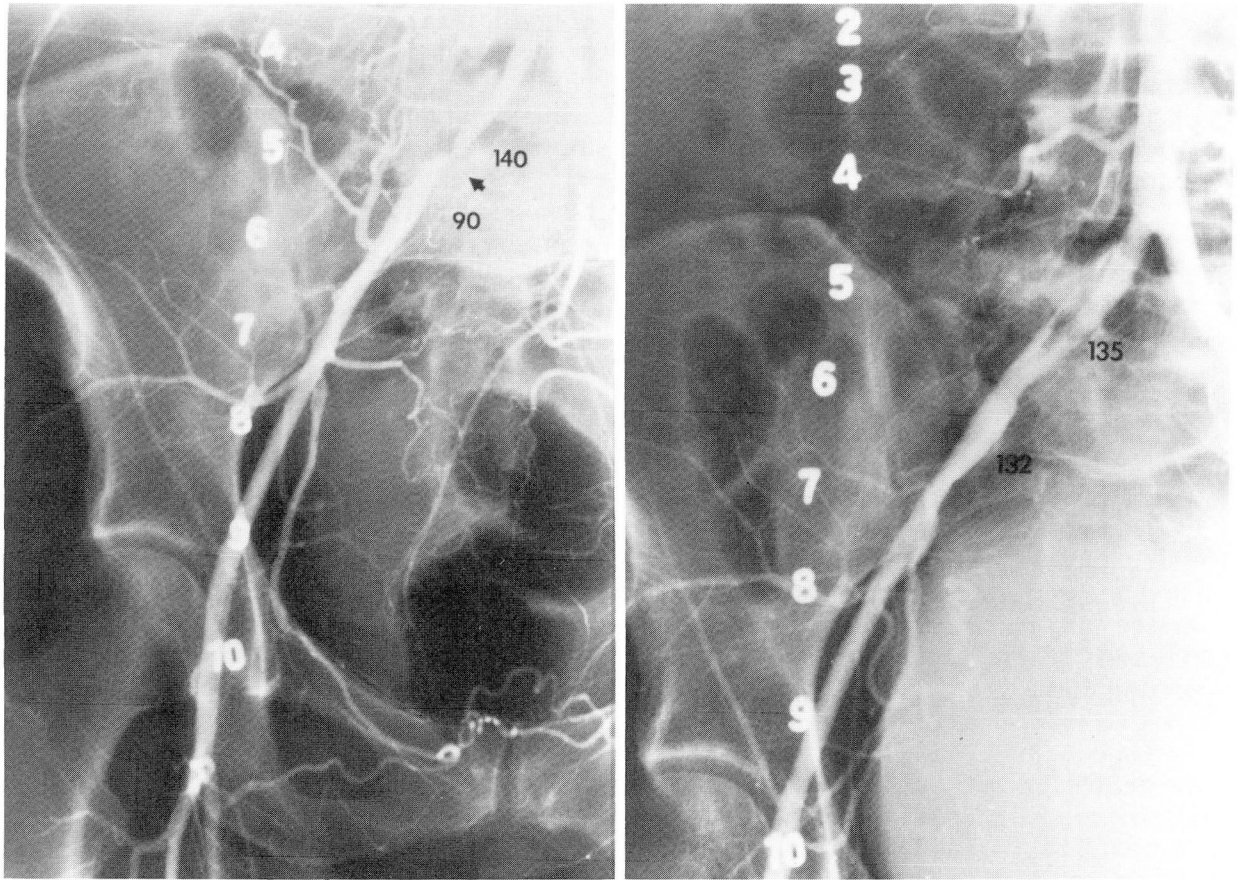


Fig. 1. A. Isolated atherosclerotic right common iliac stenosis. Gradient across the lesion was 50 mm Hg.
B. Post-PTA angiogram demonstrates widely patent common iliac artery without a significant gradient. Note intimal dissection.

when the procedure was used to dilate proximal large arteries, when the arterial lesion was short, and when the lesion was localized and not diffuse (*Table 2*). Severity of distal arterial occlusive disease adversely affected the early and late results of iliac dilatations, but had a less clear cut influence on early patency rates of femoropopliteal dilatations. The severity of distal arterial occlusive disease adversely affected late patency rates in the femoropopliteal region. In previous reports, distal runoff has been a critical factor in determining success of PTA.^{4,5,7}

The success rate was slightly higher if the clinical indication for the procedure was claudication and slightly lower if the patient had advanced arterial disease with ischemic rest pain, ulceration, or gangrene. All patients with claudication as the only symptom prior to dilatation had an ankle-brachial systolic blood pressure ratio greater than 0.35, and their results were better. The presence of diabetes appeared to slightly compromise the success of dilatation. This is

likely due to the distal small vessel atherosclerosis often seen in diabetics. Finally, the success rate was equal in all age groups when similar patients were compared with respect to distal artery disease. These factors regarding success of PTA are similar to those used to predict success of arterial reconstruction.

Although no randomized studies have been done to compare surgical revascularization results with PTA, information on surgical results is important for comparison of the modalities. Satisfactory results of surgical revascularization depend on careful evaluation of the extent of the occlusive disease, careful attention to intraoperative technical details, and assurance of adequate runoff. Mortality should not exceed 3% for elective vascular reconstruction, and a perioperative complication rate of less than 5% is expected. Early patency rates for aortofemoral bypass grafts generally are greater than 98%, and five and ten-year patency rates are 90% and 80%, respectively. Femoropopliteal bypasses with saphenous

vein provide a five-year patency rate of 80%–90%, whereas femorotibial vein bypasses can achieve a 70% five-year patency rate, if adequate runoff exists.^{18–22}

In contrast to surgical revascularization, PTA is better suited to correct a localized arterial lesion but usually is not appropriate for multiple long lesions. It is not surprising, therefore, that patients with multiple lesions have persistent, although less severe symptoms of vascular insufficiency after PTA. Of note, however, is that 12 of the 35 (34%) dilatations of the iliac arteries had ankle-brachial blood pressure ratios that returned to normal.

Small hematomas are common with PTA but usually present no problem. Major problems at the catheter site, including large hematomas, false aneurysms, thrombosis, and arteriovenous fistulae are uncommon.^{10–15} The frequency of complications at the site of PTA is not as well known. These patients should be followed for restenosis, thrombosis, and possible late aneurysm formation. Symptomatic dissection of the artery and perforation are rare with the Grüntzig balloon. Distal embolization may occur, but it has not been proved to lead to significant sequelae.²³

Advantages to PTA include low cost and low mortality and morbidity. In general, the patient's condition does not significantly worsen if the dilatation fails. In addition, when compared to iliac artery revascularization, there is no involvement of the pelvic autonomic nerves and resultant male sexual dysfunction.^{16,17} It does not preclude future surgery, and it preserves the saphenous vein for later cardiac or peripheral artery bypass surgery.

It is difficult to determine when transluminal dilatation should be considered. The procedure appears to have an important role, especially in elderly, poor-risk patients. When combined with surgical revascularization, PTA may also be of benefit by dilating inflow or runoff arterial lesions. For example, an iliac or distal popliteal or tibial lesion angioplasty done prior to femoropopliteal bypass may provide more complete revascularization and improve long-term graft patency. Although Motarjeme et al¹⁵ feel that PTA has a role in the management of more than 50% of the patients they studied, we feel that the risks and benefits indicate that a somewhat smaller number of patients will actually qualify.

There are no randomized prospective studies comparing PTA and vascular reconstructive sur-

gery. Nevertheless, a review of the literature and of our own results indicates that the success rate for PTA is generally lower than that for surgical revascularization in patients with similar clinical symptoms and arterial pathology. The main indication for PTA appears to be in patients who may not tolerate surgical revascularization.

References

1. Dotter CT, Judkins MP. Transluminal treatment of arteriosclerotic obstruction; description of a new technique and a preliminary report of its application. *Circulation* 1964; **30**:654–670.
2. Grüntzig A, Hopff H. Perkutane Rekanalisation chronischer arterieller Verschlüsse mit einem neuen Dilatationskatheter. *Modifikation der Dotter-Technik. Dtsch Med Wochenschr* 1974; **99**:2502–2510.
3. Zeitler E, Grüntzig A, Schoop W, eds. Percutaneous vascular recanalization: technique, application, clinical results. Berlin, Springer-Verlag, 1978.
4. Greenfield AJ. Femoral, popliteal, and tibial arteries: percutaneous transluminal angioplasty. *AJR* 1980; **135**:927–935.
5. Gallino A, Mahler F, Probst P, Nachbur B. Early and late results in 250 cases of percutaneous transluminal dilatation in the lower extremities. *Vasa* 1982; **11**:319–321.
6. Zeitler E, Schoop W, Zahn W. The treatment of occlusive arterial disease by transluminal catheter angioplasty. *Radiology* 1971; **99**:19–26.
7. Katzen BT, Chang J, Knox GW. Percutaneous transluminal angioplasty with the Grüntzig balloon catheter. *Arch Surg* 1979; **114**:1389–1399.
8. Brahme F, Swedenborg J, Tibell B. Evaluation of transluminal recanalisation of the femoral artery. *Acta Chir Scand* 1969; **135**:679–684.
9. van Andel GJ. Percutaneous transluminal angioplasty; the Dotter procedure. Amsterdam, Excerpta Medica, 1976.
10. Grüntzig A, Kumpe DA. Technique of percutaneous transluminal angioplasty with the Grüntzig balloon catheter. *AJR* 1979; **132**:547–552.
11. Tegtmeyer CJ, Moore TS, Chandler JG, Wellons HA, Rudolf LE. Percutaneous transluminal dilatation of a complete block in the right iliac artery. *AJR* 1979; **133**:532–535.
12. Colapinto RF, Harries-Jones EP, Johnston KW. Percutaneous transluminal recanalization of complete iliac artery occlusions. *Arch Surg* 1981; **116**:277–281.
13. Freiman DB, Spence R, Gatenby R, et al. Transluminal angioplasty of the iliac and femoral arteries: follow-up results without anticoagulation. *Radiology* 1981; **141**:347–350.
14. Spence K, Freiman DB, Gatenby R, et al. Long-term results of transluminal angioplasty of the iliac and femoral arteries. *Arch Surg* 1981; **116**:1377–1386.
15. Motarjeme A, Keifer JW, Zuska AJ. Percutaneous transluminal angioplasty and case selection. *Radiology* 1980; **135**:573–581.
16. Dotter CT. Transluminal angioplasty: A long view. *Radiology* 1980; **135**:561–564.
17. van Andel GJ. Transluminal iliac angioplasty: long-term results. *Radiology* 1980; **135**:607–611.
18. Baddeley RM, Ashton F, Slaney G, Barnes AD. Late results of autogenous vein bypass grafts in femoropopliteal arterial occlusion. *Br Med J* 1970; **1**:653–656.

19. DeWeese JA, Rob CG. Autogenous venous bypass grafts five years later. *Ann Surg* 1971; **174**:346-356.
20. Mozersky DJ, Sumner DS, Strandness DE. Long-term results of reconstructive aortoiliac surgery. *Am J Surg* 1972; **123**:503-509.
21. Reichle FA, Tyson RR. Comparison of long-term results of 364 femoropopliteal or femorotibial bypasses for revascularization of severely ischemic lower extremities. *Ann Surg* 1975; **182**:449-455.
22. Malone JM, Moore WS, Goldstone J. The natural history of bilateral aortofemoral bypass grafts for ischemia of the lower extremities. *Arch Surg* 1975; **110**:1300-1306.
23. Roberts B, Ring EJ. Current status of percutaneous transluminal angioplasty. *Surg Clin North Am*, 1982, **62**:357-372.