

Digital subtraction angiography to assess the results of operative repair in infants with hypoplastic right and left heart syndromes¹

Douglas S. Moodie, M.D.
Richard Sterba, M.D.
Carl C. Gill, M.D.
John Yiannikas, M.D.
Edward Buonocore, M.D.

The authors describe the use of intravenous digital subtraction angiography (DSA) for the postoperative evaluation of 4 infants following surgery for hypoplastic right and left heart syndromes. Digital and analogue systems with single average multiple masks were used with two commercially available systems with radiographic or continuous models. In all infants, 3 ml or less of Renografin-76 was injected intravenously for the study. DSA studies in 2 infants with hypoplastic right heart syndrome 18 and 19 months, respectively, after surgery, clearly demonstrated growth of the right ventricular chamber. In 1 infant, a pericardial outflow track aneurysm had developed. Two infants with hypoplastic left heart syndrome underwent studies 15 and 20 days after surgery, respectively, which demonstrated the adequacy of systemic and pulmonary artery flow and normal right ventricular function. Intravenous DSA is a safe and effective measure for following the results of surgery in infants with hypoplastic right and left heart syndromes.

Index terms: Digital subtraction angiography (DSA) • Heart defects, congenital

Cleve Clin Q 51:19-26, Spring 1984

Hypoplastic right heart syndrome (pulmonary atresia with an intact ventricular septum and a hypoplastic right ventricle) has a high early and late mortality.^{1,2} The dismal outlook for this condition has been attributed to associated right ventricular hypoplasia. Recent surgical reports¹⁻⁷ have shown the importance of augmentation of pulmonary blood flow by using a systemic pulmonary artery shunt as well as by establishing right ventricular pulmonary artery continuity to stimulate right ventricular growth as prereq-

¹ Departments of Cardiology (D.S.M., R.S., J.Y.), Thoracic and Cardiovascular Surgery (C.C.G.), Diagnostic Radiology (E.B.), and Pediatric and Adolescent Medicine (D.S.M.), The Cleveland Clinic Foundation. Submitted for publication July 1983; accepted Aug 1983.

uisites for survival. Subsequent anatomy is conducive to further, more definitive repair. Few studies, however, have documented the results of cardiac surgery, particularly in terms of right ventricular growth in these patients.⁸⁻¹⁰

Hypoplastic left heart syndrome (mitral and aortic atresia associated with a hypoplastic left ventricle) has been an even more lethal condition in the newborn. According to data collected between 1969 and 1979 in the New England Regional Infant Cardiac Program, 223 infants were identified as having aortic atresia and none survived for a year.¹¹ Their demise accounted for nearly 20% of cardiac deaths during the first week of life.¹¹ Recent reports of successful palliative repair in the newborn¹²⁻¹⁷ have stimulated new interest in this entity, but again there are few studies evaluating the results of the initial palliative surgery.¹⁶

With the recent development of intravenous digital subtraction angiography (DSA), an accurate assessment of the size, contractility, and relationship of the various intracardiac chambers has been possible with a spatial resolution comparable to that of direct contrast angiography. We have found no reports in the literature of the use of this technique for follow-up after surgical repair of infants with either the hypoplastic right or left heart syndromes. We describe 4 infants, 2 operated on in the newborn period with hypoplastic right heart syndrome and 2 with hypoplastic left heart syndrome who were studied using intravenous DSA techniques to assess immediate and short-term results following palliative intracardiac repair.

Case reports

Case 1. A 4-day-old, 2,275-g white boy was born to a 27-year-old gravida II, para 1 who had had no problems during pregnancy, labor, and delivery. When the baby was two days old, a murmur was noted. Cardiac catheterization demonstrated a hypoplastic right ventricle, intact ventricular septum (*Fig. 1*), large atrial septal defect, and patent ductus arteriosus supplying the pulmonary arteries with a right ventricular systolic pressure of 100mm Hg.

After cardiac catheterization, the infant was transferred to The Cleveland Clinic Foundation. On examination here, the infant was cyanotic, but in no distress. His weight was 2.2 kg, heart rate was 130 beat/min, and the respiratory rate was 50/min. The cardiac examination demonstrated a right ventricular lift. The first heart sound was normal. The second heart sound was single and increased. There was a 2/6 systolic murmur at the left upper sternal border. The chest radiograph demonstrated a normal-sized heart with decreased pulmonary vascularity. The electrocardiogram showed sinus rhythm with a QRS axis of +100°. Right

ventricular forces were absent, and left ventricular hypertrophy was demonstrated. The two-dimensional echocardiogram demonstrated a hypertrophied, hypoplastic right ventricle with a normal, but somewhat small, tricuspid valve. The pulmonary arteries appeared hypoplastic.

One day after admission, the patient underwent surgical repair and a cardiopulmonary bypass with placement of a 4mm side-to-side aortopulmonary window with right ventricular outflow tract infundibulectomy and pericardial patch angioplasty connecting the right ventricle to the main pulmonary artery. The pulmonary valve was excised, and enlargement of the atrial septal defect was noted.

The infant's postoperative course was stormy with respiratory insufficiency requiring prolonged ventilatory support as well as disseminated intravascular coagulation necessitating a postoperative stay of 110 days.

Nineteen months postoperatively, the infant underwent DSA via intravenous injection from a small line placed in the inferior vena cava (*Fig. 2*). The DSA study showed clearly that the right ventricle had grown significantly from the preoperative state demonstrated in *Figure 1*. In addition, a pericardial outflow tract aneurysm could be clearly identified by DSA (*Fig. 3*).

The patient continues to do well 37 months after surgery. We plan to perform a Fontan-type operation in one to two years.

Case 2. A 2-day-old white girl was born to a 23-year-old gravida II, para 1 following a long labor, spinal anesthesia, and forceps delivery. A murmur was noted at birth, but the infant was thought to be normal until 12 hours of age when she was noted to be cyanotic.

The physical examination at The Cleveland Clinic Foundation revealed the infant to be mildly cyanotic and in no distress. Her heart rate was 130-160 beat/min with crying, and the respiratory rate was 40/min. Her weight was 3.3 kg. The first heart sound was normal. The second heart sound was single and increased. A 3/6 systolic murmur was noted at the left middle and left upper sternal border.

The chest radiograph demonstrated cardiomegaly with right atrial enlargement. The electrocardiogram showed sinus rhythm with a QRS axis of +60°. Left ventricular hypertrophy and questionable right ventricular hypertrophy were evident. A two-dimensional echocardiogram demonstrated a hyperdynamic interventricular septum with a small hypoplastic right ventricle. The pulmonary valve was not visualized. The tricuspid valve appeared normal. There was no evidence of Ebstein's anomaly. Gases on room air demonstrated oxygen pressure to be 27mm Hg with a saturation of 54%.

Cardiac catheterization demonstrated a hypoplastic right ventricle with an atretic right ventricular outflow tract and intact ventricular septum, patent ductus arteriosus, and an atrial septal defect (*Fig. 4*). On the day of admission after the cardiac catheterization, the surgical findings were severe pulmonary stenosis with an intact ventricular septum, atrial septal defect, patent ductus arteriosus, and a hypoplastic right ventricle. The infant underwent closure of the patent ductus arteriosus, pulmonary valvotomy, and placement of an aortopulmonary shunt with the use of a 4mm polytetrafluoroethylene (PTFE) graft. Tubes were removed from the patient on the day after surgery. The patient was returned to the regular nursing floor seven days after surgery and

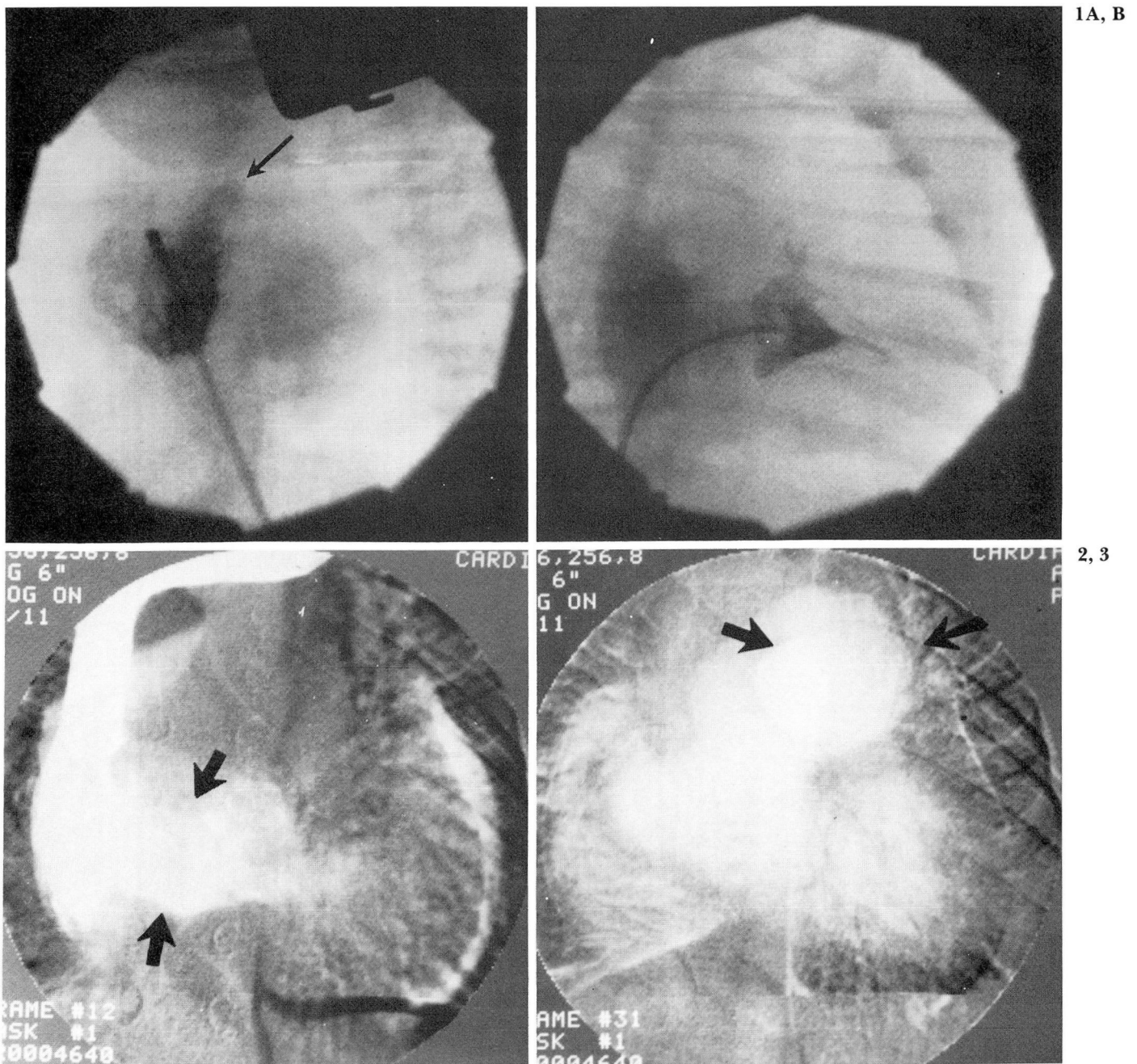


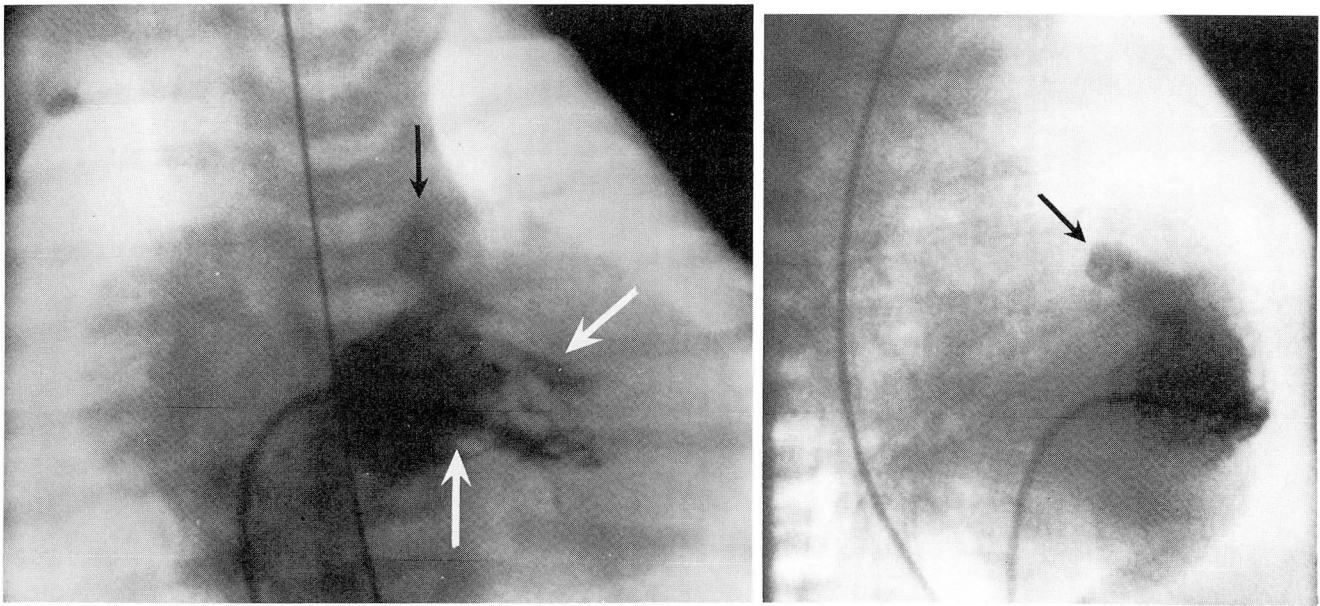
Fig. 1. Case 1. **A.** Preoperative right ventricular angiogram, AP view, demonstrating a severely hypoplastic right ventricle with pulmonary valve atresia (*arrow*) and intact ventricular septum

B. Preoperative right ventricular angiogram, lateral view, demonstrating a severely hypoplastic right ventricle with tricuspid regurgitation into a dilated right atrium. Note the difference in size between the right atrium and the right ventricle. There is no egress of blood from the right ventricle into the pulmonary artery, indicating pulmonary valve atresia.

Fig. 2. Case 1. Postoperative (19 months) intravenous DSA, AP view, demonstrates significant right ventricular growth compared to the preoperative study. Arrows point to the right ventricle which is still somewhat hypoplastic, but clearly larger than it was on the preoperative angiogram.

Fig. 3. Case 1. Peripheral intravenous DSA 19 months after surgery, demonstrating a large pericardial outflow track patch aneurysm (*arrow*).

4A, B



5A, B

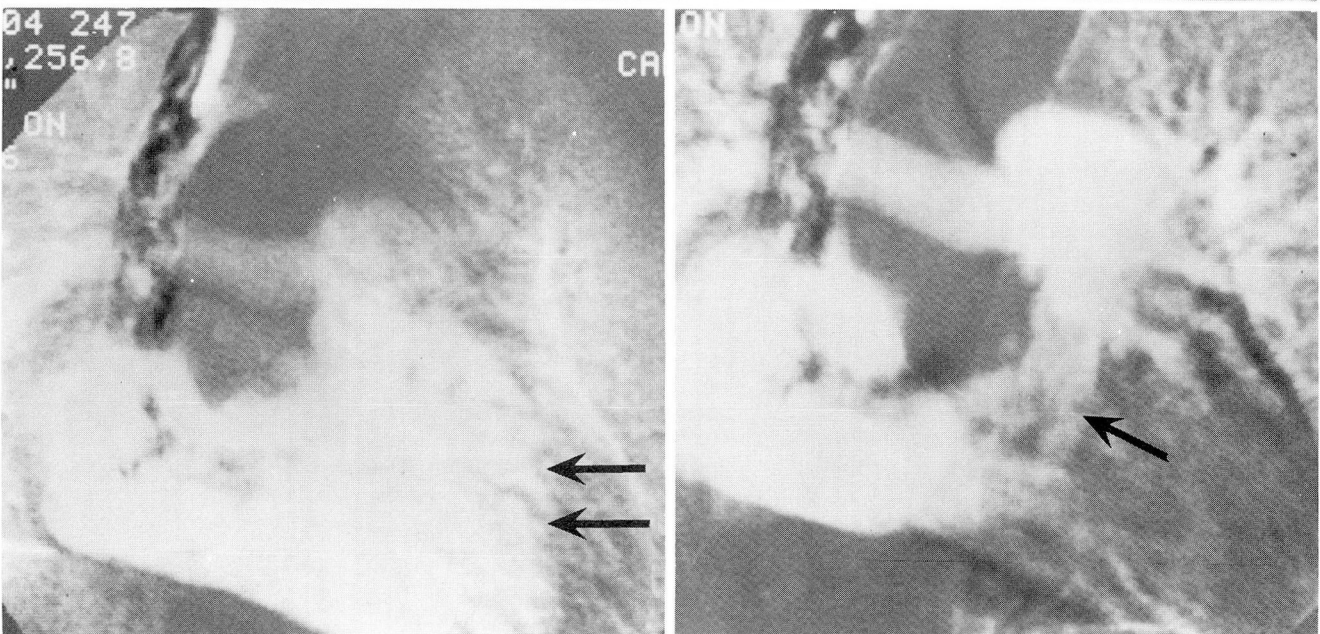


Fig. 4. Case 2. **A.** Preoperative right ventricular angiogram, demonstrating a hypoplastic right ventricle (*white arrows*) and what appears to be atresia of the right ventricular outflow track (*black arrow*), with no egress of blood to the pulmonary artery.

B. Preoperative right ventricular angiogram, lateral view, demonstrating the hypoplastic right ventricle with no egress of blood from the right ventricular outflow track (*arrow*), suggesting pulmonary valve atresia.

Fig. 5. Case 2. **A.** Eighteen-month postoperative intravenous DSA, diastolic frame, demonstrating significant growth in the size of the right ventricle in comparison with the preoperative study. The right ventricle (*arrows*) now appears normal in size with normal restoration of flow from the right ventricle to the pulmonary artery.

B. Eighteen-month postoperative intravenous DSA, AP view systolic frame, demonstrating normal systolic contraction of the right ventricle (*arrow*). The right atrium remains slightly dilated. The pulmonary valve can be visualized with a slightly dilated main pulmonary artery and normal-appearing distal vessels.

discharged ten days after surgery. Eighteen months after surgery, the infant underwent an intravenous DSA study as an outpatient with an injection from a small line placed in the inferior vena cava. The DSA study showed that the right ventricle was now relatively normal-sized, as was the right atrium (*Fig. 5*). The pulmonary arteries appeared

somewhat small. The systemic pulmonary artery shunt was not well visualized (*Fig. 5*). The right ventricular chamber was now larger than on the preoperative angiogram.

Case 3. A white girl was born after normal labor and vaginal delivery. Her birth weight was 2.9 kg. The child was

breast-fed until 48 hours of age when she became cyanotic and required 50% oxygen. Chest radiographs at that time showed an enlarged heart, and a physical examination demonstrated absent peripheral pulses. The infant was transferred to The Cleveland Clinic Foundation at five days of age.

During the physical examination here, the infant appeared jaundiced and in no distress. All peripheral pulses were normal. The heart rate was 140 beat/min, and the respiratory rate was 40/min. The first heart sound was normal; the second heart sound was single. There was a 2/6 systolic murmur at the upper left sternal border. The femoral pulses were palpable bilaterally and synchronous with the brachial pulses.

Chest radiographs demonstrated cardiomegaly with prominent pulmonary vascularity. An electrocardiogram (EKG) showed sinus rhythm with right axis deviation, right ventricular hypertrophy, and absence of left ventricular forces. M-mode and two-dimensional echocardiography demonstrated a large atrial septal defect with a hypoplastic left ventricle (Fig. 6). No mitral or aortic valve could be identified. The ascending aorta measured 6–7mm. Cardiac catheterization demonstrated hypoplastic left heart syndrome with aortic and mitral atresia and a persistent left superior vena cava. No other congenital anomalies were found.

The infant underwent surgical palliation at five days of age with ligation of the patent ductus arteriosus, elimination of an endothelial ridge of coarctation in the aorta, and placement of a 10mm polytetrafluoroethylene (Gortex) prosthesis from the aorta to the pulmonary artery. The confluence of the right and left pulmonary artery was isolated with a pulmonary artery flap, and a 4mm communication was created between the Gortex graft and the pulmonary artery. The infant's postoperative course was complicated by mild congestive heart failure, which was man-

aged with dobutamine, digoxin, and diuretics. Tubes were removed from the patient on the third postoperative day. She was discharged from the hospital 32 days after surgery. Twenty days after surgery, a DSA study was done via an indwelling subclavian line using 3 ml of Renografin-76. This demonstrated the pulmonary artery-aortic conduit (Fig. 7) with adequate flow to the pulmonary arteries as well as to the aorta. The hypoplastic ascending aorta, and the persistent left superior vena cava, were visualized on the postoperative DSA study (Fig. 7).

Nine months after surgery, the patient is growing and developing normally. The chest radiograph shows cardiomegaly. The infant is currently taking digoxin.

Case 4. A white boy was born to a 27 year old (gravid 1, para 0) who had had no problems during pregnancy, labor, and delivery. The baby did well until four hours after birth when he became cyanotic with feeding, with an arterial pH of 7.01. He was given bicarbonate. Catheterization demonstrated hypoplastic left heart syndrome with an atretic ascending aorta and a large patent ductus arteriosus (Fig. 8). The patient was started on a course of prostaglandin and transferred to The Cleveland Clinic Foundation at two days of age.

During the physical examination, the infant was acyanotic on 50% oxygen and a ventilator. The heart rate was 160 beat/min. The blood pressure was 60-66mm Hg systolic. The first heart sound was normal; the second heart sound was split, with an increased pulmonary component. A right ventricular lift and a soft, grade I/VI systolic murmur at the left mid-sternal border were noted. The peripheral pulses were 3+/4+ and bounding.

The EKG showed a sinus rhythm with right ventricular hypertrophy, right axis deviation, and lack of left ventricular forces. A chest radiograph demonstrated some cardiome-

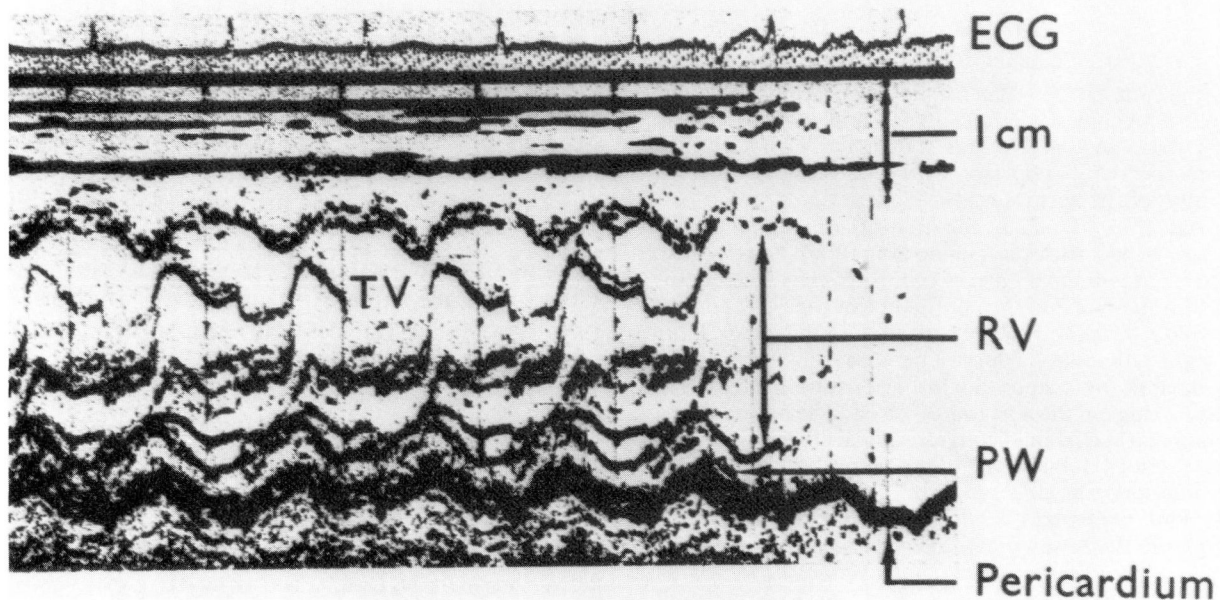


Fig. 6. Case 3. M-mode echocardiogram, demonstrating a severely hypoplastic left ventricle. Only a tiny left ventricle is noted when one compares the space between the posterior left ventricular wall (PW) and the body of the right ventricle (RV). (ECG = electrocardiogram, RV = right ventricle.)

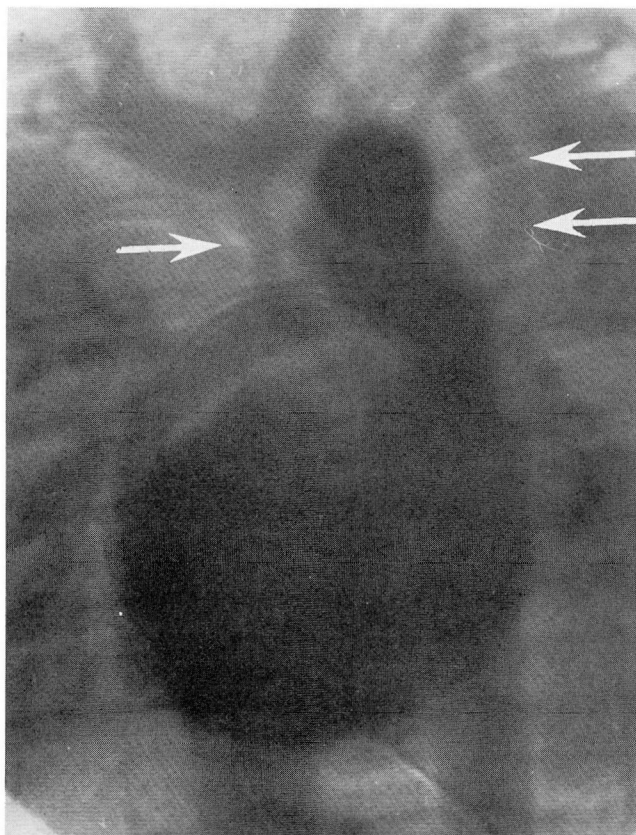


Fig. 7. Case 3. Twenty-day postoperative intravenous DSA demonstrates adequacy of palliative repair, with the conduit placed from the proximal pulmonary artery to the upper descending aorta, with adequate pulmonary and aortic blood flow. The right ventricle is enlarged. The single arrow points to the atretic ascending aorta. The double arrows indicate persistent left superior vena cava.

galy with right ventricular hypertrophy and pulmonary venous congestion. A two-dimensional echocardiogram demonstrated a hypoplastic left ventricle and no mitral valve tissue. There was a slit-like left ventricular cavity, and the aorta was severely hypoplastic with an atretic aortic valve. Coarctation of the aorta was also suggested.

One day after admission, the infant underwent a cardiopulmonary bypass with placement of a 10mm Gortex graft from the main pulmonary artery to the proximal descending aorta and isolation from the confluence of the right and left pulmonary arteries with placement of a 5mm Gortex shunt to the right pulmonary artery. The atrial septal defect was enlarged, and the patent ductus arteriosus ligated. The coarctation ridge in the aorta was excised. The perioperative course was marked by mild congestive heart failure managed with intravenous dobutamine, digoxin, and diuretics. Ventilatory support was necessary for eight days. He subsequently had prolonged feeding problems and was discharged from the hospital 40 days after surgery.

Fifteen days postoperatively, intravenous DSA via an indwelling subclavian line using 3 ml of Renografin-76 demonstrated adequate intracardiac palliation (*Fig. 9*).

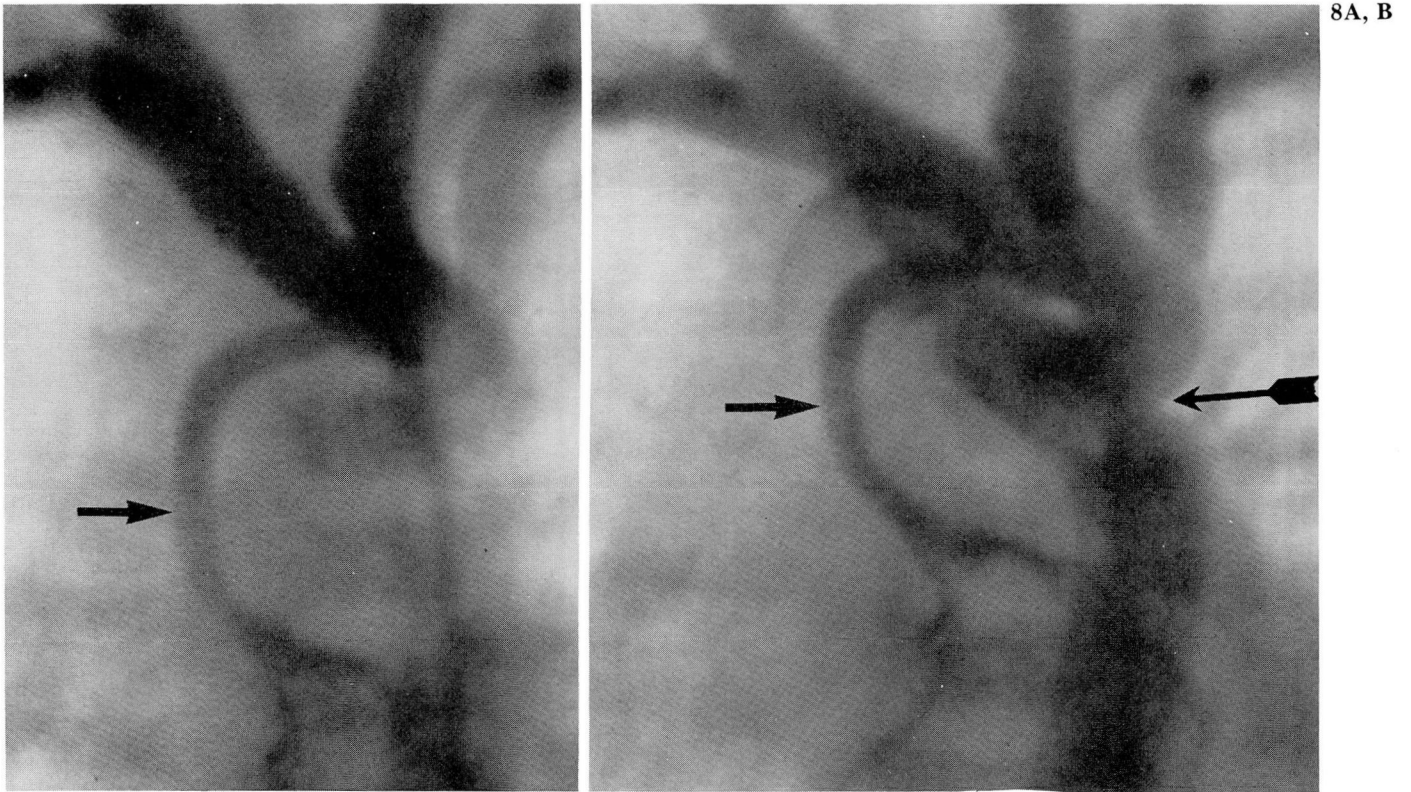
Seven months after surgery, the patient is growing and

developing normally. The chest radiograph shows cardiomegaly, and the patient is currently on a course of digitalis.

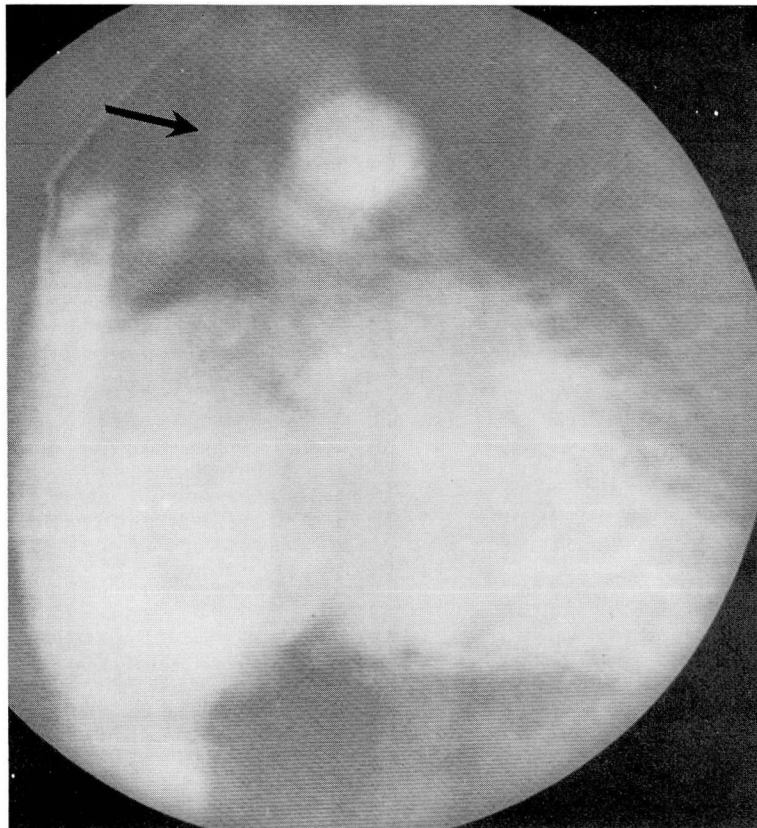
Discussion

We have previously described the use of intravenous DSA in the evaluation of congenital heart disease,^{18,19} as well as congenital abnormalities of the aorta and aortic arch,²⁰ intracardiac masses,²¹ anomalies associated with intracardiac left-to-right shunts,²² and aneurysms of the atrial and ventricular septum.²³ We believe this to be the first report detailing the use of intravenous DSA in infants following surgical palliation of hypoplastic right and left heart syndromes. The techniques for intravenous administration of contrast material have been previously described.¹⁸⁻²³ Digital and analogue systems with single and average multiple masks were used with two commercially available systems with radiographic or continuous modes. In all infants, 3 ml or less of Renografin-76 was injected intravenously for the study. The 2 patients with hypoplastic right heart syndrome were studied via peripheral intravenous injections 18 and 19 months after surgery, respectively, in an outpatient setting in a pediatric cardiology clinic. The 2 patients with hypoplastic left heart syndrome were studied via an indwelling intravenous line 15 and 20 days, respectively, after surgery.

Our approach to the infants with hypoplastic right heart syndrome (pulmonary valve atresia and an intact ventricular septum with a hypoplastic right ventricle) has been to establish an aortopulmonary shunt and provide right ventricular pulmonary artery continuity. DSA techniques provide the best method to adequately assess the growth of the right ventricle, as well as pulmonary flow, following right ventricular outflow tract reconstruction. In addition, they can detect early abnormalities as in case 1 in whom a pericardial outflow patch aneurysm had developed, which we are following clinically. In both the patients described, one can see significant right ventricular growth, as well as adequacy of pulmonary blood flow, on the follow-up intravenous DSA. Few studies document the growth of the right ventricle following intracardiac repair,⁸⁻¹⁰ yet this kind of information is critical when one is contemplating a further, more definitive procedure, such as the Fontan operation, in infants who continue to have a hypoplastic right ventricle despite that chamber's growth (our case 1). Our case 2 demonstrates that some infants with criti-



8A, B



9

Fig. 8. Case 4. **A.** Preoperative upper descending aortogram, demonstrating severe hypoplasia of the ascending aorta (*arrow*) with atresia of the aortic valve.

B. Preoperative upper descending aortogram, AP view, demonstrating aortic valve atresia with severe hypoplasia of the ascending aorta with filling of the descending aorta via a large patent ductus arteriosus. The large arrow points to an aortic coarctation.

Fig. 9. Fifteen-day postoperative intravenous DSA demonstrates a dilated right atrium and right ventricle, and adequate flow into the pulmonary artery and descending aorta via the proximal pulmonary artery-upper descending aorta conduit. The arrow points to the atretic ascending aorta. The aortopulmonary artery shunt is not well visualized.

cal pulmonary stenosis do indeed have a rudimentary valve, and thus all that will be required for successful growth of the right ventricle is opening of that valve and re-establishment of right ventricular pulmonary artery continuity. Intravenous DSA techniques, which can be performed safely with small amounts of contrast agent on an outpatient basis, are clearly helpful for following the results of this kind of repair without the necessity for numerous follow-up cardiac catheterizations.

We have previously described our approach to infants with the hypoplastic left heart syndrome.¹⁷ With any new operation, it is critical to have sequential angiographic and hemodynamic evaluation of the results of repair. DSA provided an ideal method for the study of both patients in the immediate postoperative period. In both patients, 3 ml or less of contrast material was injected through an indwelling subclavian catheter to demonstrate the adequacy of intracardiac repair and associated anomalies, such as the persistent left superior vena cava seen in the first patient. DSA techniques allowed us to assess sequentially the progression in size and function of the right ventricle, as well as the adequacy of pulmonary blood flow.

Sequential angiographic follow-up in patients with hypoplastic left heart syndrome is vital before definitive repairs are initiated.¹⁶ DSA is an ideal method to accomplish this.

DSA provides a safe, easy method for studying the results of intracardiac repair after surgical palliation in patients with hypoplastic right and left heart syndromes. DSA studies can be performed easily in the immediate postoperative period in an outpatient setting to assess long-term results of surgery, as well as growth and function of the right ventricle in the hypoplastic right heart syndrome and the adequacy of aortic and pulmonary flow in the hypoplastic left heart syndrome. Associated anomalies can also be readily identified. This may be the safest angiographic method for following the results of surgery in all newborn infants with complex congenital cardiac disease.

References

- Shams A, Fowler RS, Trusler GA, Keith JD, Mustard WT. Pulmonary atresia with an intact ventricular septum: report of 50 cases. *Pediatrics* 1971; **47**:370-377.
- Gersony WM, Bernhard WF, Nadas AS, Gross RE. Diagnosis and surgical treatment of infants with critical pulmonary outflow obstruction. Study of 34 infants with pulmonary stenosis or atresia, and intact ventricular septum. *Circulation* 1967; **35**:765-776.
- Subramanian S. Surgical treatment of complex cyanotic anomalies in infants: pulmonary atresia with an intact ventricular septum. [In] David JC, ed. *Second Henry Ford Hospital International Symposium on Cardiac Surgery*. New York, Appleton Century Crofts, 1977, p 316.
- Bull C, de Leval MR, Mercanti C, Macartney FJ, Anderson RH. Pulmonary atresia and intact ventricular septum: a revised classification. *Circulation* 1982; **66**:266-272.
- de Leval MR, Bull C, Stark J, Anderson RH, Taylor JF, Macartney FJ. Pulmonary atresia and intact ventricular septum: surgical management based on a revised classification. *Circulation* 1982; **66**:272-280.
- Moulton AL, Bowman FO Jr, Edie RN, et al. Pulmonary atresia with intact ventricular septum. 16-year experience. *J Thorac Cardiovasc Surg* 1979; **78**:527-536.
- Lewis AB, Wells W, Lindesmith GG. Evaluation and surgical treatment of pulmonary atresia and an intact ventricular septum in infancy. *Circulation* 1983; **67**:1318-1323.
- Patel RG, Freedom RM, Moes CAF, et al. Right ventricular volume determinations in 18 patients with pulmonary atresia and intact ventricular septum. Analysis of factors influencing right ventricular growth. *Circulation* 1980; **61**:428-440.
- Fricker FJ, Zuberbuhler JR, Neches WH, et al. Right ventricular growth in pulmonary atresia with intact ventricular septum (abst). *Am J Cardiol* 1980; **45**:448.
- Rao PS, Liebman J, Borkat G. Right ventricular growth in a case of pulmonic stenosis with intact ventricular septum and hypoplastic right ventricle. *Circulation* 1976; **53**:389-394.
- Fyler DC. Report of the New England Regional Infants Cardiac Program. *Pediatrics* 1980; **65**:376-471.
- Norwood WI, Lang P, Hansen DD. Physiologic repair of aortic atresia—hypoplastic left heart syndrome. *N Engl J Med* 1983; **308**:23-26.
- Norwood WI, Kirklin JK, Sanders SP. Hypoplastic left heart syndrome: experience with palliative surgery. *Am J Cardiol* 1980; **45**:87-91.
- Norwood WI, Lang P, Castaneda AR, Campbell DN. Experience with operations for hypoplastic left heart syndrome. *J Thorac Cardiovasc Surg* 1981; **82**:511-519.
- Doty DB, Marvin WJ, Schieken RM, Lauer RM. Hypoplastic left heart syndrome: successful palliation with a new operation. *J Thorac Cardiovasc Surg* 1980; **80**:148-152.
- Lang P, Norwood WI. Hemodynamic assessment after palliative surgery for hypoplastic left heart syndrome. *Circulation* 1983; **68**:104-108.
- Gill CC, Moodie DS, Sterba R. Hypoplastic left heart syndrome: medical management and practical surgical palliation. *Clev Clin Q* 1983; **50**:269-274.
- Moodie DS, Buonocore E, Yiannikas J, Gill CC, Pavlicek WA. Digital subtraction angiography in congenital heart disease in pediatric patients. *Cleve Clin Q* 1982; **49**:159-171.
- Buonocore E, Pavlicek WA, Modic MT, et al. Anatomic and functional imaging of congenital heart disease with digital subtraction angiography. *Radiology* 1983; **147**:647-654.
- Moodie DS, Yiannikas J, Gill CC, Buonocore E, Pavlicek W. Intravenous digital subtraction angiography in the evaluation of congenital abnormalities of the aorta and aortic arch. *Am Heart J* 1982; **104**:628-634.
- Yiannikas J, Zaidi AR, Moodie DS. Digital subtraction angiography: evaluation of intracardiac masses—case reports. *Am Heart J* (in press).
- Yiannikas J, Moodie DS, Gill CC, Buonocore E. Intravenous digital subtraction angiography in the assessment of patients with left-to-right shunts before and after surgical correction. *J Am Coll Cardiol* (in press).
- Yiannikas J, Moodie DS, Sterba R, Gill CC. Intravenous digital subtraction angiography to assess pre and postoperatively aneurysms of the ventricular and atrial septum. *Am J Cardiol* (in press).